

# JOURNAL OF BIOLOGICAL REGULATORS & HOMEOSTATIC AGENTS

Volume 30, No. 2 (Supplement 3), April - June, 2016

## CONTENTS

U. Wollina, J. Hercogová, M. Fioranelli, S. Gianfaldoni, A.A. Chokoeva, G. Tchernev, M. Tirant, F. Novotny, M.G. Roccia, G.K. Maximov, K. França and T. Lotti. A multi-centred open trial of “Dr Michaels®” (also branded as Soratinex®) topical product family in psoriasis .....	1
K. França, J. Hercogová, M. Fioranelli, S. Gianfaldoni, A.A. Chokoeva, G. Tchernev, U. Wollina, M. Tirant, F. Novotny, M.G. Roccia, G.K. Maximov and T. Lotti. A European prospective, randomized placebo-controlled double-blind study on the efficacy and safety of Dr Michaels® (also branded as Soratinex®) product family for stable chronic plaque psoriasis .....	9
J. Hercogová, M. Fioranelli, S. Gianfaldoni, A.A. Chokoeva, G. Tchernev, U. Wollina, M. Tirant, F. Novotny, M.G. Roccia, G.K. Maximov, K. França and T. Lotti. A clinical examination of the efficacy of preparation of Dr Michaels® (also branded as Soratinex®) products in the treatment of asis .....	15
M. Tirant, J. Hercogová, M. Fioranelli, S. Gianfaldoni, A.A. Chokoeva, G. Tchernev, U. Wollina, F. Novotny, M.G. Roccia, G.K. Maximov, K. França and T. Lotti. Nail psoriasis in an adult successfully treated with a series of herbal skin care products family – a case report .....	21
M. Fioranelli, J. Hercogová, S. Gianfaldoni, A.A.Chokoeva, G. Tchernev, U. Wollina, M Tirant, F. Novotny, M.G. Roccia, G.K. Maximov, K. França and T. Lotti. Clinical evaluation of the effectiveness of “Dr Michaels®” (also branded as Soratinex®) products in the topical treatment of patients with plaque psoriasis .....	29
M. Tirant, P. Anderson, P. Bayer, J. Hercogová, M. Fioranelli, S. Gianfaldoni, A.A. Chokoeva, G. Tchernev, U. Wollina, F. Novotny, M.G. Roccia, G.K. Maximov, K. França and T. Lotti. Successful treatment of a chronic eczema in a 48-year-old female with Dr Michaels® (Eczitinex® and Itchinex®) product family. a case report .....	35
J. Hercogová, M. Fioranelli, S.Gianfaldoni, A.A. Chokoeva, G. Tchernev, U. Wollina, M Tirant, F.Novotny, M.G.Roccia, G.K. Maximov, K. França and T. Lotti. Dr Michaels® (Soratinex®) product for the topical treatment of psoriasis: a Hungarian/Czech and Slovak study .....	43
U. Wollina, M. Tirant, P. Bayer, M. Coburn, M. Smith, B. Donnelly, T. Kennedy, J. Gaibor, M. Arora, L. Clews, S. Walsley, J. Hercogová, M. Fioranelli, S. Gianfaldoni, A.A. Chokoeva, G. Tchernev, F.Novotny, M.G. Roccia, G.K. Maximov, K. França and T. Lotti. Successful treatment of mild to moderate acne vulgaris with Dr Michaels® (also branded as Zitinex®) topical products family: a clinical trial .....	49
K. França, J. Hercogová, M. Fioranelli, S. Gianfaldoni, A.A. Chokoeva, G. Tchernev, U. Wollina, M. Tirant, P. Bayer, M. Coburn, M. Smith, B. Donnelly, T. Kennedy, J. Gaibor, M. Arora, L. Clews, F. Novotny, M.G. Roccia, G.K. Maximov and T. Lotti. Investigation of the efficacy and tolerability of Dr Michaels® (also branded as Eczitinex® and Itchinex) topical products in the treatment of atopic dermatitis in children .....	55
M. Tirant, P. Bayer, J. Hercogová, M. Fioranelli, S.Gianfaldoni, A.A.Chokoeva, G. Tchernev, U. Wollina, F. Novotny, M.G. Roccia, G.K. Maximov, K. França and T. Lotti. Treatment of ichthyosis lamellaris using a series of herbal skin care products family .....	65
J. Hercogová, M. Fioranelli, S. Gianfaldoni, A.A. Chokoeva, G. Tchernev, U. Wollina, M. Tirant, F. Novotny, M.G. Roccia, G.K. Maximov, K. França and T. Lotti. Investigation of the efficacy of Dr Michaels® (Soratinex®) family in maintaining a symptom-free state for patients with psoriasis in remission. A retrospective, comparative study .....	73
J. Hercogová, M. Fioranelli, S. Gianfaldoni, A.A. Chokoeva, G. Tchernev, U. Wollina, M Tirant, F.Novotny, M.G.Roccia, G.K. Maximov, K. França, and T. Lotti. Dr Michaels® product family (also branded as Soratinex®) versus methylprednisolone aceponate - a comparative study of the effectiveness for the treatment of plaque psoriasis .....	77
U. Wollina, J. Hercogová, M. Fioranelli, S.Gianfaldoni, A.A. Chokoeva, G. Tchernev, M. Tirant, F.Novotny, M.G. Roccia, G.K. Maximov, K. França and T. Lotti. Successful treatment of alopecia areata with Dr. Michaels® product family .....	83
J. Hercogova, M. Tirant, P. Bayer, M. Coburn, B. Donnelly, T. Kennedy, J. Gaibor, M. Arora, L. Clews, M. Fioranelli, S. Gianfaldoni, A.A. Chokoeva, G. Tchernev, U.Wollina, F. Novotny, M.G. Roccia, G.K. Maximov, K. França and T. Lotti. Successful treatment of recalcitrant <i>candidal intertrigo</i> with Dr Michaels® (Fungatinex®) product family .....	89
M. Tirant, P. Bayer, J. Hercogová, M. Fioranelli, S. Gianfaldoni, A.A. Chokoeva, G. Tchernev, U. Wollina, F. Novotny, M.G.Roccia, G.K. Maximov, K. França and T. Lotti. Successful treatment of facial systemic lupus erythematosus lesions with Dr Michaels® (Soratinex®) product family. A case report .....	95
U. Wollina, J. Hercogová, M. Fioranelli, S. Gianfaldoni, A.A. Chokoeva, G. Tchernev, M. Tirant, F. Novotny, M.G. Roccia, G.K. Maximov, K. França and T. Lotti. Scalp psoriasis: a promising natural treatment .....	103
S. Gianfaldoni, J. Hercogová, M. Fioranelli, A.A. Chokoeva, G. Tchernev, U.Wollina, M. Tirant, F. Novotny, M.G. Roccia, G.K. Maximov, K. França and T. Lotti. An innovative, promising topical treatment for psoriasis: a Romanian clinical study .....	109
K. França, F. Novotny, J. Hercogová, M. Fioranelli, S.Gianfaldoni, A.A. Chokoeva, G. Tchernev, U. Wollina, M. Tirant, M.G. Roccia and T. Lotti. Efficacy and safety of Dr Michaels® (Soratinex®) product family for the topical treatment of psoriasis: a monitored status study .....	115
K. França, M. Tirant, J. Hercogová, F. Novotny, M. Fioranelli, S. Gianfaldoni, A.A.Chokoeva, G. Tchernev, U.Wollina, M.G. Roccia and T. Lotti. Quality of life aspects of patients with psoriasis using a series of herbal products .....	121
V. Barygina, M. Becatti, A. Mannucci, N. Taddei, M. Tirant, J. Hercogova, K. França, M. Fioranelli, M.G. Roccia, G. Tchernev, U. Wollina, T. Lotti and C. Fiorillo. Short Communication: a vegetable oil extract restores redox status in fibroblasts from psoriatic patients .....	129



## A MULTI-CENTRED OPEN TRIAL OF “DR MICHAELS®” (ALSO BRANDED AS SORATINEX®) TOPICAL PRODUCT FAMILY IN PSORIASIS

U. WOLLINA<sup>1</sup>, J. HERCOGOVÁ<sup>2,3</sup>, M. FIORANELLI<sup>4</sup>, S. GIANFALDONI<sup>5</sup>,  
A.A.CHOKOEVA<sup>6,7</sup>, G.TCHERNEV<sup>8</sup>, M. TIRANT<sup>9</sup>, F. NOVOTNY<sup>10</sup>, M.G. ROCCIA<sup>11</sup>,  
G.K. MAXIMOV<sup>12</sup>, K. FRANÇA<sup>13,14</sup> and T. LOTTI<sup>15</sup>

<sup>1</sup>Department of Dermatology and Allergology, Academic Teaching Hospital Dresden-Friedrichstadt, Dresden, Germany; <sup>2</sup>2nd Medical Faculty, Charles University, Bulovka Hospital, <sup>3</sup>Institute of Clinical and Experimental Medicine, Prague, Czech Republic; <sup>4</sup>Department of Nuclear Physics, Sub-nuclear and Radiation, G. Marconi University, Rome, Italy; <sup>5</sup>Dermatological Department University of Pisa, Pisa, Italy; <sup>6</sup>“Onkodermat”- Policlinic for dermatology and dermatologic surgery, Sofia, Bulgaria; <sup>7</sup>Department of Dermatology and Venereology, Medical University of Plovdiv, Medical faculty, Plovdiv, Bulgaria; <sup>8</sup>Medical Institute of Ministry of Interior (MVR), Department of Dermatology, Venereology and Dermatologic Surgery, Sofia, Bulgaria; <sup>9</sup>Psoriasis & Skin Clinic, Melbourne, Australia; <sup>10</sup>PRO SANUM Ltd., Sanatorium of Prof. Novotný, Štěpánská Prague 1, Czech Republic; <sup>11</sup>University B.I.S. Group of Institutions, Punjab Technical University, Punjab, India, <sup>12</sup>Department “Medicinal Information and Non-interventional studies”, Bulgarian Drug Agency, Sofia, Bulgaria; <sup>13</sup>Department of Dermatology & Cutaneous Surgery, Department of Psychiatry & Behavioral Sciences, Institute for Bioethics & Health Policy, University of Miami, Miller School of Medicine - Miami, FL, USA; <sup>14</sup>Centro Studi per la Ricerca Multidisciplinare e Rigenerativa. Università Degli Studi “G. Marconi”, Rome, Italy; <sup>15</sup>Chair of Dermatology, University of Rome “G. Marconi” Rome, Italy

Psoriasis is a chronic, recurring skin disease affecting 2-4% of the population. Genetic predisposition and precipitating factors play a role in its etiology. The disease can occur in any age or gender group. The most frequently affected areas of the body include scalp, extensor surfaces of the extremities, skin folds and nails. While a number of therapies exist for the treatment of psoriasis with a total resolution of the skin, achieving remission in a high percentage of sufferers, a treatment that results in the maintenance of remission and is free of side effects is still a desirable goal. The aim of the study was to investigate the efficacy and tolerability of Dr Michaels® (Soratinex®) topical product family in psoriasis, in terms of decreasing parakeratosis, inflammation, infiltration and involved area. Seven-hundred-and-twenty-two subjects, mean age 42.3 years (range: 18-68 years) with mild to moderately severe psoriasis, with no other current anti-psoriatic therapy, consisting of 382 males and 340 females, above 18 years of age were included and the observations were subjected to statistical analysis. Triphasic application of Dr Michaels® (Soratinex®) products was employed for 8 weeks, using Cleansing Gel, Scalp & Body Ointment and Skin Conditioner. The treatment proved to be ineffective for 22 patients (3.1%) out of 722. 84 patients (11.6%) had moderate improvement with 26-50% of cleared skin lesions; 102 patients (14.1%) had good improvement with 51-75% of cleared skin lesions; 484 patients (67.0%) experienced outstanding improvement with 76-100% of the cleared skin lesions with 52% of them achieving total resolution. Twelve patients worsened and discontinued treatment; 18 patients discontinued because of non-compliance; 33 patients developed folliculitis as a side effect. Based on the results of this study, the Dr Michaels® (Soratinex®) product family can be successfully applied in mild to moderately severe psoriasis when considering the exclusion criteria.

*Key word: Psoriasis, topical products, self treatment, Psoriasis Area and Severity Index, plaque psoriasis, patient satisfaction*

Mailing address:

Professor Torello Lotti,  
Department of Dermatology,  
University of Rome “G. Marconi”,  
Rome, Italy  
e-mail: professor@torelloLotti.it

0393-974X (2016)

Copyright © by BIOLIFE, s.a.s.

This publication and/or article is for individual use only and may not be further reproduced without written permission from the copyright holder.

Unauthorized reproduction may result in financial and other penalties  
DISCLOSURE: ALL AUTHORS REPORT NO CONFLICTS OF  
INTEREST RELEVANT TO THIS ARTICLE.

Psoriasis is a chronic inflammatory disorder with a non-uniform genetic background (1, 2). The prevalence of psoriasis in many western countries is 2% to 4%. In about 20% of cases, psoriatic arthritis (PsA) develops (3). Emotional stress plays an important role as a trigger for skin and joint psoriasis (4).

A number of pro-inflammatory pathways (5) mediates the excessive and aberrant proliferation of epidermal keratinocytes. The interplay between skin cells and immune cells is crucial in the psoriatic disease process (6). Recently the Th17/Treg balance, IL-23/Th17 pathway and dendritic cells have been identified as key players in the inflammatory process (7, 8). Other important components are cytokines, antimicrobial peptides, and leukocytes (9, 10). Epigenetic factors, including histone modifications, DNA methylation, and microRNAs participate in these complex mechanisms (11). While great steps forward have been made in targeted systemic treatments for moderate to severe psoriasis (12), there is a need to further improve topical therapies for mild to moderate psoriasis, in particular for self-treatment by patients.

#### *Aim of the study*

To study the efficacy and tolerability of Dr Michaels® (Soratinex®) topical product family in psoriasis, in terms of decreasing the parakeratosis, inflammation, and infiltration in involved area.

## MATERIALS AND METHODS

The clinical records for 722 subjects consisting of 382 males and 340 females were considered for the study and observations were subjected to statistical analysis. Patient selection was based on criteria shown in Table I.

#### *Characteristics of the Tested Products*

Triphasic application: Successive use of Dr Michaels® (Soratinex®) Cleansing Gel, Scalp & Body Ointment and Skin Conditioner.

**a)** Dr Michaels® (Soratinex®) Scalp and Body Cleansing Gel.

Loose, brown-opaque, easily applicable topical preparation. Effect: Decreases parakeratosis. Application:

Applied before the use of the ointment.

- Scalp: Wet scalp and apply a small amount of cleansing gel. Massage thoroughly and leave for 2-3 min. Wash off with lukewarm water. (Can be applied to forehead but avoid cheek area).
- Body: Wet body and apply small amount of cleansing gel to the psoriatic plaques. Leave for 2-3 min then rinse off with lukewarm water.

Active ingredients: Salicylic acid, citric and glycolic acid.

**b)** Dr Michaels® (Soratinex®) Scalp and Body Ointment.

Yellowish-white ointment with characteristic scent. Effect: Decreases inflammation and infiltration. Application: Applied to the psoriatic plaques of the scalp and body after using and washing off the cleansing gel.

Ingredients: *Paraffinum liquidum*, *Paraffinum solidum*, *solanum tuberosum*, Zinc oxide, Salicylic acid, *Prunus amygdalus dulcis* oil, *Simmondsia chinensis* oil, *Persea gratissima* oil, *Daucus carota* oil, *Calendula officinalis* extract, *Citrus sinensis* oil, *Triticum vulgare* germ oil, *Prunus armeniaca* kernel oil, *Lavendula augustifolia*, *Santalum album* oil, *Pogostemon cablin* oil, *Pelargonium graveolens*, Rosemary *officinalis* extract, *Dromiceius* oil, *Citrus aurantium* SSP *bergamia* oil, *Pinus sylvestris* leaf oil, *Chamomilla recutita* oil, *Commiphora myrrha* oil, *Citrus aurantium amara* flower oil.

**c)** Dr Michaels® (Soratinex®) Skin Conditioner.

White coloured, viscous substance with characteristic scent. Effect: Improves flexibility and elasticity of the skin. Application: Applied to the psoriatic plaques two minutes after using the ointment (without washing it off).

Ingredients: Olive oil, sesame seed oil, emu oil, lavender oil, eucalyptus oil, natural vitamin E.

#### *Study protocol*

1. Time frame

Length of study: 10 weeks

Two week wash out period. Only emollients were used during this phase. Application time of Dr Michaels® (Soratinex®) products: 8 weeks. Total number of evaluations: 10. Study group: 722 patients (382 males, 340 females). Patient evaluations were carried out at -2, 0, 1, 2, 3, 4, 5, 6, 7 and 8 weeks. Evaluated features: infiltration, erythema, parakeratosis and size of affected area, measured through Psoriasis Area and Severity Index (PASI) score (13).

During treatment, each of the three-component

**Table I.** *Criteria for patient selection.*

Inclusion criteria	<ul style="list-style-type: none"> <li>▪ Mild to severe psoriasis without complications.</li> <li>▪ Both genders, age above 18.</li> <li>▪ No other current anti-psoriatic therapy.</li> <li>▪ Signed informed consent.</li> </ul>
Exclusion criteria	<ul style="list-style-type: none"> <li>▪ Pustular and erythrodermic psoriasis</li> <li>▪ Systemic, acitretin, cyclosporine, methotrexate, light therapy currently or within the past 3 months.</li> <li>▪ Topical anti-psoriatic therapy.</li> <li>▪ Pregnancy, breastfeeding.</li> <li>▪ Known hypersensitivity to any of the components of the products.</li> <li>▪ Lack of informed consent.</li> <li>▪ Low compliance.</li> </ul>

products was applied twice daily (in the morning and in the evening).

### 2. Evaluation of efficacy

The evaluation was based on the Psoriasis Area and Severity Index (PASI) scores at each interval, based on Table IIa.

### 3. Side Effects

The recording of side effects began on week 2. The side effects characteristics, their relation to the products and the additional steps taken were recorded on the datasheet. Evaluation of the side effects was carried out at the completion of the study.

## RESULTS

The study was conducted on 722 patients (382 males, 340 females), with a mean age of 42.3 (range: 18-68). These patients had a mild to moderately severe form of plaque psoriasis, with a mean duration of the disease of 22.3 years.

At the end of the study, 12 patients worsened and discontinued treatment; 18 discontinued because of non-compliance; 22 patients showed no improvement; 84 had a moderate improvement with 26-50% of skin lesions cleared; 102 had a good improvement (51-75%) and 484 showed an outstanding improvement

with 76-100% regression of the lesions.

Recorded side effects included folliculitis of lower extremities in 33 patients. The folliculitis was clearly related to the product family and noted on a few treated plaques of the lower extremities, with the surrounding area involved. The folliculitis cleared up in 28 patients after discontinuation of the application without any further treatment.

Eighteen patients developed pruritus of the scalp and 27 patients with pruritus of upper torso. The pruritus regressed without discontinuing the application, 620 patients were very satisfied by the clinical results achieved with the treatment and 643 patients wanted to continue the therapy.

## DISCUSSION

Topical self-treatment of psoriasis has been limited to moisturizers and low-potency corticosteroid ointments only. Self-treatment offers the patients more therapeutic freedom and independence.

Here we investigated a new concept of corticosteroid-free topical therapy. Patients with mild to moderately severe psoriasis were studied (n=722). Most patients (586) had more than

**Table IIa.** *PASI assessment.*

Score	0	1	2	3	4		
Erythema	0 = none	1 = mild	2 = moderate	3 = severe	4 = very severe		
Infiltration	0 = none	1 = mild	2 = moderate	3 = severe	4 = very severe		
Parakeratosis	0 = none	1 = mild	2 = moderate	3 = severe	4 = very severe		
Score	0	1	2	3	4	5	6
Area %	0	>10	10<30	30<50	50<70	70<90	90<100

**Table IIb.** *Improvement evaluation*

Worsened	PASI score higher than baseline
Not improved	PASI decrease 0-25%
Moderate improvement	PASI decrease 26-50%
Good improvement	PASI decrease 51-75%
Outstanding improvement	PASI decrease 76-100%

50% improvement whilst and 484 patients (67%) experienced outstanding improvement with 76-100% of skin lesions cleared (Fig. 1, 2, 3, 4).

Adverse effects were mild and temporary, 33 patients developed folliculitis as a side effect. The folliculitis was clearly related to the products. This was evident on the plaques located on the lower extremities. In 28 cases, the folliculitis regressed upon discontinuation of the application of the products without further treatment. The other five patients cleared up with topical therapy. Forty-five patients developed pruritus of the scalp, upper torso and lower extremities. This regressed without discontinuing the application. Twelve patients worsened and had to discontinue the application. No patient was included in the study with known hypersensitivity to any component of the product. Some components of the products may have potential photosensitizing effect, contributing to

the worsening of the lesions. In case of noticing side effects, the patient should seek medical advice.

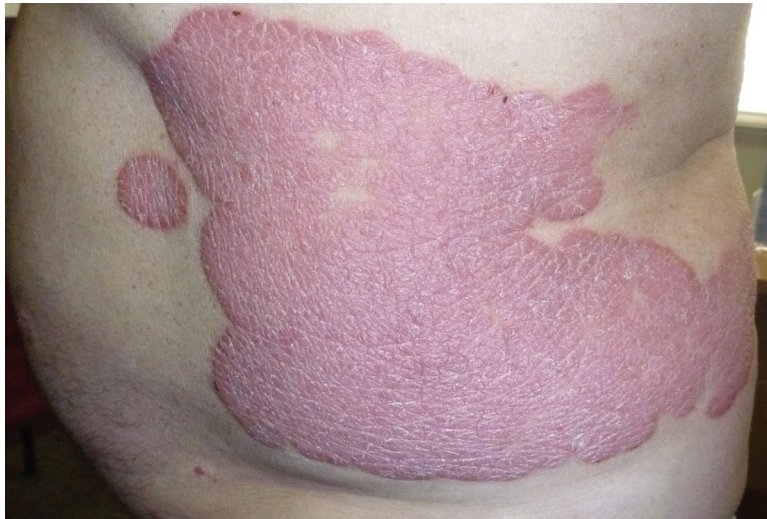As the product family consists of three differed components, it is important that the packaging insert is clear and easy to understand. The directions for application should also be easy to understand for the patient.

## CONCLUSION

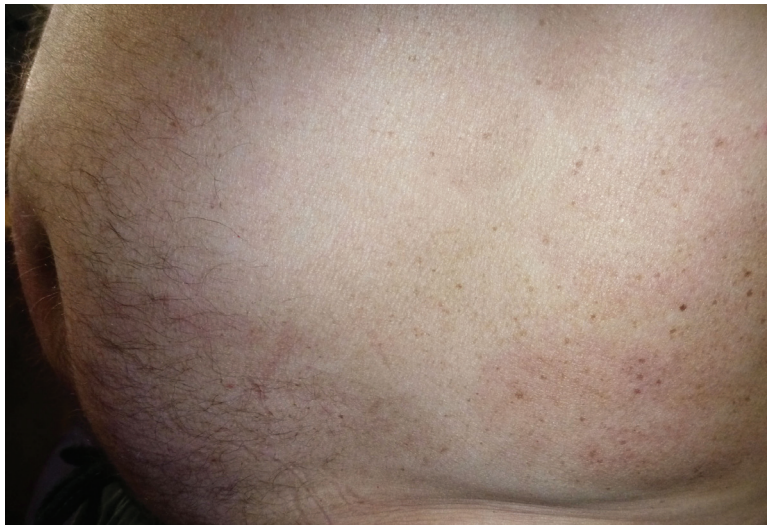Based on the results of this study, the Dr Michaels® (Soratinex®) product family can be successfully applied in mild to moderately severe psoriasis after considering the exclusion criteria.

## ACKNOWLEDGEMENTS

We gratefully acknowledge Tirsell Pty Ltd (Melbourne, Australia) and Frankl Pharma Global



**Fig. 1.** *Week 0: Before treatment with Dr Michael product family.*

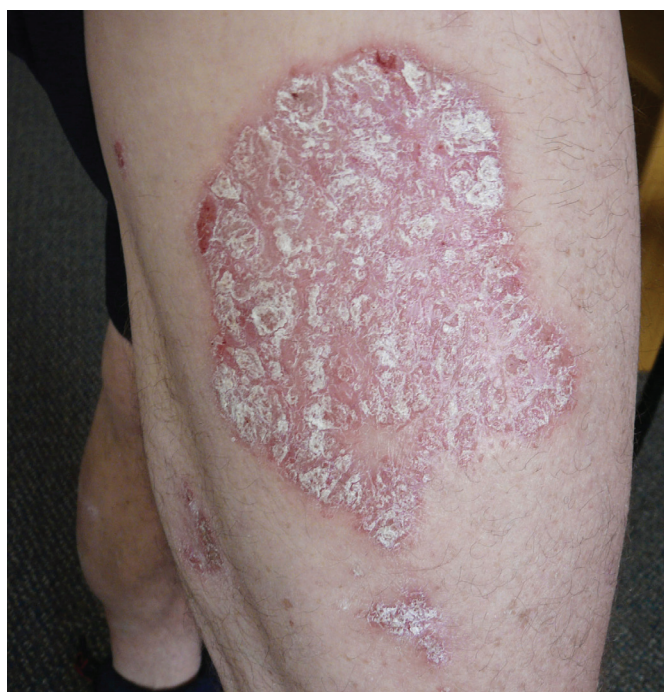

**Fig. 2.** *Week 8: After treatment with Dr Michael product family.*

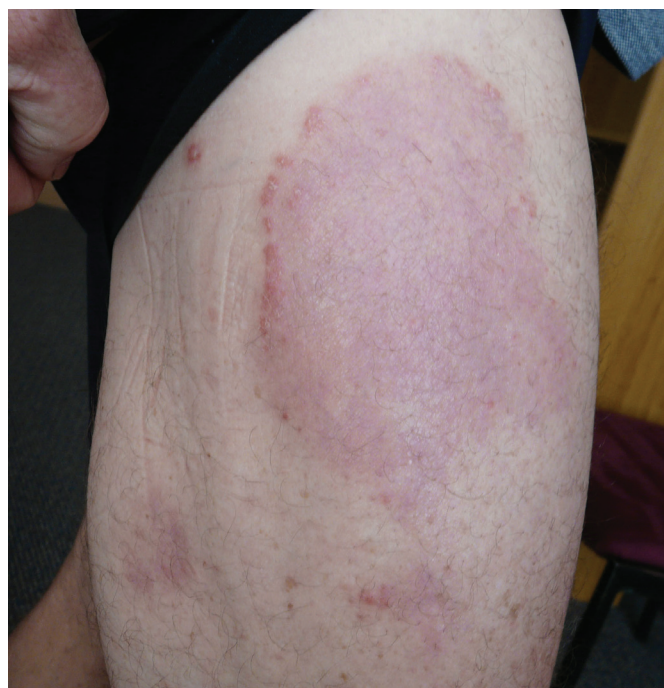Ltd. (2 Parklands Place, Guilford, Surrey, United Kingdom) for providing the products for the studies. We also acknowledge Dr T. Smith for initiating trials on the products.

#### REFERENCES:

1. Loffredo S, Ayala F, Marone G, Delfino G, Stranges S, Marone G. Immunopathogenesis of psoriasis and pharmacological perspectives. *Rheumatol Suppl* 2009; 83:9-11.
2. AlShobaili HA, Shahzad M, Al-Marshood A, Khalil A, Settin A, Barrimah I. Genetic Background of Psoriasis. *Int J Health Sci (Qassim)* 2010; 4(1):23-29.
3. Wollina U, Unger L, Heinig B, Kittner T. Psoriatic arthritis. *Dermatol Ther* 2010; 23(2):123-36.
4. Hunter HJ, Griffiths CE, Kleyn CE. Does psychosocial stress play a role in the exacerbation of psoriasis? *Br J Dermatol* 2013; 169(5):965-74.
5. Gottlieb AB, Chamian F, Masud S, et al. TNF inhibition rapidly down-regulates multiple



**Fig. 3.** *Week 0: Before treatment with Dr Michael product family.*



**Fig. 4.** *Week 8: After application of Dr Michael product family.*



- proinflammatory pathways in psoriasis plaques. *J Immunol* 2005; 175(4):2721-9.
6. Tonel G, Conrad C. Interplay between keratinocytes and immune cells - recent insights into psoriasis pathogenesis. *Int J Biochem Cell Biol* 2009; 41(5):963-8.
  7. Raychaudhuri SP. Role of IL-17 in psoriasis and psoriatic arthritis. *Clin Rev Allergy Immunol.* 2013; 44(2):183-93.
  8. Fitch E, Harper E, Skorcheva I, Kurtz SE, Blauvelt A. Pathophysiology of Psoriasis: Recent Advances on IL-23 and Th17 Cytokines. *Curr Rheumatol Rep* 2007; 9(6):461-467.
  9. Alwan W, Nestle FO. Pathogenesis and treatment of psoriasis: exploiting pathophysiological pathways for precision medicine. *Clin Exp Rheumatol* 2015; 33:(5S93)2-6.
  10. Boehncke WH. Etiology and Pathogenesis of Psoriasis. *Rheum Dis Clin North Am* 2015; 41(4):665-75.
  11. Hawkes JE, Nguyen GH, Fujita M, Florell SR, Callis Duffin K, Krueger GG, O'Connell RM. microRNAs in Psoriasis. *J Invest Dermatol* 2016; 136(2):365-71.
  12. Mahil SK, Capon F, Barker JN. Update on psoriasis immunopathogenesis and targeted immunotherapy. *Semin Immunopathol* 2016; 38(1):11-27.
  13. Fredriksson T, Pettersson U. Severe psoriasis - oral therapy with a new retinoid. *Dermatologica* 1978; 157(4):238-44.



## A EUROPEAN PROSPECTIVE, RANDOMIZED PLACEBO-CONTROLLED DOUBLE-BLIND STUDY ON THE EFFICACY AND SAFETY OF DR MICHAELS® (ALSO BRANDED AS SORATINEX®) PRODUCT FAMILY FOR STABLE CHRONIC PLAQUE PSORIASIS

K. FRANÇA<sup>1,14</sup>, J. HERCOGOVÁ<sup>2,3</sup>, M. FIORANELLI<sup>4</sup>, S. GIANFALDONI<sup>5</sup>,  
A.A. CHOKOEVA<sup>6,7</sup>, G. TCHERNEV<sup>8</sup>, U. WOLLINA<sup>9</sup>, M. TIRANT<sup>10</sup>, F. NOVOTNY<sup>11</sup>,  
M.G. ROCCIA<sup>12</sup>, G.K. MAXIMOV<sup>13</sup> and T. LOTTI<sup>15</sup>

<sup>1</sup>Department of Dermatology & Cutaneous Surgery, Department of Psychiatry & Behavioral Sciences Institute for Bioethics & Health Policy, University of Miami, Miller School of Medicine, Miami, FL, USA; <sup>2</sup>2nd Medical Faculty, Charles University, Bulovka Hospital, <sup>3</sup>Institute of Clinical and Experimental Medicine, Prague, Czech Republic; <sup>4</sup>Department of Nuclear Physics, Sub-nuclear and Radiation, G. Marconi University, Rome, Italy; <sup>5</sup>Dermatological Department, University of Pisa, Pisa, Italy; <sup>6</sup>"Onkoderma"- Polyclinic for dermatology and dermatologic surgery, Sofia, Bulgaria; <sup>7</sup>Department of Dermatology and Venereology, Medical University of Plovdiv, Medical faculty, Plovdiv, Bulgaria; <sup>8</sup>Medical Institute of Ministry of Interior (MVR), Department of Dermatology, Venereology and Dermatologic Surgery, Sofia, Bulgaria; <sup>9</sup>Department of Dermatology and Allergology, Academic Teaching Hospital Dresden-Friedrichstadt, Dresden, Germany; <sup>10</sup>Psoriasis & Skin Clinic, Melbourne, Australia, <sup>11</sup>PRO SANUM Ltd., Sanatorium of Prof. Novotný, Štěpánská Prague 1, Czech Republic; <sup>12</sup>University B.I.S. Group of Institutions, Punjab Technical University, Punjab, India; <sup>13</sup>Department "Medicinal Information and Non-interventional studies", Bulgarian Drug Agency; Sofia, Bulgaria; <sup>14</sup>Centro Studi per la Ricerca Multidisciplinare e Rigenerativa, Università Degli Studi "G. Marconi"- Rome, Italy; <sup>15</sup>Chair of Dermatology, University of Rome "G. Marconi" Rome, Italy

Psoriasis is a chronic, inflammatory, recurrent, genetically determined dermatitis that affects the skin and joints. Many patients affected by this condition seek alternatives and complementary treatment options such as herbal medicines. In order to establish the safety of these products, trials, according to medical standards should be performed to provide the highest quality of data. The aim of this study was to assess the efficacy and safety of an Australian series of herbal skin-care products [Dr. Michaels® (Soratinex®) skin-care products for psoriasis] for the management of stable chronic plaque psoriasis. We studied 142 patients (68 females and 74 males) with mild to moderate, stable, chronic plaque psoriasis and they were randomly assigned to either *verum* or control group. Exclusion criteria were: severe psoriasis, arthropathic psoriasis, intertriginous psoriasis, palmoplantar psoriasis, use of any antipsoriatic treatment and any medication which could influence or interfere with the course of the disease. Both groups consisted of a cleansing gel, an ointment and an oil blend (skin conditioner), packed in neutral bottles, used twice daily for all lesions except the scalp, for 8 weeks. As control products, we used compositions of well-known neutral ointments and medicinal bathing oil. Assessment, using the Psoriasis Activity Severity Index (PASI) scores, was done before treatment and after 2, 4, 6 and 8 weeks. Patient improvement was determined by the percentage reduction of the PASI scores. Statistical analysis was carried out using the Mann-Whitney-U Test with SPSS for Windows. Our investigation demonstrates that complementary methods can play a role in dermatologic therapy as long as they undergo standardised clinical trials and fulfil the basic requirements such as product safety and quality assurance. This study shows that Dr Michaels (Soratinex®) herbal skin-care products improve mild to moderate stable chronic plaque psoriasis significantly.

*Key words: psoriasis, topical products, plaque psoriasis, herbal medicines, Psoriasis Area and Severity Index, tolerability, efficacy, patient satisfaction*

Mailing address:  
Professor Torello Lotti,  
Department of Dermatology,  
University of Rome "G. Marconi",  
Rome, Italy  
e-mail: professor@torelloitti.it

9(S3)

0393-974X (2016)  
Copyright © by BIOLIFE, s.a.s.  
This publication and/or article is for individual use only and may not be further reproduced without written permission from the copyright holder.  
Unauthorized reproduction may result in financial and other penalties  
**DISCLOSURE: ALL AUTHORS REPORT NO CONFLICTS OF INTEREST RELEVANT TO THIS ARTICLE.**

Psoriasis is a chronic, inflammatory, recurrent, genetically determined dermatitis that affects the skin and joints (1). Topical corticosteroids have been used as the mainstay therapy for psoriasis in the past 50 years (2). Although these medications play an important role in the treatment of mild to moderate cases of psoriasis, they can have adverse effects such as telangiectasia, striae and systemic effects that prevent their long-term use (1, 2). Many patients affected by this condition seek alternatives and complementary treatment options such as herbal medicines (3, 4). Patients that are most open-minded to complementary therapeutic methods are the youngest ones, with higher income and higher levels of education, female and patients with chronic diseases (4). The market for complementary health products has emerged in the past few years, but unfortunately, many products are not currently tested according to international scientific standards (5, 6, 7). In order to establish the safety of these products, trials should be performed according to medical standards to provide the highest quality of data.

#### *Aim of the study*

The aim of the study was to investigate the efficacy and safety of an Australian series of herbal skin-care products [Dr. Michaels® (Soratinex®)] for the management of stable chronic plaque psoriasis.

## MATERIALS AND METHODS

We chose a prospective, randomized, placebo-controlled, double blind design. After obtaining written consent, 142 (68 females and 74 males) patients with mild to moderate stable chronic plaque psoriasis were randomly assigned to either *verum* or control group. Patient selection was based on the criteria in Table I.

Both *verum* and control series consisted of a cleansing gel, an ointment and a skin conditioner. The products were packed in neutral bottles. The products had to be used twice daily and in the same manner. All skin lesions were treated. The cleansing gel was applied and lathered on the lesions and washed off after three to five minutes with warm water. After drying, the lesion was covered with the ointment. After the ointment was absorbed, the plaques were then covered with a thin layer of skin conditioning oil.

#### *Product characteristics*

a. The *verum* products comprised of:

Cleansing gel containing: salicylic acid, citric acid and glycolic acid. Scalp and Body Ointment containing: *Paraffinum liquidum*, *Paraffinum solidum*, *solanum tuberosum*, Zinc oxide, Salicylic acid, *Prunus amygdalus dulcis* oil, *Simmondsia chinensis* oil, *Persea gratissima* oil, *Daucus carota* oil, *Calendula*

**Table I.** *Criteria for patient selection.*

Inclusion criteria	<ul style="list-style-type: none"> <li>▪ Mild to severe psoriasis without complications.</li> <li>▪ Both genders, age above 18.</li> <li>▪ No other current anti-psoriatic therapy.</li> <li>▪ Signed informed consent.</li> </ul>
Exclusion criteria	<ul style="list-style-type: none"> <li>▪ Pustular and erythrodermic psoriasis,</li> <li>▪ Systemic, acitretin, cyclosporine, methotrexate, light therapy currently or within the past 3 months.</li> <li>▪ Topical anti-psoriatic therapy.</li> <li>▪ Pregnancy, breast feeding.</li> <li>▪ Known hypersensitivity to any of the components of the products.</li> <li>▪ Lack of informed consent.</li> <li>▪ Low compliance.</li> </ul>

*officinalis* extract, *Citrus sinensis* oil, *Triticum vulgare* germ oil, *Prunus armeniaca* kernel oil, *Lavendula augustifolia*, *Santalum album* oil, *Pogostemon cablin* oil, *Pelargonium graveolens*, Rosemary *officinalis* extract, *Dromiceius* oil, Citrus.

Skin conditioner containing: Olive oil, sesame seed oil, emu oil, lavender oil, eucalyptus oil, natural vitamin E (8).

- b. The control products were a well-known cleanser, neutral ointments and medicinal bathing oil.

#### Time frame

The study period lasted eight weeks.

#### Evaluation

Assessment, using the Psoriasis Activity Severity Index (PASI) scores (Table II) (9), was done before treatment, after 2, 4, 6 and 8 weeks. For each patient, photographs of typical lesions were taken at the beginning, at 4 weeks and at 8 weeks follow-up. Patient improvement was determined by the percentage reduction of the PASI scores. Statistical analysis was carried out using the Mann-Whitney-U Test with SPSS for Windows (10).

Dermal toxicology and safety tests were also undertaken on 32 patients including children to evaluate any hypersensitivity that may result from the application of the product family.

## RESULTS

The study was conducted on a group of 142 patients (70 *verum* and 72 control) with a mean age of 44.6 years (range: 18-74). One-hundred-and-two patients completed the 8 weeks treatment course while 20 patients (12 *verum* and 8 control) dropped out. Twelve patients from the *verum* group were excluded because of non-compliance and 10 patients (6 *verum* and 4 control) discontinued because of side effects.

Before therapy, the mean PASI score of the *verum* group was  $7.9 \pm 2.6$  SD, and  $7.2 \pm 2.2$  SD in the *control* group, respectively.

After the 8 weeks treatment course, the mean PASI score in the *verum* group was  $1.4 \pm 1.2$  SD, which is equivalent to a PASI score reduction of 86%.

In the control group, the respective values after 8 weeks follow-up were  $5.9 \pm 2.3$  SD, equivalent to 18% PASI score reduction. Fig. 1 shows the mean values of the PASI score for the different assessment points.

The difference of the PASI score reduction after 8 weeks follow-up between the two groups was statistically significant ( $p < 0.001$ ). Fig. 2-7 show photographs of before and after treatment, with total

**Table II.** PASI assessment.

Score	0	1	2	3	4		
Erythema	0 = none	1 = mild	2 = moderate	3 = severe	4 = very severe		
Infiltration	0 = none	1 = mild	2 = moderate	3 = severe	4 = very severe		
Parakeratosis	0 = none	1 = mild	2 = moderate	3 = severe	4 = very severe		
Score	0	1	2	3	4	5	6
Area %	0	>10	10<30	30<50	50<70	70<90	90<100

resolution of lesions after 8 weeks treatment with Dr Michaels® (Soratinex®) product family for psoriasis.

Six patients in the *verum* and four patients in the control group developed folliculitis as a side effect. Four patients showed minor irritation to the cleansing gel, whilst 6 showed irritation to the ointment during the dermal toxicology and safety test. The results of the remaining test cases were within the EU acceptable range.

## DISCUSSION

This study shows that the herbal skincare products tested improves mild to moderate stable chronic plaque psoriasis significantly. One strength of this study is the clear study design, which is regarded as the gold standard of clinical tests. The left and right side comparison was not undertaken in order to avoid any potential mistakes of mixing up the sides or the use of the more effective product only on both sides. In addition to the personal instructions given on how to use the products, a very simple structured leaflet was also handed out. The patients were informed not to give the blind observer (Assessor) any information on the products used. Furthermore, they did not apply the products on the days of the follow-ups in order to prevent the observer from identifying the *verum* products by their characteristic odour. The blind observer is a consultant of dermatology and is very experienced in clinical scoring. As is well known, the PASI is a standardized internationally accepted evaluation score, which in the hands of

an experienced clinician is a reliable assessment tool. Additionally, photographs were taken with standardized focusing. The images however, lack the third dimension, which represents the infiltration of a psoriatic plaque and contributes to the clinical picture of a lesion essentially.

It was so obvious in the course of the study, that the *verum* products were superior to the *placebo* preparations. All compliant *placebo* patients showed an improvement of the condition, which could be expected when using greasy skin-care products only.

The third requirement is dermal toxicology and safety (6, 7). Before commencing the clinical trial, a dermal toxicology and tolerability test (9) was carried out on a group of 32 healthy volunteers with good results. Among the population of the study presented, 4 patients developed a mild irritative dermatitis and 6 patients developed folliculitis.

We are aware that the excellent (short-term) tolerability of Dr. Michaels® (Soratinex®) skin-care products does not necessarily exclude long-term side effects. However, serious side effects are unlikely due to the toxicologic profile of the constituents (11, 12, 13). In order to assess all the allergic potency, the products should undergo a field test. Possible herbal drug interactions have not been investigated in this trial.

## CONCLUSION

The products tested already fulfil various aspects addressed by the European Parliament in the proposal for a directive on traditional herbal

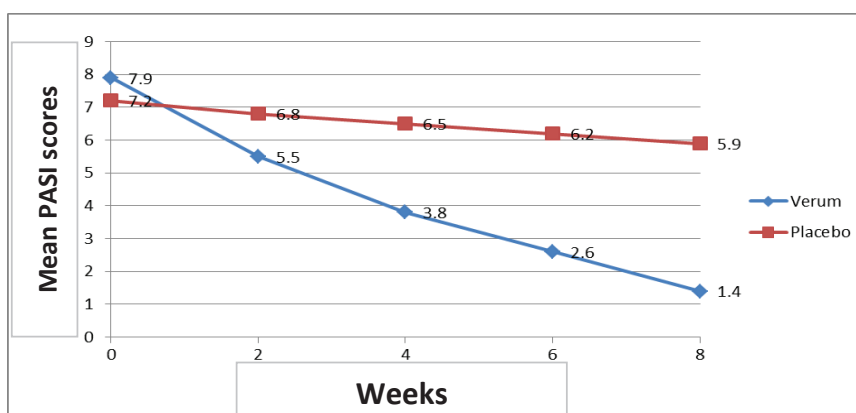
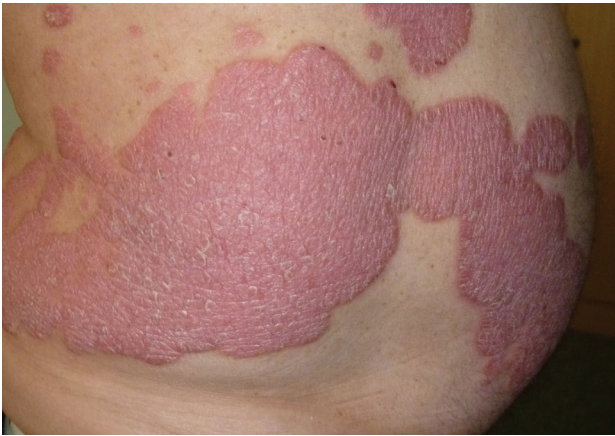
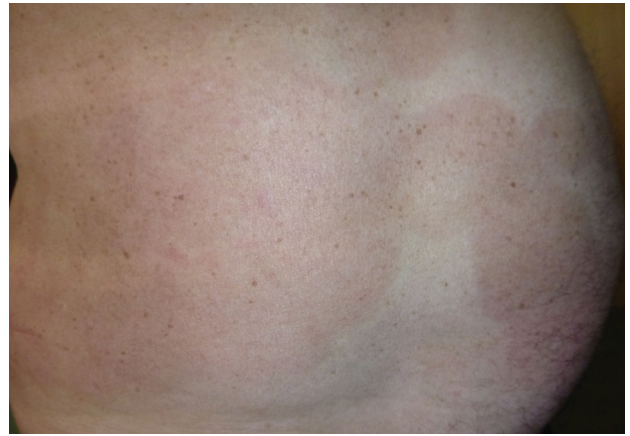
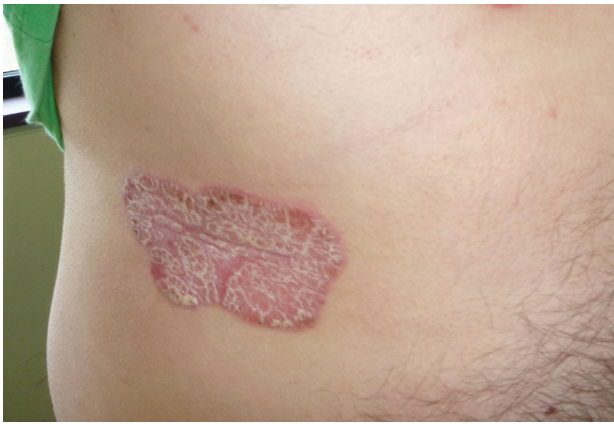Fig. 1. Mean Values of the PASI scores.



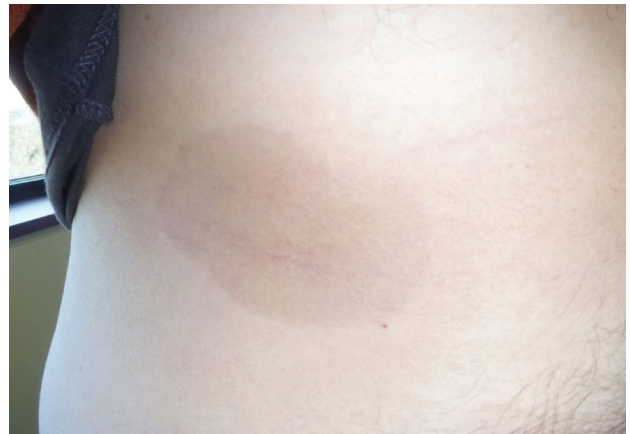**Fig. 2.** *Week 0: Before treatment with Dr Michaels product family.*



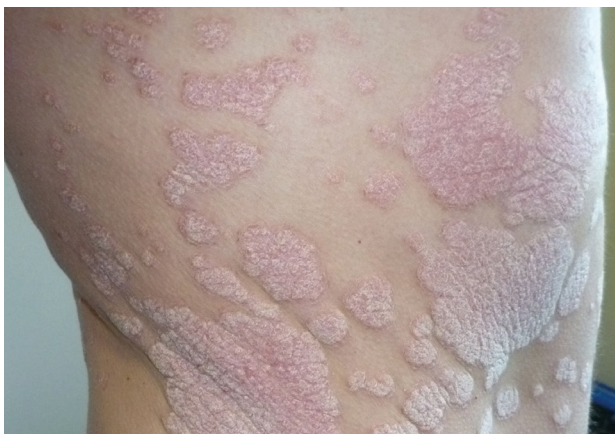**Fig. 3.** *Week 8: After treatment with Dr Michaels product family.*



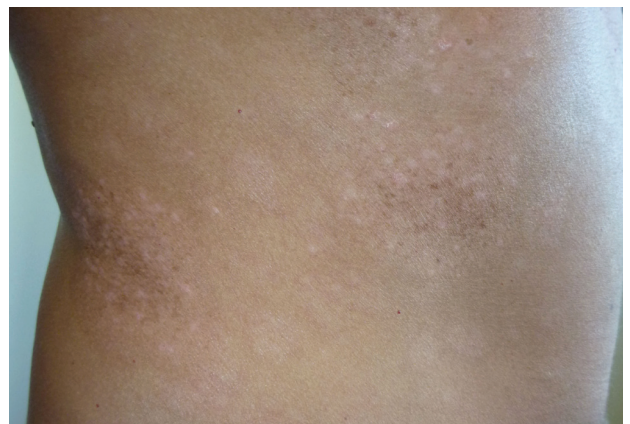**Fig. 4.** *Week 0: Before treatment with Dr Michaels product family.*



**Fig. 5.** *Week 8: After treatment with Dr Michaels product family.*



**Fig. 6.** *Week 0: Before treatment with Dr Michaels product family.*



**Fig. 7.** *Week 8: After treatment with Dr Michaels product family.*

medicinal products (14). As long as the products are composed of a mixture of various plant extracts, a variation range should be defined. The next step, however, should be the attempt to identify the active pharmacologic principle.

Our investigation demonstrates that complementary methods may play a role in dermatologic therapy as long as they undergo standardised clinical trials and fulfil the basic requirements such as product safety and quality assurance. Dr Michaels® (Soratinex®) product family can be used successfully in the treatment of stable chronic plaque psoriasis.

#### ACKNOWLEDGEMENTS

We gratefully acknowledge Tirsell Pty Ltd (Melbourne, Australia) and Frankl Pharma Global Ltd. (2 Parklands Place, Guilford, Surrey, United Kingdom) for providing the products for the studies. We also acknowledge H. Maier et al., Vienna, for previous valuable research published as a Poster in the JEADV.

#### REFERENCES

1. Uva L, Miguel D, Pinheiro C, et al. Mechanisms of action of topical corticosteroids in psoriasis. *Int J Endocrinol* 2012; 2012:561018.
2. Sukarowska BG1, Lipozencić J, Vrzogić P. [Topical corticosteroids and corticosteroid sparing therapy in psoriasis management]. *Acta Med Croatica* 2007; 61(4):375-81.
3. Straus SE. Perspective: Herbal medicines - what's in the bottle? *N Engl J Med* 2002; 347: 1997-8.
4. Ben Arye E, Ziv M, Frenkel M, Lavi I, Rosenman D. Complementary medicine and psoriasis: Linking the patient's outlook with evidence-based medicine. *Dermatology* 2003; 207:302-7.
5. Federspiel K, Herbst V. Die andere Medizin. Nutzen und Risikensanfter Heilmethoden. Stiftung Warentest-Berlin, Verein für Konsumenteninformation-Wien, eds. Stuttgart, Germany: Zenit-Presservertrieb, 1996.
6. De Smet PAGM. Drug therapy: Herbal remedies. *N Engl J Med* 2002; 347:2046-56.
7. Marcus DM, Grollman AP. Botanic medicines - the need for new regulations. *N Engl J Med* 2002; 347:2073-7.
8. Kosmetika – Inhaltsstoffe - Funktionen. Industrieverband Körperpflege- und Waschmittel e.V. (IKW)-Frankfurt a Main, Fachverband der chemischen Industrie Österreichs (FCIO) Berufsgruppe Körperpflegemittel-Wien, eds. Garching, Germany: Heichlinger Druckerei GmbH, 1998.
9. Langley RG, Ellis CN. Evaluating psoriasis with psoriasis area and severity index, psoriasis global assessment, and lattice system physician's global assessment. *J Am Acad Dermatol* 2004; 51:563-9.
10. Mann HB, Whitney DR. On a test of whether one of two random variables is statistically larger than the other. *Annals of Mathematical Statistics* 18(1):50-60.
11. Mayrhofer A, Wieser M, Wollein G. Entwicklung eines Screening-Systems für die Untersuchung corticoidverdächtiger Proben mittels HPLC-UV und HPLC-PB-MS. *Sci Pharm* 1996; 64:225-44.
12. Frosch PJ, Kligman AM. The soap chamber test: a new method for assessing the irritancy of soaps. *J Am Acad Dermatol* 1979; 1(1):35-41.
13. Izzo AA, Hoon-Kim S, Radhakrishnan R, Williamson EM. A critical approach to evaluating clinical efficacy, adverse events and drug interactions of herbal remedies. *Phytother Res* 2016; 30(5):691-700.
14. Proposal for a directive of the European parliament and the council amending the directive 2001/83/EC as regards traditional herbal medicinal products. *Official Journal of the European Communities* 2002; 263-7.



## A CLINICAL EXAMINATION OF THE EFFICACY OF PREPARATION OF DR MICHAELS® (ALSO BRANDED AS SORATINEX®) PRODUCTS IN THE TREATMENT OF PSORIASIS

J. HERCOGOVÁ<sup>1,2</sup>, M. FIORANELLI<sup>3</sup>, S. GIANFALDONI<sup>4</sup>, A.A. CHOKOEVA<sup>5,6</sup>,  
G. TCHERNEV<sup>7</sup>, U. WOLLINA<sup>8</sup>, M. TIRANT<sup>9</sup>, F. NOVOTNY<sup>10</sup>, M.G. ROCCIA<sup>11</sup>, G.K.  
MAXIMOV<sup>12</sup>, K. FRANÇA<sup>13,14</sup> and T. LOTTI<sup>15</sup>

<sup>1</sup>2nd Medical Faculty, Charles University, Bulovka Hospital, <sup>2</sup>Institute of Clinical and Experimental Medicine, Prague, Czech Republic; <sup>3</sup>Department of Nuclear Physics, Sub-nuclear and Radiation, G. Marconi University, Rome, Italy; <sup>4</sup>Dermatological Department University of Pisa, Pisa, Italy; <sup>5</sup>"Onkoderma"-Policlinic for dermatology and dermatologic surgery, Sofia, Bulgaria; <sup>6</sup>Department of Dermatology and Venereology, Medical University of Plovdiv, Medical faculty, Plovdiv, Bulgaria; <sup>7</sup>Medical Institute of Ministry of Interior (MVR), Department of Dermatology, Venereology and Dermatologic Surgery, Sofia, Bulgaria; <sup>8</sup>Department of Dermatology and Allergology, Academic Teaching Hospital Dresden-Friedrichstadt, Dresden, Germany; <sup>9</sup>Psoriasis & Skin Clinic, Melbourne, Australia, <sup>10</sup>PRO SANUM Ltd, Sanatorium of Prof. Novotný, Štěpánská Prague 1, Czech Republic; <sup>11</sup>University B.I.S. Group of Institutions, Punjab Technical University, Punjab, India; <sup>12</sup>Department "Medicinal Information and Non-interventional studies", Bulgarian Drug Agency; Sofia, Bulgaria; <sup>13</sup>Department of Dermatology & Cutaneous Surgery, Department of Psychiatry & Behavioral Sciences, Institute for Bioethics & Health Policy, University of Miami, Miller School of Medicine, Miami, FL, USA; <sup>14</sup>Centro Studi per la Ricerca Multidisciplinare e Rigenerativa, Università Degli Studi "G. Marconi"-Rome, Italy; <sup>15</sup>Chair of Dermatology, University of Rome "G. Marconi" Rome, Italy

Psoriasis is a chronic inflammatory disease with negative impacts both physically and psychologically. It is a common disorder affecting 2-3% of the total world population, in some cases causing changes to the nail and joints as well as skin lesions. The cutaneous manifestations of psoriasis can vary in morphology and severity and therapy should be tailored accordingly. The aim of the study was to investigate the efficacy of Dr Michaels® (Soratinex®) product line in the treatment of psoriatic patients with different age and disease severity. A total number of 270 patients with verified psoriasis, aged 9-60 years old participated in the studies, including 128 children: 23 girls and 105 boys, (all of them selected from the Department of Dermato-allergology of the Russian Pediatric Hospital Clinic, Moscow, and of the 4th Department of Dermatology of the 52nd Moscow City Hospital Clinic). The patients were separated into 3 groups according to the severity of the disease (based on the PASI-index). All the patients have been treated with Dr Michaels® (Soratinex®) products twice daily, as three different forms were available for application: a cleansing gel, an ointment and a conditioner. The severity of the disease and the efficacy of the treatment have been defined with the evaluation of the PASI index of each patient. The obtained results were recorded in a graphic form showing the changes of the PASI-index on days 3, 7, 14, and 21 counted from the start of the trial. Clinical remission was achieved in 147 patients, a significant improvement in 73, partial improvement in 32, while no effect was seen in 12 patients and deterioration in 6. This open trial demonstrated the clinical efficacy of topical application of Dr Michaels® (Soratinex®) preparation. We observed clinical remissions of psoriasis in adults and in children.

*Key words: psoriasis, psoriasis area and severity index, children, adults, plaque psoriasis, efficacy, patient satisfaction*

Mailing address:  
Professor Torello Lotti,  
Department of Dermatology,  
University of Rome "G. Marconi",  
Rome, Italy  
e-mail: professor@torelloLotti.it

15(S3)

0393-974X (2016)  
Copyright © by BIOLIFE, s.a.s.  
This publication and/or article is for individual use only and may not be further reproduced without written permission from the copyright holder.  
Unauthorized reproduction may result in financial and other penalties  
DISCLOSURE: ALL AUTHORS REPORT NO CONFLICTS OF INTEREST RELEVANT TO THIS ARTICLE.

Psoriasis is an inflammatory T cell-mediated autoimmune disease of skin and joints, which may have a major impact on a patient's life (1, 2, 3).

Psoriasis has posed a serious problem in health care and social issues for a long time, partly because the disease affects 1 to 3% of the world's population and partly because the treatment results are extremely modest, especially through topical approaches<sup>4</sup>. Approximately 30% of psoriasis patients are also affected with the psoriatic arthritis. There is also a greater frequency of autoimmune diseases among patients with psoriasis (2, 5).

Scientific evidence has shown that treatment of psoriatic lesions during the first years is conservative and frequently done with topical agents (6). International and national experiences affirm that the preparations most frequently used, i.e. topical corticosteroids with or without vitamin D-derivate are not always effective. Furthermore, the treatment is of considerable duration and frequently causes side effects (4, 7, 8). Therefore, the development and introduction of a product line of non-hormonal basis suitable for external treatment of psoriasis is exceptionally important since the prolonged

application of steroid preparations cause a number of unwanted local and systemic effects in patients.

#### *Aim of the study*

To evaluate the efficacy and safety of Dr Michaels® (Soratinex®) product line in psoriatic patients of different age and disease severity groups.

## MATERIALS AND METHODS

The study has been conducted in a Russian population of patients, selected from outpatient clinics with verified diagnosis of psoriasis, (Department of Dermato-allergology of the Russian Pediatric Hospital Clinic, Moscow and of the 4<sup>th</sup> Department of Dermatology of the 52<sup>nd</sup> Moscow City Hospital Clinic.)

Twohundredandseventy patients, aged 9-60 years old, participated in the studies. As far as children were concerned, 23 girls and 105 boys participated, while the ratio for adults was 46 women and 96 men (Table I).

Before starting the treatment, laboratory and physical examinations were completed on each patient with verified diagnosis of psoriasis. The duration of the disease persistence ranged between 4 months and 21 years and the

**Table I:** Demographic data of the study population.

Age groups	Age of the Patients (years)	Girls	Boys	Total
<b>Children</b>	<b>0-5</b>	-	-	-
	<b>5-10</b>	<b>16</b>	<b>18</b>	<b>34</b>
	<b>10-16</b>	<b>7</b>	<b>87</b>	<b>94</b>
	<b>Children total</b>	<b>23</b>	<b>105</b>	<b>128</b>
	Age of the Patients (years)	Women	Men	Total
<b>Adults</b>	<b>16-20</b>	<b>18</b>	<b>9</b>	<b>27</b>
	<b>20-30</b>	<b>19</b>	<b>27</b>	<b>46</b>
	<b>30-4-</b>	-	<b>29</b>	<b>29</b>
	<b>40-50</b>	<b>9</b>	-	<b>9</b>
	<b>50-60</b>	-	<b>31</b>	<b>31</b>
	<b>Total of Adults</b>	<b>46</b>	<b>96</b>	<b>142</b>
	<b>Total of Patients</b>	<b>69</b>	<b>201</b>	<b>270</b>

duration of the latest exacerbation was between 1 week and 29 months.

The patient group was subdivided into three groups based on the PASI-index values calculated during the preliminary tests according to the severity of the skin lesion (Table II).

All the patients of different age groups were treated with Dr Michaels® (Soratinex®) twice daily: in the morning and in the evening. Dr Michaels® (Soratinex®) product line offers three different preparations: a gel, an ointment and a conditioner (Table III).

## RESULTS

The efficacy of the treatment used was evaluated as follow:

- Clinical remission (improvement of PASI by 90-100%);
- Significant improvement (improvement of PASI by 75-90%);
- Improvement (improvement of PASI by 50-75%);
- Lack of change (change of PASI of <50%);
- Deterioration.

The results were recorded in a graphic form showing the changes of the PASI-index on days 3, 7, 14 and 21 counted from the start of the experiment (Table IV).

In the case of 43 patients out of the 72 patients of group 3 (disease with a severe course), on day 3 of the treatment itching and desquamation decreased significantly in the foci. At the same time, the overall

**Table II:** Distribution of patients according to the severity of the disease (according to the PASI-index) (9).

Patient Groups	Severity of the Disease (PASI)	Average Values of the PASI-index (control tests)	Number of Patients
<b>I</b>	<b>Mild 0-20</b>	<b>9.1</b>	<b>116</b>
<b>II</b>	<b>Moderately severe 20-50</b>	<b>38.2</b>	<b>82</b>
<b>III</b>	<b>Severe &gt; 50</b>	<b>64.7</b>	<b>72</b>
		<b>Total</b>	<b>270</b>

**Table III:** Composition and application of Dr Michaels® (Soratinex®) Product Line.

Dr Michaels® (Soratinex®) Scalp and Body Cleansing Gel	Ingredients: Actives - salicylic acid, citric & glycolic acids Application: Applied before the use of the ointment. Scalp: Wet scalp and apply a small amount of cleansing gel. Massage thoroughly and leave for 2-3 minutes. Wash off with lukewarm water. (Can be applied to forehead but avoid cheek area). Body: Wet body. Apply small amount of cleansing gel to the psoriatic plaques. Leave for 2-3 minutes then rinse off with lukewarm water.
Dr Michaels® (Soratinex®) Scalp and Body Ointment	Ingredients: In a base of petrolatum Zinc oxide, Salicylic acid and essential oils such as Orange Oil, Rosemary Oil, Chamomile Oil Application: Applied to the psoriatic plaques of the scalp and body after using and washing off the cleansing gel. Only apply to severely infiltrated plaques on the scalp.
Dr Michaels® (Soratinex®) Skin Conditioner	Ingredients: Essential oils such as lavender oil, eucalyptus oil, natural vitamin E. Application: Applied to the psoriatic plaques two minutes after using the ointment (without washing it off).

**TABLE IV:** *The Clinical Efficacy of Dr Michaels® (Soratinex®) Preparations.*

Results of the treatment	Degree of Severity of the Disease			
	Mild (n=116) Group 1	Moderate (n=82) Group 2	Severe (n=72) Group 3	Total
Clinical remission	91	36	20	147
Significant improvement	11	28	34	73
Improvement	-	15	17	32
No effect	9	2	1	12
Deterioration	5	1	-	6
Total	116	82	72	270

PASI-value only slightly decreased compared to the initial value (16%). By day 7 of the treatment, significant improvements were observed in the general condition of 40 patients with significant alleviation of itching accompanied by the disappearance of erythema and alleviation of desquamation and infiltration. The overall PASI-value decreased by 48% compared to the initial value. On day 14, the decrease of the PASI-index value exceeded 78% compared to the initial value. In the case of 20 patients, itching and desquamation ceased completely. By day 21 of the experiment, significant improvement was observed in the case of 34 patients, improvement was observed in the case of 17 patients and no clinical effect was observed in one case. The PASI-index decreased from 62.7 to 0.6.

As far as group 2 representing patients with moderately severe cases is concerned, in the case of 79 patients out of 82 patients, itching and desquamation significantly dropped.

Starting from day 3 of the treatment, the improvement proved to be stable in 36 out of the 80 and manifested in decrease of itching and desquamation until day 14, when the symptoms completely disappeared. By day 21 of the treatment,

the condition of 28 patients improved significantly, 15 patient's condition improved and clinical remission was observed in the case of 36 patients. The average PASI-value in the case of this group decreased from 38.2 to 2.3. In one patient, the skin worsened due to individual sensibility to the preparation. After the termination of the treatment, the condition of the patient returned to normal. The treatment had no effect for 2 patients.

With reference to group 1 (patients with a mild form of the disease), a definite improvement was observed in the condition of 22 patients out of 116 as early as the first day of treatment. By day 14 of the experiment, itching (52 patients) as well the inflammatory symptoms (erythema/9 patient, oedema/22 patients) ceased completely. By day 21 of the experiment, clinical remission was observed in 91 patients out of group 1. The PASI-index decreased by 90.6% compared to the initial value. Four patients of the group developed contact dermatitis during the treatment, so they were excluded from the study. Another patient had used the whole amount of ointment within 2 days, which led to deterioration of psoriasis. Consequently, this patient was excluded

from the study. Fig. 1 and 2 show photographs of the patient before and after treatment, with total resolution of lesions after 21 days of treatment.

### CONCLUSIONS

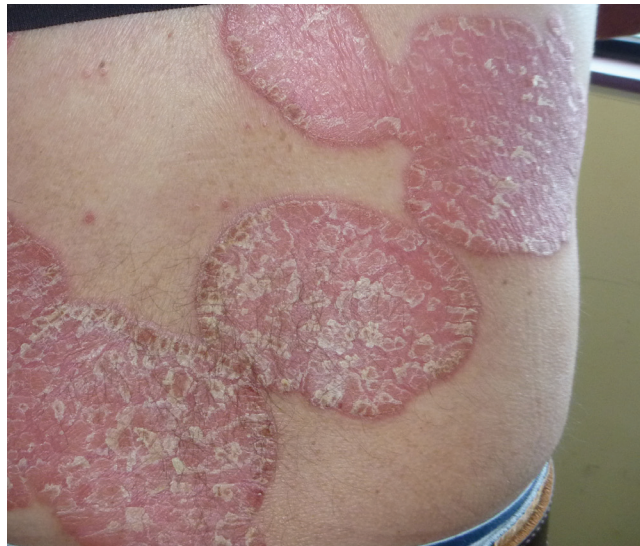In summary, in the application of Dr Michaels<sup>®</sup> (Soratinex<sup>®</sup>) preparation, we observed clinical remission during the treatment of psoriasis in adults and children. This meant a complete resolution of the

plaques in 147 patients, significant improvement in 73 patients and improvement in 32 patients.

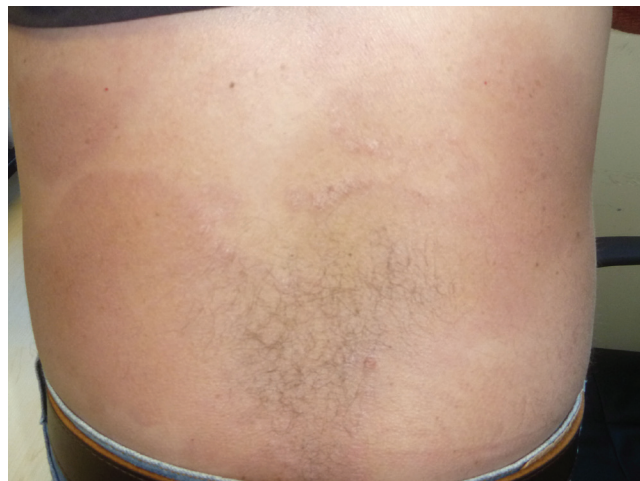
Twelve patients did not see any changes in their condition while 6 patients developed side effects, which normalized upon cessation of the treatment.

### ACKNOWLEDGEMENTS

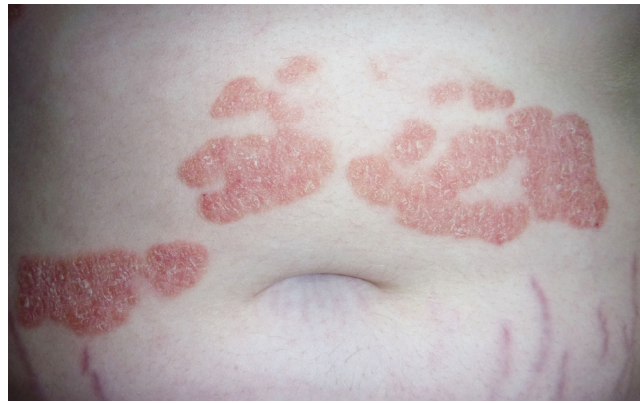We gratefully acknowledge Tirsell Pty Ltd (Melbourne, Australia) and Frankl Pharma Global



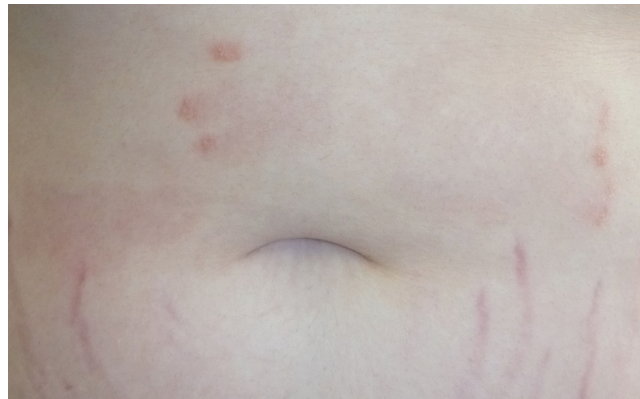**Fig. 1a. Day 0):** Before treatment with Dr Michaels product family.



**Fig. 1b. Day 21):** After treatment with Dr Michaels product family.



**Fig. 2a. Day 0):** Before treatment with Dr Michaels product family.



**Fig. 2b. Day 21):** After treatment with Dr Michaels product family.

Ltd. (2 Parklands Place, Guilford, Surrey, United Kingdom) for providing the products for the studies.

#### REFERENCES

- Schäkel K, Schön MP, Ghoreschi K. Pathogenesis of psoriasis. *Hautarzt*; 2016.
- Karczewski J, Dobrowolska A, Rychlewska-Hańczewska A, Adamski Z. New insights into the role of T cells in pathogenesis of psoriasis and psoriatic arthritis. *Autoimmunity* 2016; 1-16.
- Vaidya TS, Anderson KL, Feldman SR. Even well controlled psoriasis patients have unmet treatment needs regardless of disease severity. *Dermatol Online J* 2015; 21(9).
- Augustin M, Eissing L, Langenbruch A, et al. The German national program on psoriasis health care 2005-2015: results and experiences. *Arch Dermatol Res* 2016; (Epub ahead of print).
- Wu JJ, Nguyen TU, Poon KY, Herrinton LJ. The association of psoriasis with autoimmune diseases. *J Am Acad Dermatol* 2012; 67(5):924-30.
- Girolomoni G, et al. Early intervention in psoriasis and immune-mediated inflammatory diseases: A hypothesis paper. *J Dermatolog Treat* 2015; 26(2):103-12.
- Eliasson L, Bewley T, Mughal F, Johnston K, Kuznik A, Lloyd AJ. Evaluation of psoriasis patients' attitude to risk: benefit and therapeutic tradeoffs in their choice of treatments. *Value Health* 2015; 18(7):A425.
- Nishikawa R, Nagai H, Bito T, Ikeda T, Horikawa T, Adachi A, Matsubara T, Nishigori C. Genetic prediction of the effectiveness of biologics for psoriasis treatment. *J Dermatol*. 2016 Apr 30. doi: 10.1111/1346-8138.13412. (Epub ahead of print).
- Fredriksson T, Pettersson U. Severe psoriasis - oral therapy with a new retinoid. *Dermatologica*. 1978;157(4):238-44.

## NAIL PSORIASIS IN AN ADULT SUCCESSFULLY TREATED WITH A SERIES OF HERBAL SKIN CARE PRODUCTS FAMILY – A CASE REPORT

M. TIRANT<sup>1</sup>, J. HERCOGOVÁ<sup>2,3</sup>, M. FIORANELLI<sup>4</sup>, S. GIANFALDONI<sup>5</sup>, A.A. CHOKOEVA<sup>6,7</sup>,  
G. TCHERNEV<sup>8</sup>, U. WOLLINA<sup>9</sup>, F. NOVOTNY<sup>10</sup>, M.G. ROCCIA<sup>11</sup>,  
G.K. MAXIMOV<sup>12</sup>, K. FRANÇA<sup>13,14</sup> and T. LOTTI<sup>15</sup>

<sup>1</sup>Psoriasis & Skin Clinic, Melbourne, Australia; <sup>2</sup>2nd Medical Faculty, Charles University, Bulovka Hospital; <sup>3</sup>Institute of Clinical and Experimental Medicine, Prague, Czech Republic; <sup>4</sup>Department of Nuclear Physics, Sub-nuclear and Radiation, G. Marconi University, Rome, Italy; <sup>5</sup>Dermatological Department University of Pisa, Pisa, Italy; <sup>6</sup>“Onkodermatologia” - Policlinic for dermatology and dermatologic surgery, Sofia, Bulgaria; <sup>7</sup>Department of Dermatology and Venereology, Medical University of Plovdiv, Medical faculty, Plovdiv, Bulgaria; <sup>8</sup>Medical Institute of Ministry of Interior (MVR), Department of Dermatology, Venereology and Dermatologic Surgery, Sofia, Bulgaria; <sup>9</sup>Department of Dermatology and Allergology, Academic Teaching Hospital Dresden-Friedrichstadt, Dresden, Germany; <sup>10</sup>PRO SANUM Ltd., Sanatorium of Prof. Novotný, Štěpánská Prague 1, Czech Republic; <sup>11</sup>University B.I.S. Group of Institutions, Punjab Technical University, Punjab, India; <sup>12</sup>Department “Medicinal Information and Non-interventional studies”, Bulgarian Drug Agency, Sofia, Bulgaria; <sup>13</sup>Department of Dermatology & Cutaneous Surgery; Department of Psychiatry & Behavioral Sciences, Institute for Bioethics & Health Policy, University of Miami, Miller School of Medicine, Miami, FL, USA; <sup>14</sup>Centro Studi per la Ricerca Multidisciplinare e Rigenerativa- Università Degli Studi “G. Marconi”, Rome, Italy; <sup>15</sup>Chair of Dermatology, University of Rome “G. Marconi” Rome, Italy

**Psoriasis is a common chronic inflammatory dermatosis that causes significant distress and morbidity. Approximately 50% of patients with cutaneous psoriasis and 90% of patients with psoriatic arthritis demonstrate nail involvement of their psoriasis. Left untreated, nail psoriasis may progress to debilitating nail disease that leads to not only impairment of function but also on quality of life. We report the case of a 50-year-old male patient with recalcitrant nail dystrophies on the fingers since the age of 40, who responded successfully to Dr. Michaels® product family. The patient had a 35-year history of plaque psoriasis localised on the scalp, ears, groin, limbs, and trunk and with psoriatic arthritis. The nail symptoms consisted of onycholysis, onychomycosis, leukonychia, transverse grooves, nail plate crumbling and paronychia of the periungual skin. This case represents the efficacy and safety of the Dr. Michaels® (Soratinex® and Nailinex®) product family with successful resolution of nail dystrophies and surrounding paronychia with no reported adverse events.**

Psoriasis is a chronic and recurrent inflammatory dermatosis affecting the skin, nails and joints. Nail involvement is one of the most common manifestations of psoriasis as it occurs in 50% of

patients with skin involvement only and in 90% of patients with psoriatic arthritis (PsA) (1). When left untreated, nail psoriasis causes significant pain and discomfort and thus is a leading cause for impairment

*Key words: psoriatic nails, psoriatic arthritis, plaque psoriasis, nail dystrophies, subungual hyperkeratosis, onycholysis, onychomycosis, paronychia, treatment*

Mailing address:  
Professor Torello Lotti,  
Department of Dermatology,  
University of Rome “G. Marconi”,  
Rome, Italy  
e-mail: professor@torelloLotti.it

of quality of life and work function (2).

Nail psoriasis is characterised clinically by manifestations on the fingernails and toenails. The mean delay of onset for nail dystrophies occurs in individuals with psoriasis between 9 and 11.5 years, explaining the lower prevalence of nail psoriasis in children (1, 3). Clinically, nail psoriasis has many presentations depending on the location of the inflammatory process and includes nail pitting, leukonychia, onycholysis, oil drop patches, subungual hyperkeratosis and splinter haemorrhages (4), the most common manifestation of which is nail pitting (5). Pits generally affect the fingernails more often than the toenails and are superficial punctate depressions in the nail plate. Nail pitting occurs as a result of an interference of normal keratinization within the nail matrix (6).

The pathogenesis of psoriatic nail disorder is yet to be fully defined, however, it is thought to be multifactorial and involve a complex interplay between genetic, environmental and immune factors. Recently, there has been strong evidence to suggest that the pathogenesis of nail psoriasis may be linked to psoriatic arthritis (7). This study by McGonagle and colleagues shows that the nail and the enthesis, a ligament or tendon that directly attaches to the bone, via the distal interphalangeal (DIP) joint extensor tendon are key players in the pathophysiology of nail psoriasis. Specifically, they found that the extensor tendon, at its enthesis, is able to send superficial fibres, which contribute to the formation of a thick periosteum on the dorsal aspect of the distal phalanx. Thus, linking the dense fibrous connective tissue from the nail plate to the periosteum and indirectly to the extensor tendon (7). This study suggests that there is an association between the DIP joint arthritis and nail disease due to the close interaction between the nail, joint and its associated tendons and ligaments. This is supported by the fact that although the nail system has no neural component as such and psoriasis is generally considered a painless condition, 50% of patients with nail psoriasis observe pain (8).

#### *Case report*

A 50-year-old male is affected by psoriatic nail dystrophies from the age of 40. The patient presented

with psoriasis of the scalp, ears, groin, limbs and nails. There was a family history of psoriasis and the patient's father was confirmed with the condition.

For the cutaneous psoriasis, the patient had used multiple therapies over time, starting with steroids such as hydrocortisone acetate Sigmacort 1% twice daily, then corticosteroids such as betamethasone dipropionate - Diprosone Ointment 0.05% twice daily. Only partial resolution was achieved and relapse followed after stop of treatment. Patient had also been on several intermittent, sequential and rotational treatments such as methotrexate, cyclosporine and oral retinoids, either as standalone or combination treatment regimes, all providing only temporary relief of the cutaneous psoriasis but little or no improvement of the psoriatic nails.

The patient was very stressed and embarrassed about the flaky scalp and affected nails, as he had a management job which involved meetings and dealing with the public. The nail dystrophies had worsened over the last 10 years. It had become progressively difficult and painful to use the fingers for gripping cutlery, pens and tools and performing tasks such as buttoning clothes, which are taken for granted. The fingertips and joints were painful. He had to discontinue his sporting activities including golf and swimming. His cutaneous and nail psoriasis were severely impacting his social, personal and marital relationships and his sex life. He was depressed and lonely and self-conscious. His confidence level was very low. As he had stopped all physical exercise, his weight had increased and his blood pressure increased to 148/105. He was on Micardis 50mg twice daily.

Examination revealed parakeratotic and hyperkeratotic psoriatic plaques of the scalp, ears, limbs and groin. Also present were psoriatic nail dystrophies, including onycholysis, onychomycosis, leukonychia, transverse grooves, nail plate crumbling and paronychia on the periungual skin (Fig. 1, 2).

The patient was prescribed Dr Michaels<sup>®</sup> (Soratinex<sup>®</sup>) cleansing gel, Dr Michaels<sup>®</sup> (Nailinex<sup>®</sup>) lotion and ointment, and oral herbal formulation, PSC 500.

The cleansing gel contains salicylic acid and glycolic which have keratolytic, anti-inflammatory



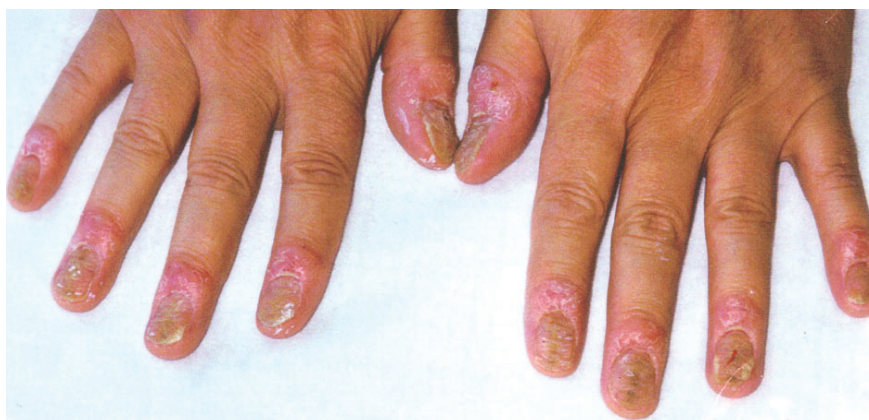and antiseptic actions. Salicylic acid facilitates desquamation by solubilizing the intercellular cement that binds scales in the nail plate, thereby loosening the keratin and facilitating the penetration of other medicaments into the nail plate.

The keratolytic effect of Salicylic acid may also provide an antifungal action because the disruption of the keratin also suppresses fungal growth. It also aids in the penetration of other antifungal agents. Salicylic acid also has a mild antiseptic action and possesses anti-inflammatory, anti-pruritic, analgesic and antimicrobial properties. Its anti-inflammatory and analgesic action appears to be mediated by

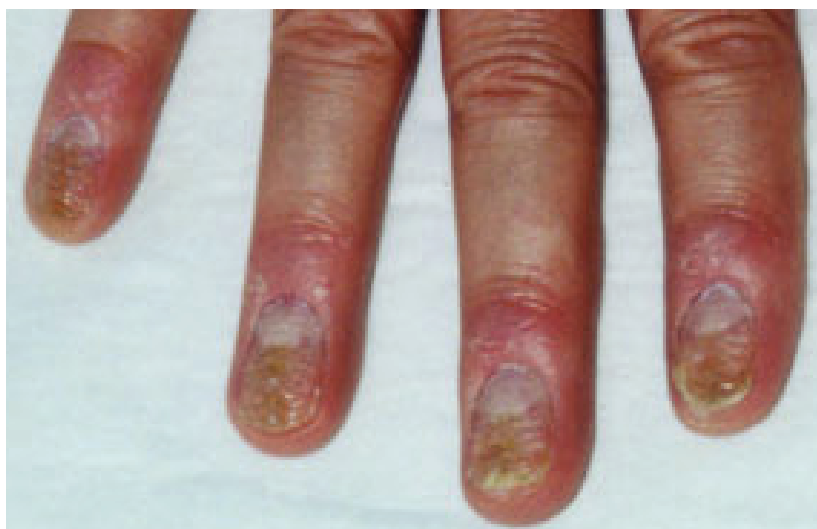the inhibition of prostaglandin synthesis via the inhibition of the cylo-oxygenase enzyme (9, 10).

The nail lotion contains a combination of essential oils, including tea tree oil, mustard oil, orange oil, oregano, ginger and tangerine, which have antibacterial, anti-fungal, anti-microbial, anti-viral and anti-inflammatory, anti-pruritic and analgesic properties.

The nail lotion provides an evaporative, cooling, vasoconstriction and resultant mild antipruritic effect. It soothes and cools inflamed skin, dry oozing lesions, softens crusts, aids in cleaning wounds and assists in the drainage of purulent wounds



**Fig. 1.** Prior to treatment with Dr Michaels<sup>®</sup> (Soratinex<sup>®</sup> and Nailinex<sup>®</sup>) product family, the patient presented with severe psoriatic nail dystrophies. These include onycholysis, onychomycosis, leukonychia, transverse grooves, nail plate crumbling and paronychia on the periungual skin.



**Fig. 2.** Higher power magnification of fig. 1. This photograph illustrates onycholysis, onychomycosis, leukonychia, transverse grooves, nail plate crumbling and paronychia on the periungual skin.

surrounding the nail. The tea tree oil component has shown to increase fungal cell permeability and membrane fluidity and inhibited medium acidification. One of its components, terpenes, are thought to induce alterations in cell permeability by inserting itself between the fatty acyl chains that make up the membrane lipid bilayers, disrupting lipid packing and causing changes to membrane properties and functions ( 11, 12).

The ointment contains essential oils that are known for their hydrophobicity, which enables them to partition the lipids of the bacterial cell membrane and mitochondria, disturbing the cell structures and rendering them more permeable. Extensive leakage from bacterial cells or the exit of critical molecules and ions will lead to death. It is generally proposed that most essential oils target microbial cell membranes, affecting their integrity or permeability or compromising membrane-associated functions (primarily respiration), through fungal cell wall polymer degradation, membrane channel and pore formation, damage to ribosomes inhibition of DNA synthesis and cell cycle (13).

The PSC 500 contains active ingredients including silica-colloidal anhydrous, zinc, and *Equisetum arvense*, which is also a rich source of

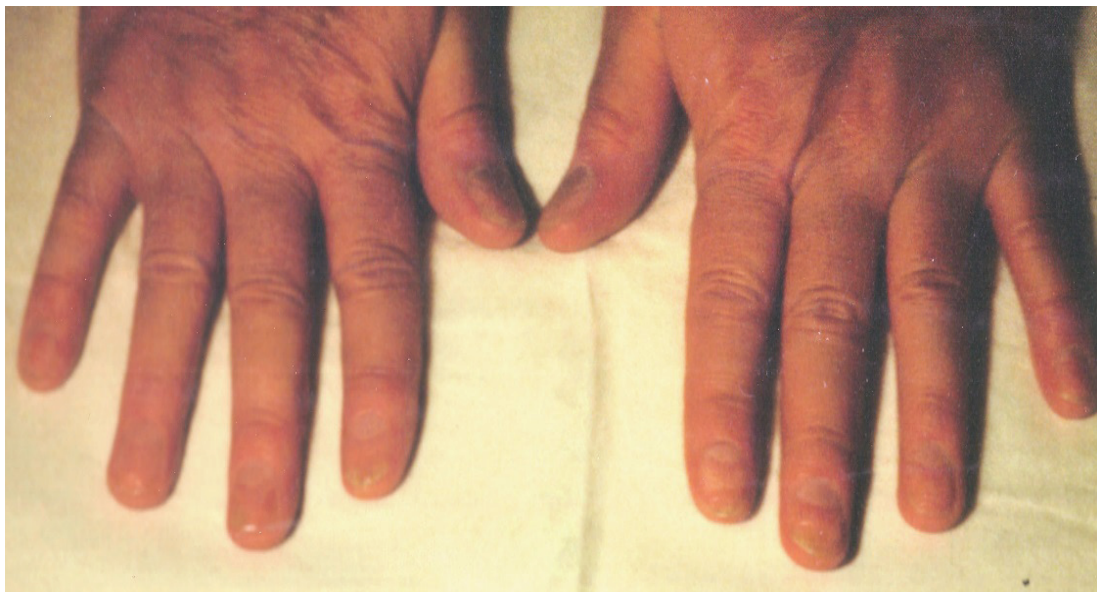
silica. Silica is involved in the formation of bone, collagen, keratin and connective tissue through its role as a component or facilitator in the formation of glycosaminoglycans. Improvement in skin isotropy and roughness and nail/hair brittleness have been observed following supplementation of silica. Nail dystrophy has been reported as a symptom of zinc deficiency and that a “cause and effect” relationship has been established between the dietary intake of zinc and maintenance of normal nails (13).

Assessment of improvements was based on modified Nail Psoriasis Severity Index (mNAPSI).

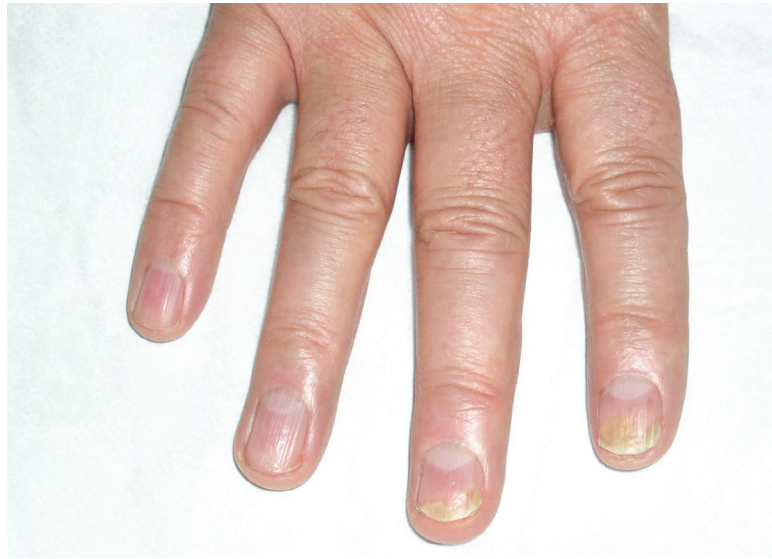## RESULTS

After 4 months of treatment using Dr Michaels® (Soratinex® and Nailinex®) cleansing gel, nail lotion, ointment and oral PSC 500, the patient achieved a significant improvement with an almost complete resolution in all parameters of his psoriatic nails. Specifically, there was a significant reduction in subungual hyperkeratosis, onycholysis, onychomycosis and pitting of the nail beds (Fig. 3, 4, 5). There was a mNAPSI score reduction from 30 to 6.

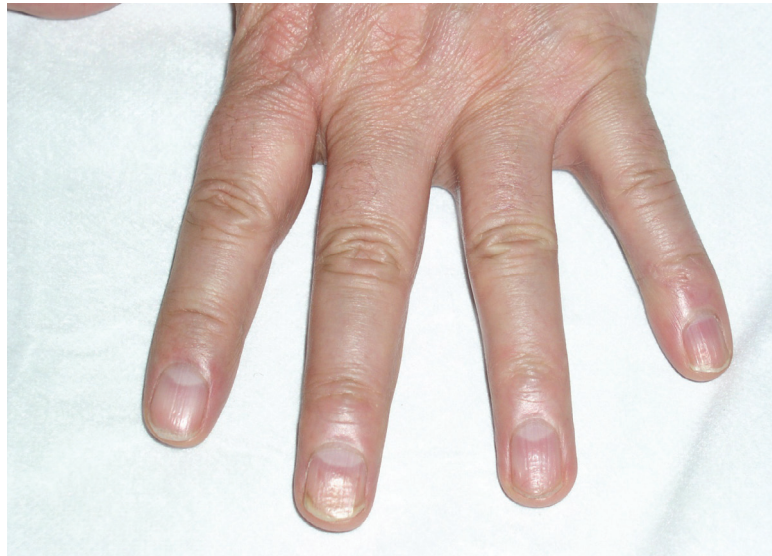The patient is extremely happy with the results for his nails and he continues to use Dr Michaels®



**Fig. 3.** Following 4 months of treatment with the Dr Michaels® (Soratinex® and Nailinex®) product family, the patient shows an almost complete resolution of psoriatic nail dystrophies and paronychia on the periungual skin. Minor nail pitting and some onycholysis only remains under three nails.



**Fig. 4.** Following 4 months of treatment with the Dr Michaels® (Soratinex® and Nailinex®) product family, the patient shows an almost complete resolution of psoriatic nail dystrophies and paronychia on the periungual skin. Minor nail pitting and some onycholysis only remains under two nails.



**Fig 5.** Following 4 months of treatment with the Dr Michaels® (Soratinex® and Nailinex®) product family, the patient shows an almost complete resolution of psoriatic nail dystrophies and paronychia on the periungual skin. Minor nail pitting on some nails and some onycholysis remains under one nail only.

(Soratinex® and Nailinex®) product family on a maintenance basis with no adverse effects after 14 years. Interestingly, his cutaneous psoriasis has also improved markedly.

## DISCUSSION

Nail psoriasis is often difficult to control and the results are often unsatisfactory. Treatment options for

nail psoriasis include various topical and systemic therapies. These are often dependent on the severity of the condition and whether skin and/or joints are involved. Current treatments for nail psoriasis can be classified into topical therapy, intra-lesional injections, photochemotherapy, laser therapy, radiotherapy and systemic therapy such as biologics.

The most commonly utilised topical therapy for nail psoriasis include corticosteroids and vitamin D3 analogues (6, 14). Additional topical treatments for nail psoriasis include tacrolimus, fluorouracil, topical cyclosporine, tazaroten and anthralin. Radiotherapy can be used in recalcitrant cases.

Intra-lesional injections of corticosteroids, such as triamcinolone acetonide are an effective treatment approach as it allows for the penetration of the corticosteroid into the nail matrix. This treatment option, although considered relatively safe, has been associated with complications arising from needless injectors including blood splash back. There has also been a report of a treated digit requiring amputation after the development of epidermoid inclusion cysts (5).

Phototherapy is well established for the treatment of cutaneous psoriasis; however, its effectiveness in psoriatic nails is not well described (6), whilst laser therapy has been shown to cause a significant improvement in NAPS I scores in patients with nail psoriasis (15). Although radiotherapy is not routinely utilised in the field of dermatology, superficial radiotherapy and electron beam therapy may confer temporary benefit in nail psoriasis (6).

Systemic therapy is generally prescribed to patients who demonstrate combined skin and nail disease where the nail involvement is moderate to severe. Systemic therapies include methotrexate, which is often prescribed as a combination with topical therapy (16). When the above therapies fail, tumour necrosis factor alpha inhibitors or other biologics are prescribed (etanercept, infliximab or adalimumab) (17).

Although corticosteroids are the preferred topical treatment of nail psoriasis, there are negatives associated with this treatment approach. A number of studies have illustrated that certain corticosteroids, such as clobetasol propionate, have a low absorption rate when applied and as a result are associated with

only slight improvements (18). Whilst systemic treatments are generally prescribed in severe cases, patients however, have concerns due to the potential side-effect profiles of these therapies. Treatment with methotrexate has been associated with hepatic, pulmonary and bone marrow toxicity, as well as teratogenicity (19).

Nail psoriasis is a common feature of psoriasis and often is associated with functional impairment of manual dexterity, pain and psychological distress (20).

Traditional first-line therapies for nail psoriasis include topical corticosteroids. The second-line options include systemics such as methotrexate. Failing first- and second-line treatment options, a newer class of drugs, such as biologics, are often prescribed. Although traditional therapies are effective, there are also associated limitations. For example, methotrexate is contraindicated in individuals with severely impaired hepatic function and in pregnancy. Furthermore, the use of methotrexate has been linked to hepatic, pulmonary and bone marrow toxicity, as well as teratogenicity (19). Whilst some of the more recent biologics, such as infliximab, have no reported contraindications for liver disease, renal disease or pregnancy, there has been increased concern over the risk of malignant conditions such as lymphoma, leukaemia and melanoma (21, 22).

In our patient, long-term nail psoriasis was unresponsive to traditional first-line therapies. However, the patient demonstrated significant resolution of his psoriasis nails following 4 months of treatment with the Dr Michaels<sup>®</sup> (Soratinex<sup>®</sup> and Nailinex<sup>®</sup>) product family.

Our case study highlights that the Dr Michaels<sup>®</sup> (Soratinex<sup>®</sup> and Nailinex<sup>®</sup>) formula is effective at attenuating onycholysis and subungual hyperkeratosis and the key process which arises as a result of hyperproliferation, hyperkeratosis and parakeratosis of the nail bed. Our case study suggests that the mechanism via which the Dr Michaels<sup>®</sup> (Soratinex<sup>®</sup> and Nailinex<sup>®</sup>) treatment improves nail psoriasis is by regulating the proliferation and differentiation of epidermal keratinocytes, permeability of the fungal and microbial cells and restores epidermal barrier function, whilst inhibiting inflammation.

The efficacious results observed in our case

report are supported by those of the Austrian clinical trial study performed by Maier and colleagues, in which they compared the efficacy of Dr Michaels® (Soratinex® and Nailinex®) product family to a placebo group in plaque psoriasis (23), albeit independent of nail involvement. However, this study highlights a potential anti-inflammatory, antimicrobial and antifungal role for the Dr Michaels® (Soratinex® and Nailinex®) product family, which may be applicable to nail psoriasis.

### CONCLUSION

Recently, there has been increasing interest in the area of complementary and herbal medicine for the treatment of psoriatic nails. Due to the refractory nature of nail psoriasis and thus the long-term nature of treatment, a safe and effective natural therapy is appealing. Similarly, a randomised controlled double blind study by Maier and colleagues demonstrated the efficacy of herbal skin care-products [Dr Michaels® (Soratinex® and Nailinex®) skin-care products for psoriasis] for stable chronic plaque psoriasis, albeit in the absence of nail psoriasis. Our case report demonstrated that the use of complementary medicine, such as Dr Michaels® (Soratinex® and Nailinex®) product family, is efficacious in the treatment of not only plaque psoriasis, as illustrated in the Maier study (21), but also in nail psoriasis in a 50-year-old male patient with a 10-year history of nail psoriasis and a 35-year history of plaque psoriasis. Furthermore, this case report highlights that the Dr Michaels® (Soratinex® and Nailinex®) product family is well tolerated even long-term, with no serious adverse events reported.

In conclusion, our case report demonstrates that the Dr Michaels® (Soratinex® and Nailinex®) product family is an effective therapeutic option for the treatment psoriatic nails. Moreover, it highlights the safety profile of the Dr Michaels® (Soratinex® and Nailinex®) product family in the treatment of psoriatic nails. Due to the refractory nature of psoriatic nails, efficacy and safety of long-term treatments are highly important. These data have important implications for resistant cases of psoriatic nails where traditional therapies have failed. In addition, this treatment

approach may be an attractive option for patients who demonstrate contraindications to traditional therapies or have growing concerns regarding side-effects of long-term steroid and systemic therapies.

### ACKNOWLEDGEMENTS

We gratefully acknowledge Tirsell Pty Ltd (Melbourne, Australia) for providing the products for the studies. We gratefully acknowledge the patient for the permission to report his case.

### REFERENCES

1. Van Laborde S, Scher RK. Developments in the treatment of nail psoriasis, melanonychia striata, and onychomycosis. A review of the literature. *Dermatol Clin* 2000; 18(1):37-46.
2. de Jong EM, Seegers BA, Gulinck MK, Boezeman JB, van de Kerkhof PC. Psoriasis of the nails associated with disability in a large number of patients: results of a recent interview with 1,728 patients. *Dermatology* 1996; 193(4):300-303.
3. Klaassen KM, van de Kerkhof PC, Pasch MC. Nail psoriasis: A questionnaire-based survey. *Br J Dermatol* 2013; 169:314-9.
4. Jiaravuthisan MM, Sasseville D, Vender RB, Murphy F, Muhn CY. Psoriasis of the nail: anatomy, pathology, clinical presentation, and a review of the literature on therapy. *J Am Acad Dermatol* 2007; 57(1):1-27.
5. Wollina U, Barta U, Uhlemann C, Oelzner P, Hein G. Nail changes in rheumatic disease. *Hautarzt* 1999; 50(8):549-55.
6. Tan ES, Chong WS, Tey HL. Nail psoriasis: a review. *Am J Clin Dermatol* 2012; 13:375-88.
7. McGonagle D, Benjamin M, Tan AL. The pathogenesis of psoriatic arthritis and associated nail disease: not autoimmune after all? *Curr Opin Rheumatol* 2009; 21(4):340-7.
8. de Jong EM, Seegers BA, Gulinck MK, et al. Psoriasis of the nails associated with disability in a large number of patients: results of a recent interview with 1728 patients. *Dermatology* 1996; 193:300-3.
9. Marks R, Davies M, Cattell A. An explanation for the keratolytic effect of salicylic acid. *J Invest Dermatol* 1975; 64:283.

10. Loden M, Bostrom P, Kneczke M. Distribution and keratolytic effect of salicylic acid and urea in human skin. *Skin Pharmacol* 1995; 8:173-178.
11. Nenoff P, Haustein U-F, Brandt W. Antifungal activity of the essential oil of *Melaleuca alternifolia* (tea tree oil) against pathogenic fungi in vitro. *Skin Pharmacol* 1996; 9:388-94.
12. Hammer KA, Carson CF, Riley TV. Antifungal effects of *Melaleuca alternifolia* (tea tree) oil and its components on *Candida albicans*, *Candida glabrata* and *Saccharomyces cerevisiae*. *J Antimicrob Chemother* 2004; 53(6):1081-5.
13. Scientific Opinion on the substantiation of health claims related to zinc and maintenance of normal skin (ID 293), DNA synthesis and cell division (ID 293), contribution to normal protein synthesis (ID 293, 4293), maintenance of normal serum testosterone concentrations (ID 301), “normal growth” (ID 303), reduction of tiredness and fatigue (ID 304), contribution to normal carbohydrate metabolism (ID 382), maintenance of normal hair (ID 412), maintenance of normal nails (ID 412) and contribution to normal macronutrient metabolism (ID 2890) pursuant to Article 13(1) of Regulation (EC) No 1924/2006 EFSA Panel on Dietetic Products, Nutrition and Allergies (NDA) 2, 3 European Food Safety Authority (EFSA), Parma, Italy. *EFSA Journal* 2010; 8(10):1819.
14. Treewittayapoom C, Singvahanont P, Chanprapaph K, Haneke E. The effect of different pulse durations in the treatment of nail psoriasis with 595-nm pulsed dye laser: a randomized, double-blind, inpatient left-to-right study. *J Am Acad Dermatol* 2012; 66:807-12.
15. Oram Y, Karıncaoğlu Y, Koyuncu E, Kaharaman F. Pulsed dye laser in the treatment of nail psoriasis. *Dermatol Surg* 2010; 36(3):377-81.
16. Schons KR, Knob CF, Murussi N, Beber AA, Neumaier W, and Monticielo OA. Nail psoriasis: a review of the literature *An Bras Dermatol* 2014; 89(2):312-7.
17. Langley RG, Saurat JH, Reich K. Nail Psoriasis Delphi Expert Panel. Recommendations for the treatment of nail psoriasis in patients with moderate to severe psoriasis: a dermatology expert group consensus. *J Eur Acad Dermatol Venereol* 2012; 26:373-81.
18. Nakamura RC, Abreu Ld, Duque-Estrada B, Tamler C, Leverone AP. Comparison of nail lacquer clobetasol efficacy at 0.05%, 1% and 8% in nail psoriasis treatment: prospective, controlled and randomized pilot study. *An Bras Dermatol* 2012; 87(2):203-11.
19. Wollina U, Ständer K, Barta U. Toxicity of methotrexate treatment in psoriasis and psoriatic arthritis - short- and long-term toxicity in 104 patients. *Clin Rheumatol* 2001; 20(6):406-10.
20. Dogra A, Arora AK. Nail psoriasis: the journey so far. *Indian J Dermatol* 2014; 59(4):319-33.
21. Fabroni C, Gori A, Troiano M, Prignano F, Lotti T. Infliximab efficacy in nail psoriasis. A retrospective study in 48 patients. *J Eur Acad Dermatol Venereol* 2011; 25(5):549-53.
22. Marchesoni A, Altomare G, Matucci-Cerinic M, et al. An Italian shared dermatological and rheumatological proposal for the use of biological agents in psoriatic disease. *J Eur Acad Dermatol Venereol* 2010; 24(5):578-86.
23. Maier H. et al. Prospective randomized controlled double-blind study on the efficacy and safety of a series of herbal skin-care products for stable chronic plaque psoriasis. *JEADV (Journal of the European Academy of Dermatology and Venereology)*, Volume 18. Number 6. November 2004; P061.

## CLINICAL EVALUATION OF THE EFFECTIVENESS OF “DR MICHAELS®” (ALSO BRANDED AS SORATINEX®) PRODUCTS IN THE TOPICAL TREATMENT OF PATIENTS WITH PLAQUE PSORIASIS

M. FIORANELLI<sup>1</sup>, J. HERCOGOVÁ<sup>2,3</sup>, S. GIANFALDONI<sup>4</sup>, A.A.CHOKOEVA<sup>5,6</sup>,  
G. TCHERNEV<sup>7</sup>, U. WOLLINA<sup>8</sup>, M TIRANT<sup>9</sup>, F. NOVOTNY<sup>10</sup>, M.G. ROCCIA<sup>11</sup>,  
G.K. MAXIMOV<sup>12</sup>, K. FRANÇA<sup>13,14</sup> and T. LOTTI<sup>15</sup>

<sup>1</sup>Department of Nuclear Physics, Sub-nuclear and Radiation, Guglielmo Marconi University, Rome, Italy; <sup>2</sup>2nd Medical Faculty, Charles University, Bulovka Hospital, Prague, Czech Republic; <sup>3</sup>Institute of Clinical and Experimental Medicine, Prague, Czech Republic; <sup>4</sup>Dermatological Department University of Pisa, Pisa, Italy; <sup>5</sup>“Onkoderma”- Policlinic for dermatology and dermatologic surgery, Sofia, Bulgaria; <sup>6</sup>Department of Dermatology and Venereology, Medical University of Plovdiv, Medical faculty, Plovdiv, Bulgaria; <sup>7</sup>Medical Institute of Ministry of Interior (MVR), Department of Dermatology, Venereology and Dermatologic Surgery, Sofia, Bulgaria; <sup>8</sup>Department of Dermatology and Allergology, Academic Teaching Hospital Dresden-Friedrichstadt, Dresden, Germany; <sup>9</sup>Psoriasis & Skin Clinic, Melbourne, Australia; <sup>10</sup>PRO SANUM Ltd, Sanatorium of Prof. Novotný, Štěpánská Prague 1, Czech Republic; <sup>11</sup>University B.I.S. Group of Institutions, Punjab Technical University, Punjab, India; <sup>12</sup>Department “Medicinal Information and Non-interventional studies”, Bulgarian Drug Agency, Sofia, Bulgaria; <sup>13</sup>Department of Dermatology & Cutaneous Surgery, Department of Psychiatry & Behavioral Sciences, Institute for Bioethics & Health Policy, University of Miami, Miller School of Medicine, Miami, FL, USA; <sup>14</sup>Centro Studi per la Ricerca Multidisciplinare e Rigenerativa, Università Degli Studi “G. Marconi”, Rome, Italy; <sup>15</sup>Chair of Dermatology, University of Rome “G. Marconi” Rome, Italy

Psoriasis is generally considered as an autoimmune inflammatory cutaneous-systemic disease, with chronic course and high rate of recurrence, while its high risk of comorbidities affect the patients' quality of life significantly. Despite the good therapeutic response, most of the available options show tendency for poor tolerance and high rate of occurrence of side effects. Therefore, the interest of patients and doctors to investigate the possibility of treating psoriasis with natural substances is not surprising. The aim of this study was to investigate the efficacy and safety of the herbal skin-care product Dr Michaels® (Soratinex®) for the management of chronic plaque psoriasis, within a 6 to 8 week treatment course. Thirty patients of both sexes, aged between 24 and 70 years with mild to moderate psoriasis vulgaris were included in this study. The products of Dr Michaels® (Soratinex®) were applied in sequence: cleansing gel, ointment after 3-4 minutes and tonic care (for the fire-smear ointment) 2 times per day for restorative care and cleansing gel for psoriasis within scalp 3 times a week. The study lasted six weeks. The severity and extent of the lesions were evaluated by PASI score (Psoriasis Area and Severity Index). Based on the obtained result, the products of “Dr Michaels® (Soratinex®)” have proved to be effective in the treatment of mild and moderate psoriasis vulgaris. In the study group, no improvement was observed in 10% of patients, a slight improvement in 20%, good in 40% and very good in 16.6% of patients.

Psoriasis is a chronic relapsing autoimmune inflammatory disease of the skin, which is characterized by excessive proliferation and abnormal differentiation of keratinocytes,

*Key words: psoriasis, topical products, herbal products, psoriasis area and severity index, plaque psoriasis, efficacy, safety, patient satisfaction*

Mailing address:  
Professor Torello Lotti  
Department of Dermatology,  
University of Rome “G. Marconi”,  
Rome, Italy  
e-mail: professor@torelloLotti.it

accumulation and the activation of T cells and other inflammatory cells in the psoriatic fire. (1, 2, 3) Psoriasis is the result of genetic factors, predisposing and precipitating factors (e.g. mechanical trauma, drugs, infections, stress) (4, 5). Psychosomatic stressful events play an important role in psoriasis. They may induce or worsen the disease. (6, 7) The lesions are reddish patches covered with silvery scales and the size of the lesions ranges from very small (guttate psoriasis) to extensive lesions that can involve almost the entire surface of the skin (psoriatic erythroderma) (5). The most common form is plaque psoriasis characterized by localized lesions on the extensor surfaces of the upper and lower limbs, in the lumbosacral, on the trunk and in the scalp (8, 9). Topical treatment of plaque psoriasis is intended to remove the scales and to remove inflammation (8). The recommended formulations are salicylic acid, dithranol, tar, vitamin D analogues and corticosteroids (9, 10, 11). Although corticosteroids have beneficial antipsoriatic effect, due to their poor tolerance as well as the possible occurrence of side effect, they should not be used for a long period (9, 10, 11). Therefore, it is not surprising that there is an interest on behalf of both patients and doctors to investigate the possibility of treating psoriasis with natural substances.

The aim of this study was to investigate the

efficacy and safety of the herbal skin-care product Dr Michaels® (Soratinex®) for psoriasis and the management of chronic plaque psoriasis, within a 6 to 8 week treatment course.

## MATERIALS AND METHODS

We evaluated the ability to treat psoriasis with “Dr Michaels® (Soratinex®)”. The study was conducted at the Department of Dermatology and Pediatric Dermatology, Medical University of Lodz, from August 2003 to April 2004.

The study included 30 patients of both sexes, aged between 24 and 70 years of age with mild to moderate psoriasis vulgaris. Patients joined the study after informed consent. The exclusion criteria were the following:

1. Pregnancy and lactation
2. No systemic anti-psoriatic treatment in the 3 months preceding the survey
3. Hypersensitivity to the preparation ingredients (resulting from medical history)
4. Pustular psoriasis and psoriatic erythroderma

The severity and extent of the lesions were evaluated by PASI score (Psoriasis Area and Severity Index) (Table I) (12).

Two weeks before applying the product, patients had ceased all topical treatments and used emollients only. The products of Dr Michaels® (Soratinex®) were

**Table I:** PASI assessment.

Score	0	1	2	3	4		
Erythema	0 = none	1 = mild	2 = moderate	3 = severe	4 = very severe		
Infiltration	0 = none	1 = mild	2 = moderate	3 = severe	4 = very severe		
Parakeratosis	0 = none	1 = mild	2 = moderate	3 = severe	4 = very severe		
Score	0	1	2	3	4	5	6
Area %	0	>10	10<30	30<50	50<70	70<90	90<100



applied in sequence: cleansing gel, ointment after 3-4 minutes and tonic care (for the fire-smearred ointment) 2 times a day or for restorative care and cleansing gel for

psoriasis within scalp 3 times a week. The characteristics of the products including effects, application and active ingredients are presented in Table II. The study lasted six

**Table II.** Characteristics of the Tested Products Dr Michaels® (Soratinex®).

PRODUCT	EFFECT	APPLICATION	ACTIVE INGREDIENTS
Dr Michaels® (Soratinex®) Scalp and Body Cleansing Gel	Decreases parakeratosis	Applied before the use of the ointment <ul style="list-style-type: none"> <li>Scalp: Wet scalp and apply a small amount of cleansing gel.</li> <li>Massage thoroughly and leave for 2-3 minutes. Wash off with lukewarm water.</li> <li>Body: Wet body and apply small amount of cleansing gel to the psoriatic plaques. Leave for 2-3 minutes then rinse off with lukewarm water.</li> </ul>	<ul style="list-style-type: none"> <li>Salicylic acid</li> <li>Citric acid</li> <li>Glycolic acid</li> </ul>
<b>Dr Michaels® (Soratinex®) Scalp and Body Ointment</b>	Decreases inflammation and infiltration	Applied to the psoriatic plaques of the scalp and body after using and washing off the cleansing gel.	<ul style="list-style-type: none"> <li>Paraffinum liquidum</li> <li>Paraffinum solidum</li> <li>Solanum tuberosum</li> <li>Zinc oxide</li> <li>Salicylic acid</li> <li>Prunus amygdalus dulcis oil</li> <li>Simmondsia chinensis oil</li> <li>Persea gratissima oil</li> <li>Daucus carota oil</li> <li>Calendula officinalis extract</li> <li>Citrus sinensis oil</li> <li>Triticum vulgare germ oil</li> <li>Prunus armeniaca kernel oil</li> <li>Lavendula augustifolia</li> <li>Santalum album oil</li> <li>Pogostemon cablin oil</li> <li>Pelargonium graveolens</li> <li>Rosemary officinalis extract</li> <li>Dromiceius oil</li> <li>Citrus aurantium SSP bergamia oil</li> <li>Pinus sylvestris leaf oil</li> <li>Chamomilla recutita oil</li> <li>Commiphora myrrha oil</li> <li>Citrus aurantium amara flower oil</li> </ul>
Dr Michaels® (Soratinex®) Skin Conditioner	Improves flexibility and elasticity of the skin	Applied to the psoriatic plaques two minutes after using the ointment (without washing it off)	<ul style="list-style-type: none"> <li>Olive oil,</li> <li>Sesame seed oil</li> <li>Emu oil</li> <li>Lavender oil</li> <li>Eucalyptus oil</li> <li>Natural vitamin E</li> </ul>

weeks. Preparation was not applied to the face, skin folds and the genital area.

The study group was observed after 1, 2, 3, 4, 5 and 6 weeks of treatment and the total time of observation was 8 weeks. Effectiveness evaluation was performed by a doctor, based on PASI assessment criteria:

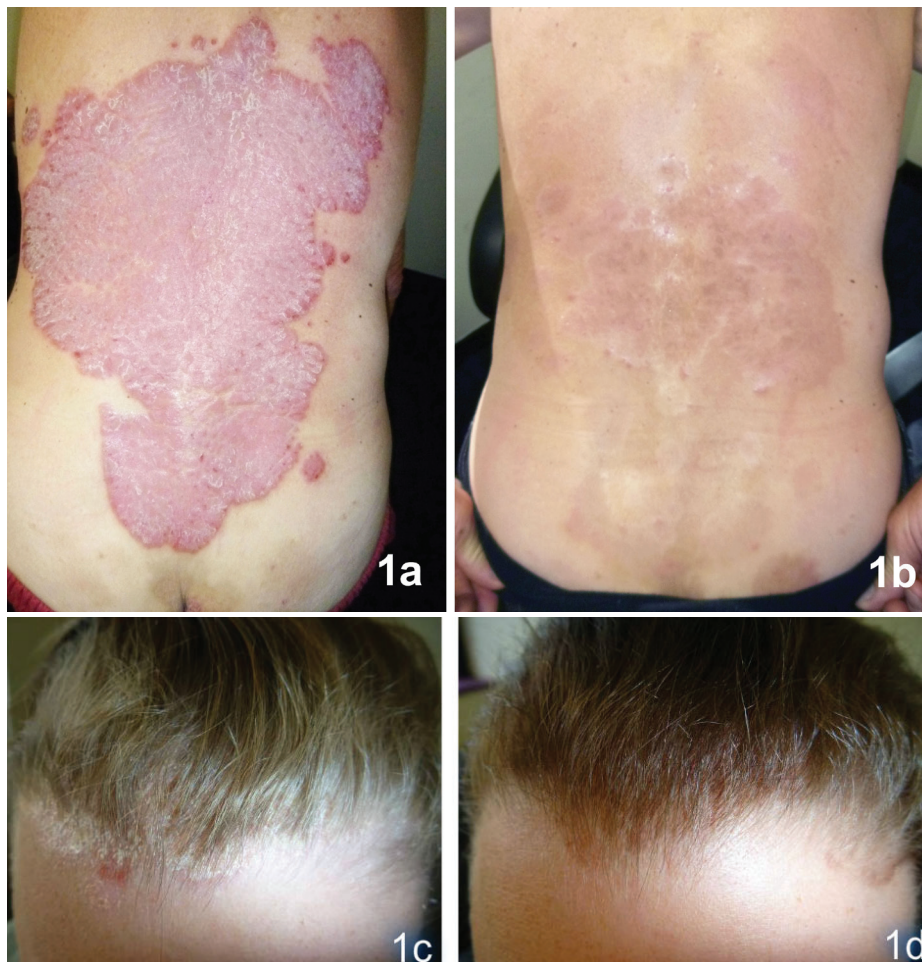
- Inefficiency - a decrease of about 0-25% PASI
- Slight improvement - reduction of PASI about 26-50%
- Good therapeutic effect - a decrease of about 51-75% PASI
- Excellent effect - a reduction in the PASI about 76-100%
- Deterioration - value ratio above baseline PASI.

## RESULTS

Twenty-six patients out of 30 have used cleansing gel, ointment and care tonic for lesions on the skin. Four patients applied the gel cleanser and tonic due to an outbreak of psoriasis on the scalp. Three patients developed a mild skin inflammation and folliculitis, so they stopped treatment.

Of the remaining patients, 3 had no clinical improvements, 6 patients showed a slight improvement, a good response was seen in 9, and 5 achieved an excellent improvement.

Seven patients complained of mild and transient itching spontaneously without accompanying



**Fig. 1.** Clinical manifestation before and after treatment. **a)** 60-year-old, with psoriasis vulgaris on the trunk before treatment; **b)** after 6 weeks of treatment with Doctor Michael's products; **c)** 27-year-old man, affected by scalp psoriasis; **d)** after 2 weeks of treatment.

redness of the skin. Treatment was continued. Only one patient with scalp psoriasis discontinued treatment because of folliculitis-like inflammation.

### DISCUSSION

This open trial evaluated the efficacy and safety of a topical herbal-based remedy treatment for mild to moderate psoriasis. The potential risks of topical corticosteroids and other topical agents could be avoided. Patient adherence to the formulations was successful. Some patients reported mild itching without redness, but this has not caused cessation of therapy. A limitation of this study was the relatively small sample size.

The development of an efficient and safe self-treatment for patients, which targets scaling, redness

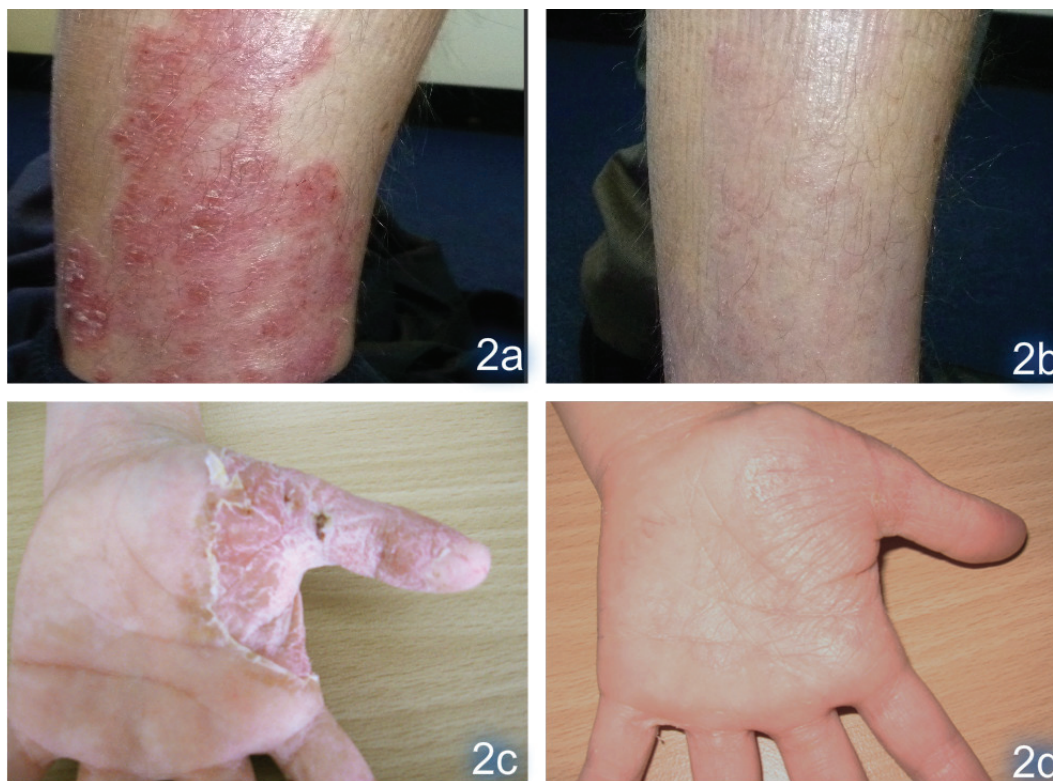and pruritus is necessary to better assist patients with mild-to-moderate psoriasis and improve their quality of life.

### CONCLUSION

The treatment of psoriasis is a difficult process, which must take into account factors such as age, location and extent of lesions, the endogenous factors and tendency for recurrence, as well as the individual skin sensitivity.

The result of this study indicate that “Dr Michaels® (Soratinex®)” cleansing gel, ointment and restorative care, affect the normalization of the process of keratinization in the epidermis and reduce the skin inflammation.

“Dr Michaels® (Soratinex®)” products have proved to be effective in the treatment of mild and



**Fig. 2.** Clinical manifestation before and after treatment. **a)** 54-year-old patient, with chronic plaques of psoriasis on the legs; **b)** complete remission after 5 weeks of treatment. **c)** 38-year-old female patient, with psoriasis of the hand, **d)** the same woman after 3 weeks of treatment.

moderate psoriasis vulgaris. In the study group, improvement was rated good or excellent in 56.6% of the patients.

#### ACKNOWLEDGEMENTS

We gratefully acknowledge Tirsell Pty Ltd (Melbourne, Australia) and Frankl Pharma Global Ltd. (2 Parklands Place, Guilford, Surrey, United Kingdom) for providing the products for the studies.

#### REFERENCES:

1. Scarpa R, Altomare G, Marchesoni A, et al. Psoriatic disease: concepts and implications. *J Eur Acad Dermatol Venereol* 2010; 24(6):627-30.
2. Prignano F, Ruffo G, Ricceri F, Pescitelli L, Lotti T. A global approach to psoriatic patients through PASI score and Skindex-29. *G Ital Dermatol Venereol* 2011; 146(1):47-52.
3. Lotti T, D'Erme AM, Hercogová J. The role of neuropeptides in the control of regional immunity. *Clin Dermatol*.2014; 32(5):633-45.
4. Lotti T, Hercogova J, Prignano F. The concept of psoriatic disease: can cutaneous psoriasis any longer be separated by the systemic comorbidities? *Dermatol Ther* 2010; 23(2):119-22.
5. Machado-Pinto J, Diniz Mdos S, Bavoso NC. Psoriasis: new comorbidities. *An Bras Dermatol* 2016; 91(1):8-14.
6. Campolmi E, Zanieri F, Santosuosso U, D'Erme AM, Betti S, Lotti T, Cossidente A. The importance of stressful family events in psoriatic patients: a retrospective study. *J Eur Acad Dermatol Venereol* 2012; 26(10):1236-9.
7. França K, Chacon A, Ledon J, Savas J, Nouri K. Psychodermatology: a trip through history . *Anais Brasileiros de Dermatologia* 2013; 88(5):842-3.
8. Kin KC, Hill D, Feldman SR. Calcipotriene and betamethasone dipropionate for the topical treatment of plaque psoriasis. *Expert Rev Clin Pharmacol* 2016; 19.
9. Panconesi E, Lotti T. Steroids versus nonsteroids in the treatment of cutaneous inflammation: therapeutic modalities for office use. *Arch Dermatol Res* 1992; 284 (S1):37-41.
10. Jurado-Santa Cruz F, Pérez-Agraz F. From evidence to expertise: concordance in the topical management of psoriasis. *Rev Med Inst Mex Seguro Soc* 2016; 54(3):304-1
11. Wu JJ, Lynde CW, Kleyn CE, Iversen L, van der Walt JM, Carvalho A, Kirby B, Bissonnette R. Identification of key research needs for topical therapy treatment of psoriasis - a consensus paper by the International Psoriasis Council. *J Eur Acad Dermatol Venereol* 2016; 30(7):1115-9.
12. Fredriksson T, Pettersson U. Severe psoriasis - oral therapy with a new retinoid. *Dermatologica* 1978; 157(4):238-44.

## SUCCESSFUL TREATMENT OF A CHRONIC ECZEMA IN A 48-YEAR-OLD FEMALE WITH DR MICHAELS® (ECZITINEX® AND ITCHINEX®) PRODUCT FAMILY. A CASE REPORT

M. TIRANT<sup>1</sup>, P. ANDERSON<sup>1</sup>, P. BAYER<sup>1</sup>, J. HERCOGOVÁ<sup>2,3</sup>, M. FIORANELLI<sup>4</sup>,  
S. GIANFALDONI<sup>5</sup>, A.A. CHOKOEVA<sup>6,7</sup>, G. TCHERNEV<sup>8</sup>, U. WOLLINA<sup>9</sup>,  
F. NOVOTNY<sup>10</sup>, M.G. ROCCIA<sup>11</sup>, G.K. MAXIMOV<sup>12</sup>, K. FRANÇA<sup>13,14</sup> and T. LOTTI<sup>15</sup>

<sup>1</sup>Psoriasis & Skin Clinic, Melbourne, Australia; <sup>2</sup>2nd Medical Faculty, Charles University, Bulovka Hospital, <sup>3</sup>Institute of Clinical and Experimental Medicine, Prague, Czech Republic; <sup>4</sup>Department of Nuclear Physics, Sub-nuclear and Radiation, G. Marconi University, Rome, Italy; <sup>5</sup>Dermatological Department University of Pisa, Pisa, Italy; <sup>6</sup>"Onkoderma"-Policlinic for dermatology and dermatologic surgery, Sofia, Bulgaria; <sup>7</sup>Department of Dermatology and Venereology, Medical University of Plovdiv, Medical faculty, Plovdiv, Bulgaria; <sup>8</sup>Medical Institute of Ministry of Interior (MVR), Department of Dermatology, Venereology and Dermatologic Surgery, Sofia, Bulgaria; <sup>9</sup>Department of Dermatology and Allergology, Academic Teaching Hospital Dresden-Friedrichstadt, Dresden, Germany; <sup>10</sup>PRO SANUM Ltd, Sanatorium of Prof. Novotný, Štěpánská Prague 1, Czech Republic; <sup>11</sup>University B.I.S. Group of Institutions, Punjab Technical University, Punjab, India; <sup>12</sup>Department "Medicinal Information and Non-interventional studies", Bulgarian Drug Agency, Sofia, Bulgaria; <sup>13</sup>Department of Dermatology & Cutaneous Surgery, Department of Psychiatry & Behavioral Sciences, Institute for Bioethics & Health Policy, University of Miami, Miller School of Medicine, Miami, FL, USA; <sup>14</sup>Centro Studi per la Ricerca Multidisciplinare e Rigenerativa, Università Degli Studi "G. Marconi", Rome, Italy; <sup>15</sup>Chair of Dermatology, University of Rome "G. Marconi" Rome, Italy

We report the case of a 48-year-old female with chronic atopic eczema who responded successfully to Dr Michaels® (Eczitinex® and Itchinex®) product family. The patient had a 41-year history of atopic eczema and presented with erythematous, excoriated lesions with telangiectasia and scattered purpura (bruising) covering 90% of her body surface area. The patient also regularly suffered blepharitis with red, itchy, watery eyes. The patient was treated with Dr Michaels® (Eczitinex® and Itchinex®) ointment and herbal supplements and presented total resolution of the atopic eczema and underlying inflammation within 6 weeks. This case also suggests that Dr Michaels® (Eczitinex® and Itchinex®) product family is safe and effective, even in cortisone acquired sensitive skin.

Atopic eczema, also known as atopic dermatitis (AD) is a common chronic relapsing inflammatory skin disorder, characterized clinically by intensely pruritic eczematous skin lesions and a defective epidermal barrier (1). Currently, it is estimated that up to a fifth of the population in developed countries are affected by AD (2). This disease is often associated with both a compromised skin barrier function and a defect in the innate immunity of the skin (3). With

this predisposition, AD patients commonly develop allergic diseases, including asthma, food allergies and rhinitis (3).

In AD, defects in epidermal barrier function are known to contribute greatly to triggering and exacerbating inflammation of the skin. This is observed in patients who constantly scratch the skin and subsequently the resultant erythematous, scaly, cracked skin has increased potential for developing

*Key words: chronic atopic eczema, pruritus, topical products, herbal products, quality of life, effectiveness, patient satisfaction*

Mailing address:

Professor Torello Lotti,  
Department of Dermatology,  
University of Rome "G. Marconi",  
Rome, Italy  
e-mail: professor@torelloLotti.it

0393-974X (2016)

Copyright © by BIOLIFE, s.a.s.

This publication and/or article is for individual use only and may not be further reproduced without written permission from the copyright holder.

Unauthorized reproduction may result in financial and other penalties  
**DISCLOSURE: ALL AUTHORS REPORT NO CONFLICTS OF INTEREST RELEVANT TO THIS ARTICLE.**

secondary infection (4). In addition to this, the skin of patients with AD demonstrates increased transepidermal water loss, and a defect in terminal keratinocyte differentiation that leads to reduced levels of ceramides, filaggrin and antimicrobial peptides.

In regards to immune system defects, AD patients often demonstrate an increase in protease activity and pro-inflammatory cytokine release. These mediators are released, in part, because of the increased endogenous keratinocyte and mast cell derived proteases that are present in atopic skin. In addition, mediators are also released from exogenous proteases derived from environmental allergens, such as dust mites or *Staphylococcus aureus*. Taken together, these factors potentiate the degree of inflammation in the skin of AD patients.

Clinically, the presentation of AD has a wide spectrum ranging from minor forms of AD such as hand eczema through to major forms with erythrodermic rash. The acute and subacute forms are often seen in children and are characterized by intensely pruritic erythematous papules with excoriation and serous exudate, whilst chronic atopic dermatitis is characterised by lichenification, papules and excoriations (2). The intense pruritus experienced by AD patients is responsible for the scratching, which results in lichenification and prurigo papules. Other known triggers that exacerbate pruritus and subsequently cause scratching include allergens, reduced humidity, excessive sweating and low concentrations of irritants (5).

The localisation of AD varies depending on age and disease severity, although it is generally associated with affecting the extensor surfaces. In infancy, AD usually affects the face, scalp and extensor surfaces of the extremities. Whilst in older children, AD generally affects the flexural folds of the extremities (5). In adults, AD may demonstrate localised through to diffuse/generalised patterns and is associated with increased xerosis and lichenification.

The pathogenesis of AD appears to be multifactorial, involving skin barrier defects most likely associated with increased interleukin (IL)-4 and IL-13 expression (6) and reduced filaggrin.

In addition, innate immunity involving Toll-like receptors (TLRs), IL-33, IL-25 and innate lymphoid cells are also suggested to play a role in the pathogenesis of AD (6), where a defect in these microbial sensing receptors was shown to increase the risk of developing AD (7, 8, 9). Histologically, AD is characterised by spongiosis or intercellular oedema, fluid accumulation within intra-epidermal vesicles and infiltration of lymphocytes. Whilst dermal changes include oedema, to varying degrees and a superficial perivascular infiltrate with lymphocytes, histiocytes and occasional neutrophils and eosinophils (10).

The main goal of therapy for atopic dermatitis is to restore the function of the epidermal barrier and to reduce skin inflammation (11). Traditional/conventional topical treatment options for atopic dermatitis include over the counter skin emollients, topical corticosteroids, calcineurin inhibitors and phototherapy. Whilst systemic medications include methotrexate, cyclosporine, corticosteroids, azathioprine, interferon- $\gamma$  and mycophenolate mofetil (12).

Although topical corticosteroids are widely prescribed for AD, they are associated with various short- and long-term side effects. Because topical corticosteroids are absorbed through the skin, they can be associated with systemic side effects, particularly in infants and the elderly where the skin is much thinner and thus absorption is increased (13). The systemic-associated side effects include hypothalamic-pituitary-adrenal axis suppression, Cushing's disease and femoral head osteonecrosis, whilst the cutaneous adverse effects include tinea, skin atrophy, striae distensae and contact dermatitis.

The most commonly referred to side effect of topical corticosteroid use is the corticosteroid-induced flare-up following discontinuation of corticosteroids. This was illustrated in a cross sectional survey of 918 AD patients by Takahashi-Ando and colleagues. That study found that 63.9% of AD patients experienced a flare-up following discontinuation of their topical corticosteroid (14). Furthermore, the degree of flare-up observed significantly correlated with the strength of the topical corticosteroid (14). Thus, caution must be

taken when patients are prescribed corticosteroids, particularly when there is increased transcutaneous penetration in certain areas of the body with thin epidermis, such as the eyelids, periorbital area, axillae, crural region and genitalia (15) in the young and elderly.

In addition, systemic corticosteroids are also often prescribed for atopic dermatitis, despite them not being officially approved for their use in AD (12). Although systemic corticosteroids are an effective immunosuppressive option for severe AD, their associated side effects limit their long-term use.

The need for new and effective treatment option for atopic dermatitis with a limited side-effect profile is warranted, particularly for patients who have recalcitrant forms of AD and are hesitant to embark on a long-term relationship with corticosteroids. In addition, infants and the elderly AD sufferers would benefit from a safe and effective treatment option for AD which does not pose serious side-effects as those described with long-term corticosteroids use.

#### *Case report*

We report a case of a 48-year-old female who presented chronic AD since the age of 7. There was no family history of asthma, hay fever or AD. The patient, as an infant and young child, had no significant illnesses and did not suffer from asthma or hayfever.

Diagnosed with AD by a dermatologist at the age of approximately 7, she had been prescribed with corticosteroid cream (Betnovate, Betamethasone Valerate 0.1% w/w and Clioquinol 3% w/w applied twice daily). By the age of 13, the patient was applying the cortisone cream constantly. This treatment resolved most of the symptoms of AD and the patient was able to function as a normal teenager. She did however suffer flare-ups on a regular basis. During her 20s, due to her growing concern and dermatologist warnings about the over-use of cortisone and its potential side effects, the patient tried naturopathic treatments and underwent allergy “scratch” tests, the results of which indicated a severe over-sensitivity to almost everything she was tested for.

By the time the patient was in her late 20s, she

was constantly itching and lived with chronic severe pruritus. The patient made the statement that her scratching was completely self-conscious at that point. Her skin was noticeably dry and her lips constantly flaking and peeling. Working as a flight attendant, the dehydrating work atmosphere aggravated her condition. Her hands were permanently and prematurely wrinkled, with lichenification of fingers and wrists. She was under a lot of stress and was in constant physical discomfort.

At the age of 29, she suffered a serious flare up due to an episode of severe sunburn of the face whilst skiing. Her face swelled significantly and affected her eyes, which were severely bloodshot, swollen and almost completely closed. The treatment for this was a course of systemic corticosteroids, prednisolone tablets, 25 mg twice daily. After this episode, the patient was photosensitized and any sun exposure caused a similar flare up.

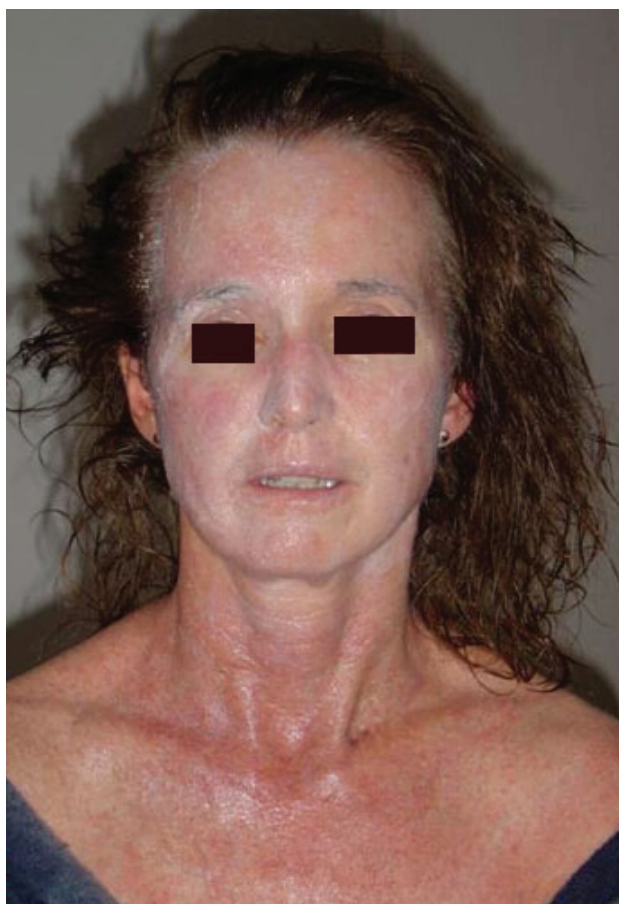Whilst in her 30s the patient had to avoid any sun exposure and she had to cover-up completely and apply high spectrum sunscreens. Frequent flare ups of her AD, due to her other environmental sensitivities were common place and her dermatologist was supplying her with a “bulk” prescription for corticosteroid (mometasone furoate), elecon 1mg/g and again even though warned against overuse, the patient was applying this cream several times a day and especially to her face. She was doing this in order to maintain her looks so that she could continue to work. The patient stated that she could not afford any potential long periods of sick leave and did not want to lose her employment.

At age 39, after a particularly bad flare up that caused intensive pruritus and scratching, her arm came up with a deep red “welt”. She consulted with her dermatologist immediately and was advised that she had thinning of the skin, arteries and veins, but stopped short of stating that this was due to corticosteroid-induced dermal atrophy. The patient indicated that her skin always had a “thin” dry papery look and upon undressing, a sprinkle of fine skin scales would be evident on her clothes.

In her early 40s, the patient reduced her employment to part-time status. However, she was now involved in home renovations and the

subsequent exposure to chemicals and toxic dust caused several severe flare-ups. She stated that she was “sleeping in a coating” of corticosteroid cream without significant relief. The patient was also using systemic corticosteroid (prednisolone tablets), 25 mg twice daily, in order to control the flare ups and ease her symptoms. At the age of 46, she suffered a shock after going horse riding and upon undressing finding her inner calves, buttocks and shins covered in a deep purple “bruising”.

This scare caused her to take 2 months off work, removing herself from both systemic and topical corticosteroids and to follow a restrictive diet. As this had been the first time in 30 years that she had not used some form of corticosteroid, either topically or systemically, she immediately suffered a whole body



**Fig. 1.** Before treatment with the Dr. Michaels® product family, the patient demonstrated AD on the face, upper chest and cervicis/neck regions. Severe xerosis, flaking and excoriations are evident. Overall facial pallor is evident with discrete ill-defined areas of erythema.

withdrawal flare up. Her whole body had “exploded” into a fiery, erythematous and intensely pruritic state that worsened day by day. Upon attending the Emergency Department, they prescribed yet another dose of prednisolone for her (100 mg per day for 10 days, reducing to 50 mg for 5 days, 25 mg for a further 5 days and 10 mg for 5 days, as well as continual twice-daily applications of Elocon cream. Whilst this did control the inflammation and AD, the continued application of the corticosteroid caused greater fragility of the patient’s skin and her condition became more debilitating. Not only did she bruise easily and regularly, but also her skin fissured easily and bled from even the slightest bump.

In desperation, the patient attempted again to undergo corticosteroid withdrawal under the guidance of a dermatologist. Again, the patient suffered from corticosteroid withdrawal and 90% of her body was affected by a red burning rash, accompanied again by an intense pruritus. After several days, the patient’s skin peeled off in layers and resolved, only to re-flare and the process to repeat. The cycle repeated itself several times with increasing intensity.

It was at that time that the patient presented for her initial consultation at our clinic. Examination revealed diffuse erythema covering 90% of her body. Excoriations, telangiectasia and scattered bruising could be seen. The patient was also suffering blepharitis with red, itchy, watery eyes (Fig. 1). She described extremely pruritic, burning and painful lesions. There was extensive usage of corticosteroids, even on the face, which created a whitish mask.

The patient was treated with Dr Michaels® (Eczitinex® and Itchinex®) product family, consisting of an ointment and oral herbal formulations, PSC200 (1 BD) and PSC900 (5ml per day).

The topical ointment is anti-inflammatory and provides barrier repair while restoring skin lipid imbalances. The ointment contains a synergistic blend including zinc oxide, castor oil, emu oil, papaya fruit extract in a petroleum jelly, glycerine base. Zinc is required for collagen and protein synthesis as low levels of zinc are associated with impaired wound healing. Zinc is also required for



cellular growth and replication and may assist in wound healing by reducing free radical activity and inhibiting bacterial growth. Zinc serves as a cofactor in numerous transcription factors and enzyme systems including zinc-dependent matrix metalloproteinases that augment auto-debridement and keratinocyte migration during wound repair. Zinc confers resistance to epithelial apoptosis through stabilizing cellular membranes, and cytoprotection against reactive oxygen species and bacterial toxins through anti-oxidant activity of the cysteine-rich metallothionines and superoxide dismutase (15). The constituents of this carefully blended formula addresses the different factors that contribute to dry skin and restores epidermal differentiation. The essential oils and herbal extracts in topical ointment not only address the different factors that contribute to dry skin but also restore epidermal differentiation by restoring the lipid lamellae, improve skin hydration, skin elasticity and prevent itching.

The PSC 200 (2 tablets/twice daily) contains herbs including dandelion, echinacea, ginseng, licorice and astragalus and is anti-inflammatory, anti-bacterial and immune stimulating. It was prescribed for the symptomatic relief and management of dry skin, and its wound healing and skin renewal properties. It has hepato-protective properties, inhibits prostaglandin synthesis through the inhibition of COX-1 and COX-2 and activates T-Cells and natural killer (NK) cells.

The PSC 900 (2ml/twice daily), a zinc and folic acid based supplement, facilitates the improvement and maintenance of general wellbeing. It also contains pyridoxine hydrochloride (B6) and ferrous gluconate (iron), which are helpful in the symptomatic relief and management of dry, skin and is necessary for the production and maintenance of new cells and DNA and RNA synthesis.

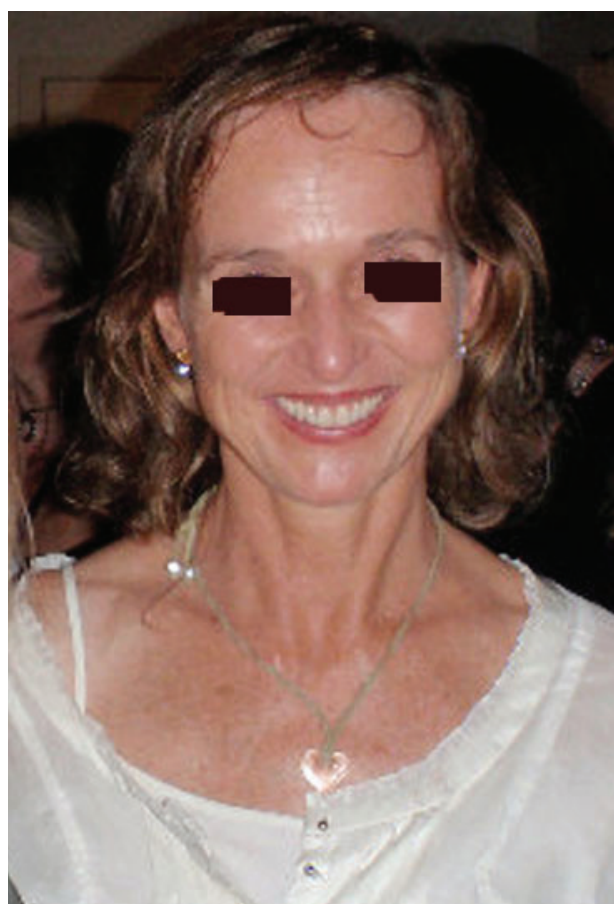## RESULTS

After a 2-week treatment of the Dr Michaels® (Eczitinex® and Itchinex®) topical ointment and herbal supplements, there was a marked improvement in all the dermatology markers, including erythema, oedema, scaling, excoriations, exudate and parakeratosis (photos not available). In addition,

the associated oedema and pruritus had reduced. The patient was happy with the improvements and continued on the treatment protocols.

After 6-weeks of treatment with the Dr Michaels® (Eczitinex® and Itchinex®) and oral product family, the patient demonstrated complete resolution of her AD and was symptom free. On examination, her skin had completely normalized and there was no evidence of xerosis, erythema, edema or excoriations (Fig. 2). Her skin was no longer pruritic and was sleeping a lot better (7-8 h). It was the first time in years that her sleeping pattern had returned to normal. She felt great.

A maintenance program was employed which consisted of continuing with the Dr. Michaels® herbal supplement as required (PSC200 1 tablet



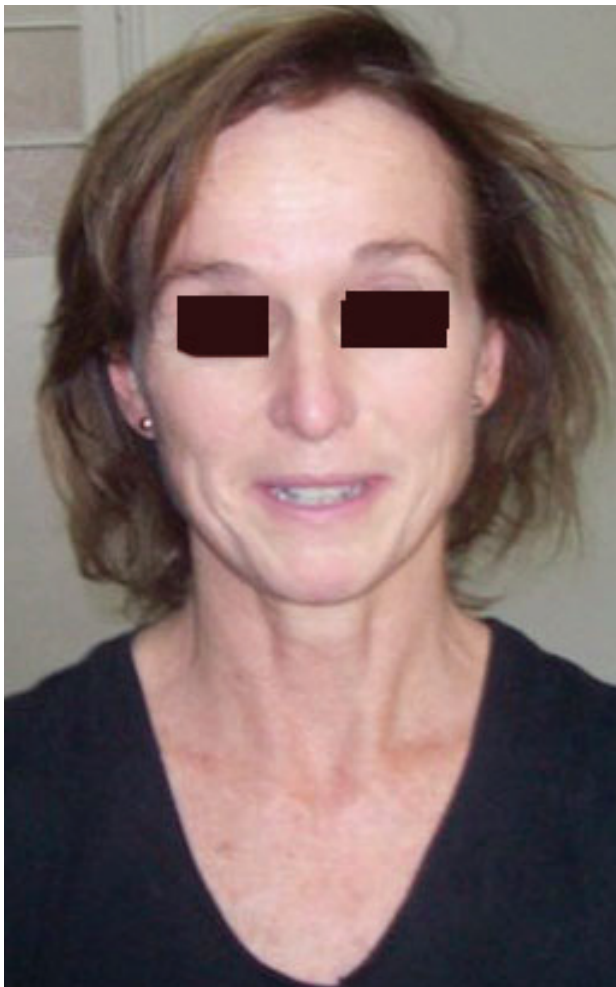**Fig. 2.** Following 6-weeks of treatment with Dr. Michaels® product family, the AD on the face, cervical and neck region have completely resolved. Specifically, erythema and xerosis are no longer observed. The facial pallor has also returned to normal.

daily and PSC900 5ml daily) with application of the Dr Michaels® (EczitineX® and Itchinex®) ointment only in case of xerosis or pruritus. The patient was extremely happy, especially with her improved quality of life and returned to the workforce (airline travel).

Following 2 years on a maintenance program, the patient continues to exhibit a symptom free state and her skin has completely normalized with no signs of lichenification (Fig. 3). She is extremely happy and is now leading a normal life.

### DISCUSSION

AD is a chronic inflammatory cutaneous disease



**Fig. 3.** After 2 years on a maintenance treatment program with the Dr. Michaels® product family, the patient demonstrated complete resolution of her AD.

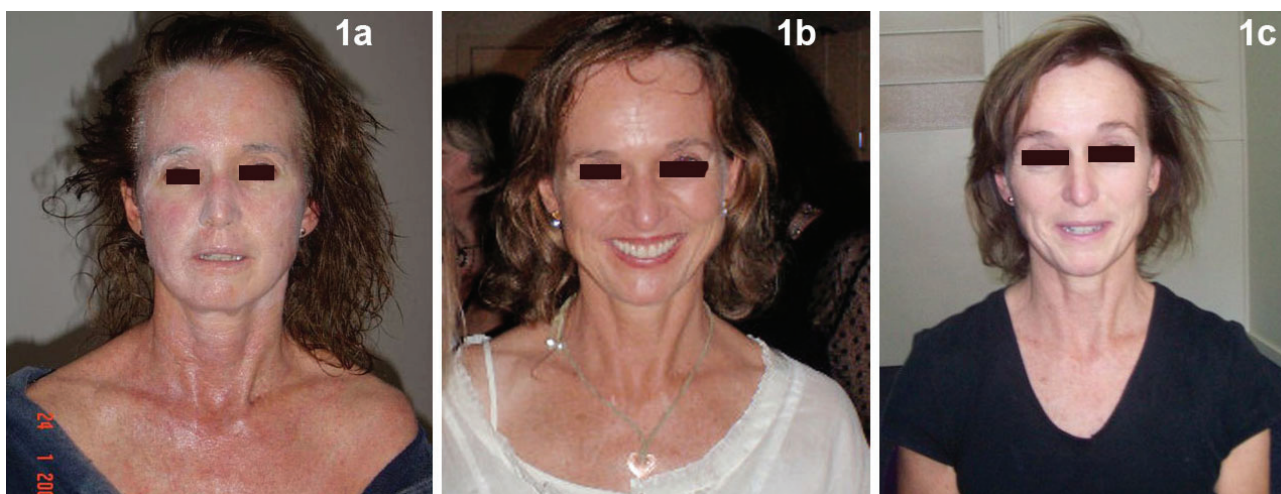and is a part of the triad of atopy including allergic rhinitis and asthma. Most cases of AD generally develop in children under the age of five; however, it may persist into adulthood (16, 17). Apart from allergic mechanisms and cutaneous barrier disruption, dysregulation in the immune system is a key player in this condition. Adult AD is primarily localized to face, wrists and popliteal and antecubital fossae, however, it could present in a widespread manner.

In our patient, long-term AD was unresponsive to traditional first-line therapies. However, the patient demonstrated rapid resolution of her AD and associated pruritus following 6 weeks of treatment with the Dr Michaels® (EczitineX® and Itchinex®) product family. Specifically, the patient was prescribed a topical ointment and oral formulations, PSC 200 and PSC900.

The attenuation in AD observed following Dr Michaels® (EczitineX® and Itchinex®) product family treatment is attributed to the synergistic effect of the topical cream and oral supplements. Specifically, the active ingredients in the topical ointment are a combination of essential oils and zinc oxide. Lastly, the PSC 200 has antibiotic and antifungal properties. Whilst the PSC900 is a zinc based supplement, which assists in the management and symptomatic relief of dry skin. It has been demonstrated that zinc can reduce itchiness and redness in AD patients (15). In haemodialysis-associated pruritus, oral zinc was more effective than placebo for pruritus relief (18, 19).

### CONCLUSION

In conclusion, our case report demonstrates that the Dr Michaels® (EczitineX® and Itchinex®) ointment and oral formulations are an effective therapeutic option for the treatment of recalcitrant AD. Moreover, it highlights the rapid onset (6 weeks) and safety profile of the Dr Michaels® (EczitineX® and Itchinex®) product family in AD compared to traditional first-line treatments. These data have important implications for resistant cases of AD where traditional first- and second- line therapies have failed. In addition, this treatment approach may be an attractive option for patients who have



**Fig. 4.** *a): Before treatment; b): After 6 weeks of treatment; c): after 2 years.*

growing concern regarding the safety profile of long-term corticosteroid or other systemic therapies.

#### ACKNOWLEDGEMENTS

We gratefully acknowledge Tirsell Pty Ltd (Melbourne, Australia) for providing the products for the studies. We gratefully acknowledge the patient for the permission to report her case.

#### REFERENCES

1. Zeppa. L, Bellini V, Lisi P. Atopic dermatitis in adults. *Dermatitis* 2011; 22(1):40-6.
2. Weidinger S, Novak N. Atopic dermatitis. *Lancet* 2016; 387(10023):1109-22.
3. Mrabet-Dahbi S, Maurer M. Innate immunity in atopic dermatitis. *Curr Probl Dermatol* 2011; 41:104-11.
4. Kanchongkittiphon W, Gaffin JM, Phipatanakul W. Child with atopic dermatitis. *Ann Allergy Asthma Immunol* 2015; 114(1):6-11.
5. Leung DY, Bieber T. Atopic dermatitis. *Lancet* 2003; 361(9352):151-60.
6. Ong P. New insights in the pathogenesis of atopic dermatitis. *Pediatric Research* 2014; 75(1-2):171-5.
7. Ahmad-Nejad P, Mrabet-Dahbi S, Breuer K et al. The toll-like receptor 2 R753Q polymorphism defines a subgroup of patients with atopic dermatitis having severe phenotype. *J Allergy Clin Immunol* 2004; 113:565-7.
8. Oh DY, Schumann RR, Hamann L, Neumann K, Worm M, Heine G. Association of the toll-like receptor 2 A-16934T promoter polymorphism with severe atopic dermatitis. *Allergy* 2009; 64(11):1608-15.
9. Niebuhr M, Heratizadeh A, Wichmann K, Satzger I, Werfel T. Intrinsic alterations of pro-inflammatory mediators in unstimulated and TLR-2 stimulated keratinocytes from atopic dermatitis patients. *Exp Dermatol* 2011; 20(6):468-72.
10. Gutte RM. Adult onset atopic dermatitis with secondary follicular mucinosis with cyclosporine induced spiny follicular hyperkeratosis and hair casts. *Indian J Dermatol* 2013; 58(3):243.
11. Chong M, Fonacier L. Treatment of Eczema: Corticosteroids and Beyond. *Clin Rev Allergy Immunol* 2015; [Epub ahead of print].
12. Akhavan A, Rudikoff D. Atopic dermatitis: systemic immunosuppressive therapy. *Semin Cutan Med Surg* 2008; 27(2):151-5.
13. Fisher AD. Adverse effects of topical corticosteroid use. *West J Med* 1995; 162(2):123-6.
14. Takahashi-Ando N, Jones MA, Fujisawa S, Hama R. Patient-reported outcomes after discontinuation of long-term topical corticosteroid treatment for atopic dermatitis: a targeted cross-sectional survey. *Drug Health Patient Saf* 2015; 7:57-62.
15. Wiegand C, Hipler UC, Boldt S, Strehle J, Wollina U. Skin-protective effects of a zinc oxide-functionalized

- textile and its relevance for atopic dermatitis. *Clin Cosmet Investig Dermatol* 2013; 6:115-21.
16. Buggiani G, Ricceri F, Lotti T. Atopic dermatitis. *Dermatol Ther* 2008; 21(2):96-100.
  17. Pallanti S, Lotti T, Urpe M. Psychoneuroimmunodermatology of atopic dermatitis: from empiric data to the evolutionary hypothesis. *Dermatol Clin*. 2005; 23(4):695-701.
  18. Mapar MA, Pazyar N, Siahpoosh A, Latifi SM, Beladi Mousavi SS, Khazanee A. Comparison of the efficacy and safety of zinc sulfate vs. placebo in the treatment of pruritus of hemodialytic patients: a pilot randomized, triple-blind study. *G Ital Dermatol Venereol* 2015; 150(4):351-5.
  19. Najafabadi MM, Faghihi G, Emami A, Monghad M, Moeenzadeh F, Sharif N, Davarpanah Jazi AH. Zinc sulfate for relief of pruritus in patients on maintenance hemodialysis. *Ther Apher Dial* 2012; 16(2):142-5.

## DR MICHAELS® (SORATINEX®) PRODUCT FOR THE TOPICAL TREATMENT OF PSORIASIS: A HUNGARIAN/ CZECH AND SLOVAK STUDY

J. HERCOGOVÁ<sup>1,2</sup>, M. FIORANELLI<sup>3</sup>, S. GIANFALDONI<sup>4</sup>, A.A. CHOKOEVA<sup>5,6</sup>, G. TCHERNEV<sup>7</sup>, U. WOLLINA<sup>8</sup>, M. TIRANT<sup>9</sup>, F. NOVOTNY<sup>10</sup>, M.G. ROCCIA<sup>11</sup>, G.K. MAXIMOV<sup>12</sup>, K. FRANÇA<sup>13,14</sup> and T. LOTTI<sup>15</sup>

<sup>1</sup>2nd Medical Faculty, Charles University, Bulovka Hospital, <sup>2</sup>Institute of Clinical and Experimental Medicine, Prague, Czech Republic; <sup>3</sup>Department of Nuclear Physics, Sub-nuclear and Radiation, G. Marconi University, Rome, Italy; <sup>4</sup>Dermatological Department University of Pisa, Pisa, Italy; <sup>5</sup>"Onkoderma"-Polyclinic for dermatology and dermatologic surgery, Sofia, Bulgaria; <sup>6</sup>Department of Dermatology and Venereology, Medical University of Plovdiv, Medical faculty, Plovdiv, Bulgaria; <sup>7</sup>Medical Institute of Ministry of Interior (MVR), Department of Dermatology, Venereology and Dermatologic Surgery, Sofia, Bulgaria; <sup>8</sup>Department of Dermatology and Allergology, Academic Teaching Hospital Dresden-Friedrichstadt, Dresden, Germany; <sup>9</sup>Psoriasis & Skin Clinic, Melbourne, Australia; <sup>10</sup>PRO SANUM Ltd., Sanatorium of Prof. Novotný, Štěpánská Prague 1, Czech Republic; <sup>11</sup>University B.I.S. Group of Institutions, Punjab Technical University, Punjab, India; <sup>12</sup>Department "Medicinal Information and Non-interventional studies", Bulgarian Drug Agency, Sofia, Bulgaria; <sup>13</sup>Department of Dermatology & Cutaneous Surgery, Department of Psychiatry & Behavioral Sciences, Institute for Bioethics & Health Policy, University of Miami, Miller School of Medicine, Miami, FL, USA; <sup>14</sup>Centro Studi per la Ricerca Multidisciplinare e Rigenerativa, Università Degli Studi "G. Marconi", Rome, Italy; <sup>15</sup>Chair of Dermatology, University of Rome "G. Marconi" Rome, Italy

Psoriasis is a chronic inflammatory T cell-mediated skin disease, affecting about 2% of Hungarian population. Genetic predisposition as well as environmental triggering factors, and innate immune processes play a role in its etiology. Treatment of psoriasis during the initial stages and first years of disease tend to be conservative and frequently based on topical agents. The aim of this study was to investigate and to describe the efficacy and safety of Dr Michaels® (Soratinex®) skin-care products for the topical treatment of stable chronic plaque psoriasis in a Hungarian population. Two-hundred-and-eight-six (120 female/166 male) patients, aged 10-80 years old (mean age 43 years) with mild to moderate plaque psoriasis had participated in the study. The products, including cleansing gel containing a coal tar solution, herbal oils and emulsifiers, were used twice daily and in the same manner for all the skin lesions. The study period was eight weeks. Assessment, using the Psoriasis Activity Severity Index (PASI) scores and photographic analysis, was done 2 weeks before treatment, at time 0, and after 2, 4, 6 and 8 weeks. Patient's improvement was determined by the percentage reduction of the PASI scores. Side effects and tolerability were also evaluated. After 8 weeks treatment course, 46 patients had a moderate improvement, with the regression of 25-50% of skin lesions; 77 patients showed a good improvement, with the resolution of 51-75% of lesions. Another 115 patients had an outstanding improvement, with the regression of 76-98.9% of lesions. Only 13 patients did not achieve an improvement of psoriasis. Fifteen patients experienced folliculitis, which resolved after cessation of treatment. Seven patients worsened and discontinued treatment. Thirteen patients dropped out because of non-compliance. Our investigation demonstrates that Dr Michaels® (Soratinex®) products, an Australian treatment, can be used successfully in the treatment of stable chronic plaque psoriasis.

*Key words: psoriasis, topical products, herbal products, Psoriasis Area and Severity Index, effectiveness, safety*

Mailing address:  
Professor Torello Lotti,  
Department of Dermatology,  
University of Rome "G. Marconi",  
Rome, Italy  
e-mail: professor@torelloLotti.it

Psoriasis is a chronic inflammatory T cell-mediated skin disease, affecting about 2% of Hungarian population (1). Genetic predisposition as well as environmental triggering factors, and innate immune processes play role in its etiology (1, 2, 3, 4). Stressful life events may also trigger the disease (5, 6). This disease also has a profound psychosocial impact on the patient's quality of life (7, 8, 9). Psoriasis can occur at any age without any gender predominance (1) and can affect any region of the body, although more commonly it involves scalp, extensor surfaces of the extremities, skin folds and nails (10). The clinical presentation is variable, characterized by infiltration and parakeratosis (10) and approximately 30% of psoriasis patients are also affected with the psoriatic arthritis (11). Treatment of psoriasis during the initial stages and first years of disease tend to be conservative and frequently based on topical agents (12).

The aim of this study was to investigate and to describe the efficacy and safety of Dr Michaels® (Soratinex®) skin-care products for the topical

treatment of stable chronic plaque psoriasis, in a Hungarian population.

## MATERIALS AND METHODS

After obtaining written consent, 286 (120 female/166 male) patients, aged 10-80 years old (mean age 43), had participated in the study. All the patients had a mild to moderate plaque psoriasis.

Exclusion criteria were pustular and erythrodermic psoriasis, pregnancy, use of any antipsoriatic treatments, any medication which may influence or interfere with the course of the disease, hypersensitivity to any of the components of the products. The products was used twice daily and in the same manner for all the skin lesions.

First, patients had to use a cleansing gel containing a coal tar solution, fruit acid complex and emulsifiers (Table I).

After 5 min, the gel was washed off and lesions were covered with an ointment composed of herbal extracts and essential oils in a petroleum base. After the ointment was absorbed into the plaques, the plaques were then

**Table I.** *Characteristics of the products*

<p><b>Dr Michaels® (Soratinex®) Scalp and Body Cleansing Gel</b> Loose, brown-opaque, easily applicable topical preparation Effect: Decreases parakeratosis Application: Applied before the use of the ointment.</p> <ul style="list-style-type: none"> <li>• Scalp: Wet scalp and apply a small amount of cleansing gel. Massage thoroughly and leave for 2-3 min. Wash off with lukewarm water. (Can be applied to forehead but avoid cheek area)</li> <li>• Body: Wet body and apply small amount of cleansing gel to the psoriatic plaques. Leave for 2-3 min. then rinse off with lukewarm water.</li> </ul> <p>Active ingredients: Salicylic acid, citric and glycolic acid</p>
<p><b>Dr Michaels® (Soratinex®) Scalp and Body Ointment</b> Yellowish-white ointment with characteristic scent. Effect: Decreases inflammation and infiltration. Application: Applied to the psoriatic plaques of the scalp and body after using and washing off the cleansing gel. Ingredients: Paraffinum liquidum, Paraffinum solidum, solanum tuberosum, Zinc oxide, Salicylic acid, Prunus amygdalus dulcis oil, Simmondsia chinensis oil, Persea gratissima oil, Daucus carota oil, Calendula officinalis extract, Citrus sinensis oil, Triticum vulgare germ oil, Prunus armeniaca kernel oil, Lavendula augustifolia, Santalum album oil, Pogostemon cablin oil, Pelargonium graveolens, Rosemary officinalis extract, Dromiceius oil, Citrus aurantium SSP bergamia oil, Pinus sylvestris leaf oil, Chamomilla recutita oil, Commiphora myrrha oil, Citrus aurantium amara flower oil.</p>
<p><b>Dr Michaels® (Soratinex®) Skin Conditioner.</b> White coloured, viscous substance with characteristic scent. Effect: Improves flexibility and elasticity of the skin. Application: Applied to the psoriatic plaques two min after using the ointment (without washing it off). Ingredients: Olive oil, sesame seed oil, emu oil, lavender oil, eucalyptus oil, natural vitamin E.</p>

**Table II:** PASI score.

Score	0	1	2	3	4
Erythema	0=none	1=mild	2=moderate	3=severe	4=very severe
Infiltration	0=none	1=mild	2=moderate	3=severe	4=very severe
Scaling	0=none	1=mild	2=moderate	3=severe	4=very severe

Score	0	1	2	3	4	5	6
Area	0	<10	10<30	30<50	50<70	70<90	90<100

covered with a thin layer of oil.

The study period was 8 weeks. Assessment, using the Psoriasis Activity Severity Index (PASI) scores (Table II) (13) and photograph analysis was done 2 weeks before treatment, at time 0 and after 1, 2, 4, 6 and 8 weeks. Patient improvement was determined by the percentage reduction of the PASI scores. Side effects and tolerability were also evaluated.

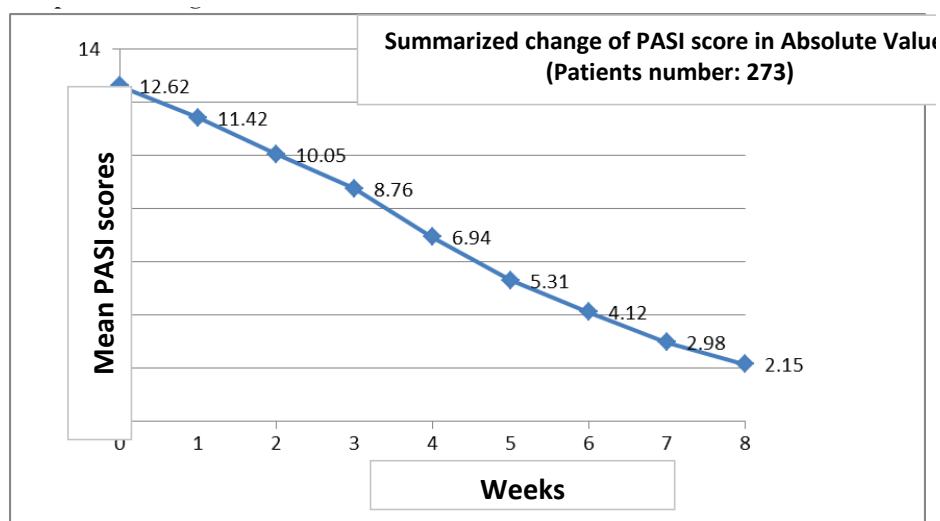
## RESULTS

The data presented here are the results of a group of 251 patients (109 female/142 male) who had completed 8 weeks of treatment. Thirteen patients had been excluded because the lack of compliance and 15 patients discontinued the treatment when they developed folliculitis, which regressed upon the discontinuation. Seven patients dropped out because of adverse reaction of contact dermatitis. After 8 weeks of treatment, 46 patients had a moderate improvement, with the regression of 25-50% of skin

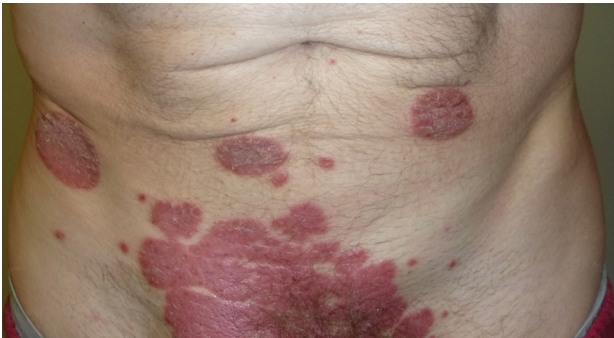lesions; 77 patients showed a good improvement, with the resolution of 51-75% of lesions. Another 115 patients had an outstanding improvement, with the regression of 76-98.86% of lesions. The treatment had been well tolerated. Fig. 2 shows the change in PASI scores throughout 8 weeks of treatment. Thirteen patients did not show improvement of psoriasis. Fig. 1 and Fig. 2 show patient photographs of before and after treatment, with total resolution of lesions after 8 weeks of treatment.

## DISCUSSION

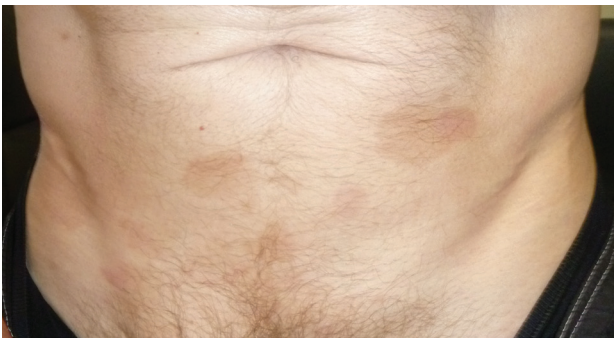Topical treatment of psoriasis has been limited to emollients, corticosteroids, vitamin D analogs, coal tar, calcineurin inhibitors, dithranol, retinoids, keratolytics and combination therapy. This study involved 251 patients (109 female/142 male) with mild to moderate psoriasis. They completed 8 weeks of treatment with DR Micheals® (Soratinex®) triple herbal formula for psoriasis. The majority of patients



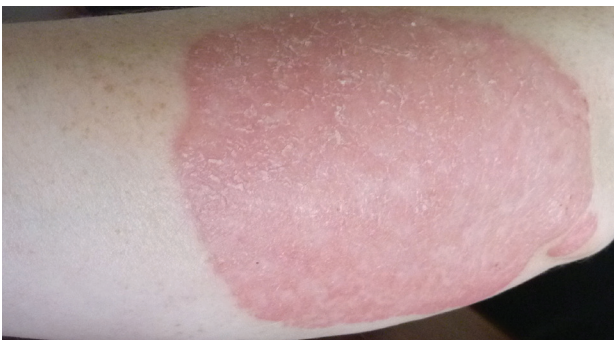**Graphic 1.** Changes in PASI score



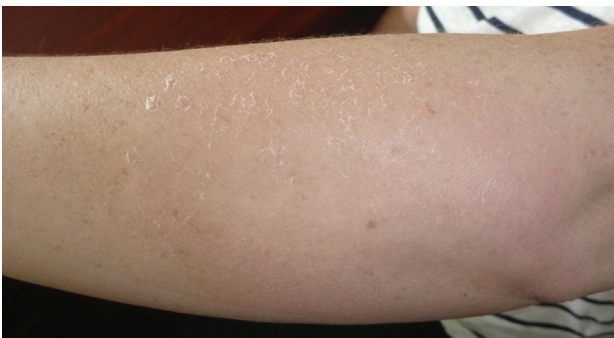**Fig. 1a.** *Week 0: Before treatment with Dr Michaels product family.*



**Fig. 1b.** *Week 8: Before treatment with Dr Michaels product family.*



**Fig. 2a.** *Week 0: Before treatment with Dr Michaels product family.*



**Fig. 2b.** *Week 8: Before treatment with Dr Michaels product family.*

presented significant improvement.

Adverse effects were mild and temporary, 15 patients developed folliculitis, which regressed upon the discontinuation and 7 patients developed adverse reaction of contact dermatitis.

This study investigated a new concept of corticosteroid-free topical therapy based on herbal skin care products. These new products proved to be effective and safe to the treatment of mild to moderate stable chronic plaque psoriasis

## CONCLUSIONS

Our investigation demonstrates that Dr. Michaels® (Soratinex®) products, an Australian series of herbal-based skin products, can be used successfully in the treatment of stable chronic plaque psoriasis. Moderate to good improvement, with regression of skin lesions was observed in the predominant percentage of cases, while the products were well tolerated without occurrence of contact sensitization.

## REFERENCES

1. Rencz F, Brodszky V, Péntek M, et al. Disease burden of psoriasis associated with psoriatic arthritis in Hungary. *Orv Hetil.* 2014; 155(48):1913-21.
2. Schäkel K, Schön MP, Ghoreschi K. [Pathogenesis of psoriasis]. *Hautarzt* 2016; 67(6):422-31.
3. Vaidya TS, Anderson KL, Feldman SR. Even well-controlled psoriasis patients have unmet treatment needs regardless of disease severity. *Dermatol Online J* 2015; 21:9.
4. Karczewski J, Dobrowolska A, Rychlewska-Hańczewska A, Adamski Z. New insights into the role of T cells in pathogenesis of psoriasis and psoriatic arthritis. *Autoimmunity.* 2016; 6:1-16.
5. Heller MM, Lee ES, Koo JY. Stress as an influencing factor in psoriasis. *Skin Therapy Lett* 2011; 16(5):1-4.
6. Campolmi E, Zanieri F, Santosuosso U, D'Erme AM, Betti S, Lotti T, Cossidente A. The importance of stressful family events in psoriatic patients: a retrospective study. *J Eur Acad Dermatol Venereol* 2012 Oct; 26(10):1236-9.
7. de Korte J, Sprangers MA, Mommers FM, Bos JD. Quality of life in patients with psoriasis: a system-



- atic literature review. *J Invest Dermatol Symp Proc* 2004; 9(2):140-7.
8. Langley R, Krueger G, Griffiths C. Psoriasis: epidemiology, clinical features, and quality of life. *Annals of the Rheumatic Diseases* 2005 ;64(S2):ii18.
  9. Bhosle MJ, Kulkarni A, Feldman SR, Balkrishnan R. Quality of life in patients with psoriasis. *Health and Quality of Life Outcomes* 2006; 4:35.
  10. Jurado-Santa Cruz F, Páez-Agraz F. From evidence to expertise: concordance in the topical management of psoriasis. *Rev Med Inst Mex Seguro Soc* 2016; 54(3):304-11.
  11. Girolomoni G, Griffiths CE, Krueger J, et al. Early intervention in psoriasis and immune-mediated inflammatory diseases: A hypothesis paper. *J Dermatolog Treat* 2015; 26(2):103-12.
  12. Laws PM1, Young HS. Topical treatment of psoriasis. *Expert Opin Pharmacother* 2010; 11(12):1999-2009.
  13. Fredriksson T, Pettersson U. Severe psoriasis - oral therapy with a new retinoid. *Dermatologica* 1978; 157(4):238-44.



## SUCCESSFUL TREATMENT OF MILD TO MODERATE ACNE VULGARIS WITH DR MICHAELS® (also branded as ZITINEX®) TOPICAL PRODUCTS FAMILY: A CLINICAL TRIAL

U. WOLLINA<sup>1</sup>, M. TIRANT<sup>2</sup>, P. BAYER<sup>2</sup>, M. COBURN<sup>2</sup>, M. SMITH<sup>2</sup>,  
B. DONNELLY<sup>2</sup>, T. KENNEDY<sup>2</sup>, J. GAIBOR<sup>2</sup>, M. ARORA<sup>2</sup>, L. CLEWS<sup>2</sup>, S. WALMSLEY<sup>2</sup>,  
J. HERCOGOVÁ<sup>3,4</sup>, M. FIORANELLI<sup>5</sup>, S. GIANFALDONI<sup>6</sup>, A.A. CHOKOEV<sup>7,8</sup>,  
G. TCHERNEV<sup>9</sup>, F.NOVOTNY<sup>10</sup>, M.G. ROCCIA<sup>11</sup>, G.K. MAXIMOV<sup>12</sup>, K. FRANÇA<sup>13,14</sup>  
and T. LOTTI<sup>15</sup>

<sup>1</sup>Department of Dermatology and Allergology, Academic Teaching Hospital Dresden-Friedrichstadt, Dresden, Germany; <sup>2</sup>Psoriasis & Skin Clinic, Melbourne, Australia; <sup>3</sup>2nd Medical Faculty, Charles University, Bulovka Hospital, <sup>4</sup>Institute of Clinical and Experimental Medicine, Prague, Czech Republic; <sup>5</sup>Department of Nuclear Physics, Sub-nuclear and Radiation, G. Marconi University, Rome, Italy; <sup>6</sup>Dermatological Department University of Pisa, Pisa, Italy; <sup>7</sup>"Onkoderma"- Polyclinic for dermatology and dermatologic surgery, Sofia, Bulgaria; <sup>8</sup>Department of Dermatology and Venereology, Medical University of Plovdiv, Medical faculty, Plovdiv, Bulgaria; <sup>9</sup>Medical Institute of Ministry of Interior (MVR), Department of Dermatology, Venereology and Dermatologic Surgery, Sofia, Bulgaria; <sup>10</sup>PRO SANUM Ltd., Sanatorium of Prof. Novotný, Štěpánská Prague I, Czech Republic; <sup>11</sup>University B.I.S. Group of Institutions, Punjab Technical University, Punjab, India; <sup>12</sup>Department "Medicinal Information and Non-interventional studies", Bulgarian Drug Agency, Sofia, Bulgaria; <sup>13</sup>Department of Dermatology & Cutaneous Surgery, Department of Psychiatry & Behavioral Sciences, Institute for Bioethics & Health Policy, University of Miami, Miller School of Medicine, Miami, FL, USA; <sup>14</sup>Centro Studi per la Ricerca Multidisciplinare e Rigenerativa, Università Degli Studi "G. Marconi", Rome, Italy; <sup>15</sup>Chair of Dermatology, University of Rome "G. Marconi" Rome, Italy

Acne vulgaris is an epidemic inflammatory skin disease of multi-factorial origin, frequently seen in adolescents and often persisting or occurring through to adulthood. Acne vulgaris is a nearly universal skin disease afflicting 79-95% of the adolescent population in westernized societies and is a significant cause of psychological morbidity in affected patients. Despite the various treatment options available for acne, there is still a need for a safe and effective option. The aim of the study was to investigate the efficacy and tolerability of Dr Michaels® (Zitinex®) product family in the treatment of papulo-pustular acne. 25 patients (17 female/8 male), aged 15-22, with a mild to moderate papulo-pustular acne, localized on the face and on the trunk, were included in this study. None of the patients had used any other kind of treatment in the 3 months prior to commencing this study. All of the patients were treated with Dr Michaels® (Zitinex®) facial exfoliating cleanser, activator formula, a cream, PSC 200 and PSC 900 oral supplements. Application time of Dr Michaels® (Zitinex®) products was 12 weeks. The treatment was been evaluated clinically at 0, 4, 8 and 12 weeks. All of the patients showed an improvement in all parameters of their acne (comedones, papules, pustules, hyperpigmentation and scars). The acne lesions and erythema had mostly resolved. The hyperpigmentation and pitted scarring had significantly reduced also, with the skin appearing smoother. The treatment was well tolerated and no side effects have been described. Our study demonstrates that the Dr Michaels® (Zitinex®) facial exfoliating cleanser, activator formula, cream and oral supplements PSC 200 and PSC 900 are an effective therapeutic option for the treatment of moderately severe acne vulgaris. Moreover, it highlights the safety profile of the Dr Michaels® (Zitinex®) product family in a case of acne compared to traditional first-line treatments.

*Key words: acne, topical products, oral herbal extracts, papulo-pustular acne, hyperpigmentation, pitted scarring, effectiveness, safety*

Mailing address:  
Professor Torello Lotti  
Department of Dermatology,  
University of Rome "G. Marconi",  
Rome, Italy  
e-mail: professor@torellolotti.it

Acne vulgaris is an epidemic inflammatory skin disease of multi-factorial origin, frequently seen in adolescents and often persisting or occurring into adulthood (1). The inflammatory processes that occur are attributed to the interplay between the gram-positive bacterium, *Propionibacterium acnes* (*P. acnes*), the innate immune response which propagates abnormal hyperkeratinization and inflammation and excessive sebum production (1). The pathogenesis of acne vulgaris includes follicular hyperkeratinization, sebaceous hypersecretion due to androgen stimulation, follicular colonization by *Propionibacterium acnes*, immune and inflammatory responses (1, 2). It affects the face, anterior chest and upper back (2). Acne vulgaris is a nearly universal skin disease afflicting 79-95% of the adolescent population in westernized societies and is a significant cause of psychological morbidity in affected patients (2).

Traditional therapeutic approaches for acne can be categorised into either topical or systemic (3, 4). Topical products include mainly retinoids and antibiotics, in addition active ingredients such as salicylic acid, azelaic acid, and benzoyl peroxide (4, 5). Whist systemic therapies include antibiotics, oral contraceptives and retinoid isotretinoin (5, 6). The gold standard for topical acne treatments, in terms of safety and efficacy, is benzoyl peroxide, which has shown to kill *P. acnes* through generation and release of oxygen free radicals (7, 8, 9). However, this treatment option is associated with primary irritant dermatitis (erythema, dryness, desquamation, burning, and itching), and thus patients experiencing these symptoms are advised to discontinue use (10). Other common topical agents indicated for the treatment of acne include aluminium, sulfur, sulfacetamide, resorcinol, and zinc, however, there is limited data proving the efficacy of these therapies (11).

Systemics are often prescribed for severe forms of acne or when acne is resistant to other therapies (7). The most commonly prescribed treatment for acne are oral antibiotics (5). This treatment option is effective for reducing the inflammation associated with lesions although its use does not completely clear acne (5). In addition, there is increasing concern regarding the issue of antibiotic resistance, specifically with erythromycin, to *P. acnes* which has questioned the use

of this commonly prescribed treatment (3, 4). The Oral contraceptives are effective at suppressing sebaceous gland activity and decreasing androgen secretion and thus is beneficial for females suffering acne who also need oral contraception (5), however, it is not clear how these treatments compare with alternative acne treatments (6). Currently, isotretinoin is considered the most effective systemic treatment for acne (7), however, it is associated with the most serious side effects that include teratogenicity, permanent side effects and in some cases an exacerbation of acne (8, 9, 10). Thus, despite the various treatment options available for acne, there is still a need for a safe and effective option.

The aim of the study was to investigate the efficacy and tolerability of Dr Michaels® (Zitinex®) product family in the treatment of papulo-pustular acnes.

## MATERIALS AND METHODS

The study was conducted on 25 patients (17 female/8male), aged 15-22. All of the patients had a mild to moderate papulo-pustular acne, localized on the face and sometimes on the trunk. None of the patients had used any other kind of treatment in the 3 months prior to commencing this study.

All patients were treated with Dr Michaels® (Zitinex®) facial exfoliating cleanser, activator formula, cream, PSC 200 and PSC 900 oral supplements.

The PSC 200 (2 tablets, twice daily) contains herbs including dandelion, echinacea, ginseng, licorice and astragalus and is an anti-inflammatory, anti-bacterial and immune stimulator. It was prescribed for the symptomatic relief and management of dry skin and its wound healing and skin renewal properties. It also maintains and supports the health of the liver and inhibits prostaglandin synthesis through the inhibition of COX-1 and COX-2 and activates T-Cells and natural killer (NK) cells.

The PSC 900 (5ml, twice daily) contains zinc, pyridoxine hydrochloride (B6), folic acid and ferrous gluconate. It facilitates the improvement and maintenance of general wellbeing, the symptomatic relief and management of dry skin and is necessary for the production and maintenance of new cells and DNA and RNA synthesis.

The Dr Michaels® (Zitinex®) facial exfoliating cleanser

(1 application per day) aids to gently exfoliate and remove dry flaky skin and excess oil, resulting in a softer and smoother complexion. The facial exfoliating cleanser contains glycolic acid, (an alpha hydroxy acid which is used for moisturizing and removing dead skin cells) for treating acne and improving the appearance of atrophic acne scars, improving the appearance of photo-aged skin, firming and smoothing skin. Hyperkeratinization appears to play a role in the development of acne and is often the result of decreases in the rate of skin cell sloughing, which in itself is due to an increase in the cohesion of cells known as corneocytes. Alpha hydroxy acids may decrease the cohesiveness of corneocytes by weakening intracellular bonding, thereby freeing skin cells and permitting more efficient cell removal and skin cleansing. It has been proposed that alpha hydroxy acids reduce the calcium ion concentration in the epidermis and remove calcium ions from the cell adhesions by chelation. This causes a loss of calcium ions from the cadherins of the desmosomes and adherens junctions, from the tight junctions and possibly also from other divalent metallic cation-dependent cell adhesion molecules. The cell adhesions are thereby disrupted, resulting in desquamation. Desquamation is enhanced by cleavage of the endogenous stratum corneum chymotryptic enzyme on the cadherins, which are otherwise protected from proteolysis by conjugation with calcium ions (16).

Dr Michaels® (Zitinex®) Activator lotion (1/day) enhances keratolysis of the stratum corneum while repairing barrier function and also aids to reduce scarring. It contains alpha hydroxy acids including, Glycolic, Lactic, Benzoic and Salicylic Acids. Dr Michaels® (Zitinex®) Activator lotion has active properties against numerous pathogenic bacteria and fungi that cause acne and infection. The acids contained in Dr Michaels® (Zitinex®) Activator lotion are keratolytic agents that promote shedding of the keratinized epithelial cells on the surface of the skin, preventing closure of the pilosebaceous orifice and formation of follicular plugs, and facilitating the flow of sebum. The various compounds cause this effect via different mechanisms. The keratolytic agents also possess varying levels of antimicrobial activity, which contributes to their effectiveness. Keratolytic agents facilitates desquamation of the lesions by solubilizing the intercellular cement that binds scales in the stratum corneum, thereby loosening the keratin/epidermis and

facilitating the penetration of other medicaments into the skin and produces their action against the skin lesion.

Finally, Dr Michaels® (Zitinex®) Cream (1/day) was especially formulated for the treatment of acne and acne scarring and contains both anti-microbial and keratolytic properties. The cream has active properties against numerous pathogenic bacteria that cause acne and bacterial infections. It also has anti-androgenic, anti-pruritic, anti-inflammatory and anti-oxidant properties. Dr Michaels® (Zitinex®) Cream promotes cellular proliferation, differentiation and wound healing. Some of the ingredients include glycolic and lactic acid, and the essential oils of chamomile, tea tree, avocado and lavender.

Application time of Dr Michaels® (Zitinex®) topical and oral products was 16 weeks. The treatment has been evaluated clinically at 0, 4, 8 and 12 weeks.

## RESULTS

All the patients showed an improvement in all parameters of their acne (comedones, papules, pustules, scars).

Specifically, the acne lesions and erythema had mostly resolved. In addition, the pitted scarring had significantly reduced with the skin appearing smoother. Some minor evidence of scar tissue remains. The treatment was well tolerated and no side effects have been described.

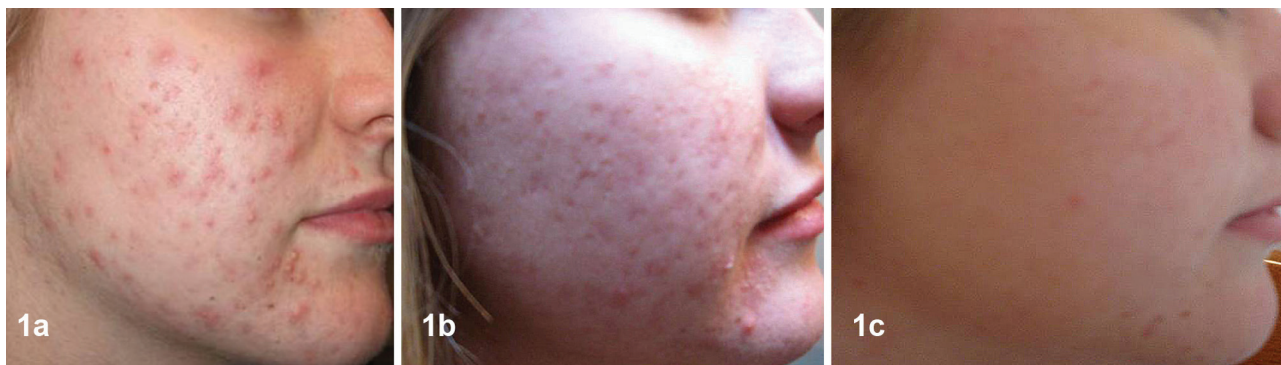## DISCUSSION

The successful therapeutic outcome of patients' acne following Dr Michaels® (Zitinex®) topicals and oral product family treatment is attributed to the synergistic effect of the facial exfoliating cleanser, activator formula, cream and oral supplements. The main active ingredients in Dr Michaels® (Zitinex®) exfoliating cleanser include glycolic acid and vitamins A and B. Glycolic acid is an alpha hydroxy acids (AHAs) which aids desquamation of the stratum corneum, while vitamin A and B play important, enzymatic roles aiding in the reduction of pore size and sebum production. The active ingredients in Dr Michaels® (Zitinex®) activator lotion include fruit acid complexes and salicylic acid. Salicylic acid

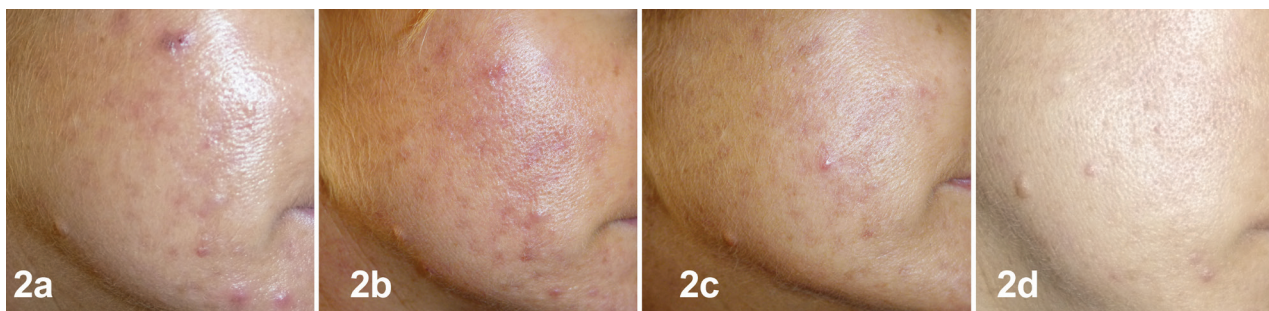
possesses anti-inflammatory, anti-Seborrhoeic and anti-microbial properties, which aid to reduce acne and acne scarring. Dr Michaels® (Zitinex®) cream contains various keratolytic agents and anti-microbial agents which further potentiate the beneficial anti-acne effects. Lastly, the oral PSC 200 formulation contains a range of herbal extracts including berberis vulgaris stem bark, astragalus membranaceus root, taraxacum officinale root and Panax ginseng root. The combination of herbal extracts acts as an anti-bacterial, anti-fungal and anti-viral agent. Whilst the PSC 900 is a liquid supplement, containing various vitamins and mineral including high doses of zinc. This formulation supports the immune system to help achieve healthy skin.

## CONCLUSION

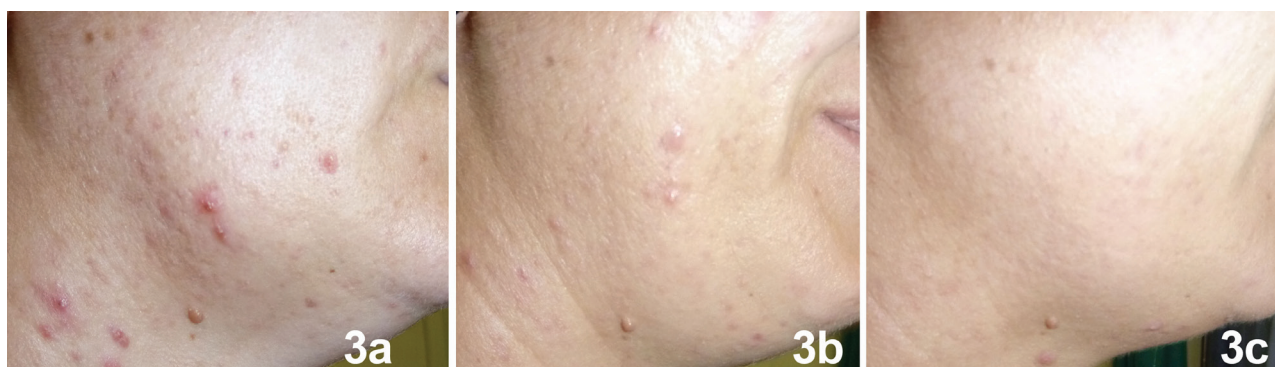In conclusion, our results demonstrate that Dr Michaels® (Zitinex®) facial exfoliating cleanser, activator lotion, cream, PSC 200 and PSC 900 oral supplements, are an effective therapeutic option for the treatment of moderately severe acne vulgaris. Moreover, it highlights the safety profile of the Dr Michaels® (Zitinex®) topical and oral product family in acne compared to traditional first-line treatments. These data have important implications for resistant cases of acne where traditional therapies have failed. In addition, this treatment approach may be an attractive option for patients who have growing concerns regarding the effectiveness of antibiotics



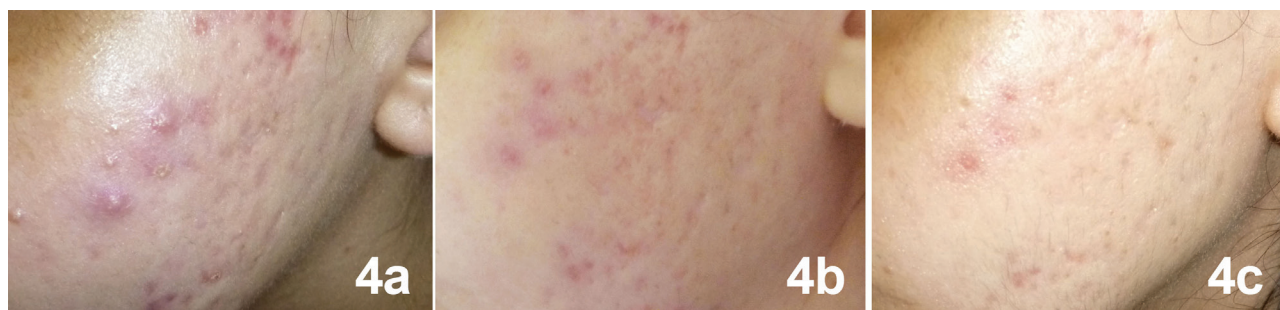
**Fig. 1. a):** Prior to treatment with Dr Michaels® (Zitinex®) topicals and oral product family, the patient demonstrated moderately severe inflammatory pustules and erythematous papules on the face. There is also evidence of pitted acne scarring; **b):** Following 8-weeks of treatment with the Dr Michaels® (Zitinex®) topical and oral product family, the patient demonstrated attenuation in inflammatory pustules and red papules on her face. **c):** Following 12-weeks of treatment with the Dr Michaels® (Zitinex®) topical and oral product family, the patient demonstrated complete resolution of the acne on her face. Acne scarring was also significantly reduced.



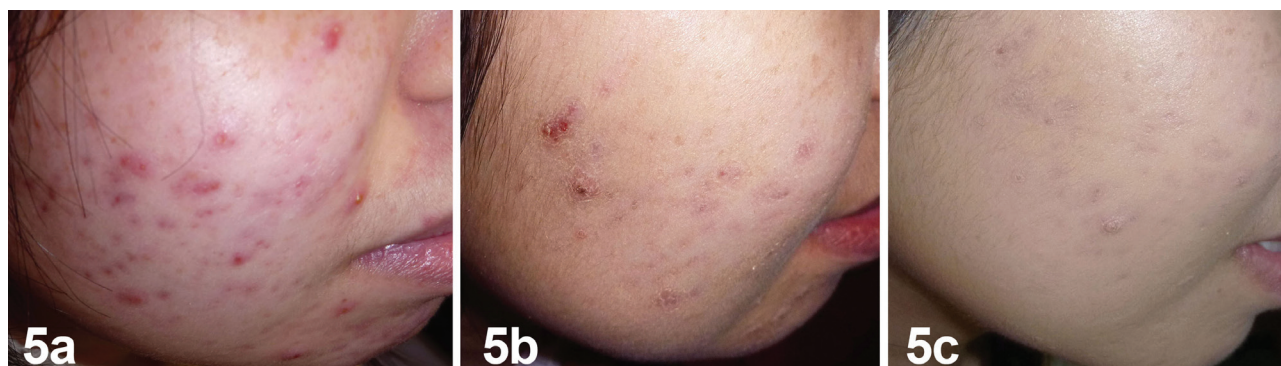
**Fig. 2. a):** Prior to treatment with Dr Michaels® (Zitinex®) product family, the patient demonstrated mild inflammatory pustules and hyperpigmented pitted acne scarring on the face; **b):** Following 4-weeks of treatment with the Dr Michaels® (Zitinex®) product family, the patient demonstrated attenuation in inflammatory pustules on her face; **c):** Following 8-weeks of treatment with the Dr Michaels® (Zitinex®) product family, the patient shows a reduction in hyperpigmentation, smoother skin with a reduction of the acne scarring. **d):** Following 12-weeks of treatment with the Dr Michaels® (Zitinex®) product family, the patient demonstrated almost complete resolution of the acne on her face. Also, acne scarring was significantly reduced and the hyperpigmentation totally resolved.



**Fig. 3. a):** Prior to treatment with Dr Michaels® (Zitinex®) product family, the patient demonstrated moderate inflammatory pustules and papules with hyperpigmented pitted acne scarring on the face; **b):** Following 8-weeks of treatment with the Dr Michaels® (Zitinex®) product family, the patient demonstrated attenuation in inflammatory pustules on her face. Significant reduction can be seen in both hyperpigmentation and acne scarring; **c):** Following 12-weeks of treatment with the Dr Michaels® (Zitinex®) product family, the patient show a total resolution of the hyperpigmentation, with smoother skin and a reduction of the acne scarring.



**Fig. 4. a):** Prior to treatment with Dr Michaels® (Zitinex®) product family, the patient demonstrated moderate inflammatory pustules and papules with severe hyperpigmented, deeply, pitted acne scarring on the face; **b):** Following 8-weeks of treatment with the Dr Michaels® (Zitinex®) product family, the patient demonstrated attenuation in inflammatory pustules on the face. Some reduction can be seen in both hyperpigmentation and acne scarring; **c):** Following 12-weeks of treatment with the Dr Michaels® (Zitinex®) product family, the patient show a good resolution of the hyperpigmentation, with a reduction of the acne scarring.



**Fig. 5. a):** Prior to treatment with Dr Michaels® (Zitinex®) product family, the patient demonstrated moderate inflammatory pustules and papules with hyperpigmented, pitted acne scarring on the face; **b):** Following 8-weeks of treatment with the Dr Michaels® (Zitinex®) product family, the patient demonstrated significant reduction in the number of inflammatory pustules on the face. Some reduction can be seen in both hyperpigmentation and acne scarring; **c):** Following 12-weeks of treatment with the Dr Michaels® (Zitinex®) product family, the patient show a good resolution of the hyperpigmentation, with good reduction of the acne scarring. Most of the pustules had resolved.

due to the development of antibiotic resistance to the various strains of *P.acnes*.

#### ACKNOWLEDGEMENTS

We gratefully acknowledge Tirsell Pty Ltd (Melbourne, Australia) and Frankl Pharma Global Ltd. (2 Parklands Place, Guilford, Surrey, United Kingdom) for providing the products for the studies.

#### REFERENCES

1. Das S, Reynolds RV. Recent advances in acne pathogenesis: implications for therapy. *Am J Clin Dermatol* 2014; 15(6):479-88.
2. Williams HC, Dellavalle RP, Garner S. Acne vulgaris. *Lancet* 2012; 379(9813):361-72.
3. Eady AE, Cove JH, Layton AM. Is antibiotic resistance in cutaneous propionibacteria clinically relevant? Implications of resistance for acne patients and prescribers. *Am J Clin Dermatol* 2003; 4(12):813-31.
4. Simonart T, Dramaix M. Treatment of acne with topical antibiotics: lessons from clinical studies. *Br J Dermatol* 2005; 153(2):395-403.
5. Gollnick H, Cunliffe W, Berson D, et al; Global Alliance to Improve Outcomes in Acne. Management of acne: a report from a global alliance to improve outcomes in acne. *J Am Acad Dermatol* 2003; 49(1S):1-37.
6. Arowojolu AO, Gallo MF, Lopez LM, Grimes DA, Garner SE. Combined oral contraceptive pills for treatment of acne. *Cochrane Database Syst Rev* 2009; 3:CD004425.
7. Bojar RA, Cunliffe WJ, Holland KT. The short-term treatment of acne vulgaris with benzyl peroxide: effects on the surface and follicular cutaneous microflora. *Br J Dermatol* 1995; 132(2):204-8.
8. Haider A, Shaw JC. Treatment of acne vulgaris. *JAMA* 2004; 292(6): 726-35.
9. Ramos-e-Silva M, Carneiro SC. Acne vulgaris: review and guidelines. *Dermatol Nurs* 2009; 21(2):63-8.
10. Lowenstein EJ. Isotretinoin made SMART and simple. *Cutis* 2002; 70(2):115-20.
11. Wang X. Theory for the mechanism of action of the alpha-hydroxy acids applied to the skin.; *Med Hypotheses* 1999; 53(5):380-2.
12. Rosenmeier GJ, Torok HM. iPLEDGE and its implementation in Dermatology practices. *Cos Dermatol* 2013:6-8.
13. Strauss JS, Krowchuk DP, Leyden JJ, et al. American Academy of Dermatology/American Academy of Dermatology Association. Guidelines of care for acne vulgaris management. *J Am Acad Dermatol* 2007; 56(4):651-63.
14. Amann W. Acne vulgaris and Agnus castus (Agnolyt) *Z Allgemeinmed* 1975; 51:1645-48.



## INVESTIGATION OF THE EFFICACY AND TOLERABILITY OF DR MICHAELS® (also branded as ECZITINEX® and ITCHINEX ECZITINEX®) TOPICAL PRODUCTS IN THE TREATMENT OF ATOPIC DERMATITIS IN CHILDREN

K. FRANÇA<sup>1,14</sup>, J. HERCOGOVÁ<sup>2,3</sup>, M. FIORANELLI<sup>4</sup>, S. GIANFALDONI<sup>5</sup>,  
A.A. CHOKOEVA<sup>6,7</sup>, G. TCHERNEV<sup>8</sup>, U. WOLLINA<sup>9</sup>, M. TIRANT<sup>10</sup>, P. BAYER<sup>10</sup>,  
M. COBURN<sup>10</sup>, M. SMITH<sup>10</sup>, B. DONNELLY<sup>10</sup>, T. KENNEDY<sup>10</sup>, J. GAIBOR<sup>10</sup>,  
M. ARORA<sup>10</sup>, L. CLEWS<sup>10</sup>, F. NOVOTNY<sup>11</sup>, M.G. ROCCIA<sup>12</sup>, G.K. MAXIMOV<sup>13</sup>  
and T. LOTTI<sup>15</sup>

<sup>1</sup>Department of Dermatology & Cutaneous Surgery, Department of Psychiatry & Behavioral Sciences, Institute for Bioethics & Health Policy, University of Miami Miller School of Medicine, Miami, FL, USA; <sup>2</sup>2nd Medical Faculty, Charles University, Bulovka Hospital, <sup>3</sup>Institute of Clinical and Experimental Medicine, Prague, Czech Republic; <sup>4</sup>Department of Nuclear Physics, Sub-nuclear and Radiation, G. Marconi University, Rome, Italy; <sup>5</sup>Dermatological Department University of Pisa, Pisa, Italy; <sup>6</sup>"Onkoderma"-Polyclinic for dermatology and dermatologic surgery, Sofia, Bulgaria; <sup>7</sup>Department of Dermatology and Venereology, Medical University of Plovdiv, Medical faculty, Plovdiv, Bulgaria; <sup>8</sup>Medical Institute of Ministry of Interior (MVR), Department of Dermatology, Venereology and Dermatologic Surgery, Sofia, Bulgaria; <sup>9</sup>Department of Dermatology and Allergology, Academic Teaching Hospital Dresden-Friedrichstadt, Dresden, Germany; <sup>10</sup>Psoriasis & Skin Clinic, Melbourne, Australia; <sup>11</sup>PRO SANUM Ltd, Sanatorium of Prof. Novotný, Štěpánská Prague 1, Czech Republic; <sup>12</sup>University B.I.S. Group of Institutions, Punjab Technical University, Punjab, India; <sup>13</sup>Department "Medicinal Information and Non-interventional studies", Bulgarian Drug Agency, Sofia, Bulgaria; <sup>14</sup>Centro Studi per la Ricerca Multidisciplinare e Rigenerativa, Università Degli Studi "G. Marconi", Rome, Italy; <sup>15</sup>Chair of Dermatology, University of Rome "G. Marconi" Rome, Italy

**Atopic eczema is a chronic relapsing inflammatory skin disorder, characterized clinically by intensely pruritic eczematous skin lesions and a defective epidermal barrier. It affects more than 15% of children and up to 10% of adults, which makes the disease a social health problem still without a challenging treatment. The aim of this study was to evaluate the efficacy and tolerability of Dr Michaels® (Eczitinex®) topical product family in the treatment of atopic dermatitis in children. We studied a group of 30 patients (17 female, 13 male), aged 5 to 13 (mean age: 9), affected by atopic dermatitis since they were newborn. All patients had been unsuccessfully treated with conventional anti-inflammatory therapies and ceased treatment 2 weeks before commencing research. The patients were treated with Dr Michaels® (Eczitinex® and Itchinex®) product family including a moisturising bar, topical ointment and PSC 900 oral herbal formulation. The treatment was evaluated clinically and photographically at 0, 1, 2, 4, 6, 8, 10, 12, and 14 weeks. Twenty-eight patients showed a significant improvement of cutaneous rashes and pruritus on the first week of treatment, with a complete remission at 10-12 weeks. Only two patients, brother and sister respectively, showed a slow response to treatment and reported an increasing itching. Following 14 weeks of treatment with the Dr Michaels® (Eczitinex® and Itchinex®) product family, patients demonstrated complete resolution of their AD. All patients showed a marked improvement in their condition within 3 days of treatment with most of the lesions and symptoms totally resolved within 10 to 12 weeks of treatment with Dr Michaels® (Eczitinex® and Itchinex®) family of products. This clinical report highlights that the Dr Michaels® (Eczitinex® and Itchinex®) product family is a safe and effective treatment option for AD.**

*Key words: atopic dermatitis, moisturizing bar, topical ointment, oral herbal formulation, Eczema Area and Severity Index, efficacy, tolerability*

Mailing address:  
Professor Torello Lotti  
Chair of Dermatology,  
University of Rome "G. Marconi",  
Rome, Italy  
e-mail: professor@torelloLotti.it

Atopic eczema, also known as atopic dermatitis (AD), is a chronic relapsing inflammatory skin disorder, characterized clinically by intensely pruritic eczematous skin lesions (1) and a defective epidermal barrier (1). The severe pruritus of AD is mediated by hyperreactivity to various environmental and endogenous stimuli such as food and inhalant allergens, irritants, changes in physical environment (including pollution, humidity, etc.), microbial infection and stress (1). AD is a common skin disease, affecting more than 15% of children and 2-10% of adults in industrialised countries (2). Allergic diseases, including asthma, food and rhinitis, are also common in AD patients (2).

AD is often associated with both a compromised skin barrier function and a defect in the innate immunity of the skin (2). However, it is more common in early childhood (3), where constant scratching of the area results in red, scaly and cracked presentation of the skin with the potential for secondary infection (4). In chronic eczema, lichenification of the epidermis is often observed, characterized by hyperkeratosis and an accentuation of skin lines especially in the region of the antecubital fossa, popliteal fossa and nape. Parakeratosis with exudate inclusions (serum crusts) may also be observed.

Recent studies indicate that defects in epidermal barrier function contribute greatly to triggering and exacerbation of skin inflammation in AD. In patients with AD, the skin is characterized by increased transepidermal water loss, and a defect in terminal keratinocyte differentiation, which leads to reduced levels of ceramides, filaggrin and antimicrobial peptides. Concomitantly, an increase in protease activity and pro-inflammatory cytokine release is observed, which results from increased endogenous keratinocyte and mast cell derived proteases that are released in atopic skin, as well as exogenous proteases from environmental allergens, such as dust mites, or *Staphylococcus aureus* resulting in skin barrier breakdown (3).

The pathogenesis of AD appears to be multifactorial, involving skin barrier defects most likely associated with increased interleukin IL-4 and IL-13 expression (5). In addition, innate immunity involving Toll-like receptors (TLRs), IL-33, IL-

25, and innate lymphoid cells are also suggested to play a role in the pathogenesis of AD (5), where a defect in these microbial sensing receptors increases the risk of developing AD (6-8). Histologically, atopic dermatitis is characterised by spongiosis or intercellular oedema, fluid accumulation within intraepidermal vesicles, infiltration of lymphocytes. Note that parakeratosis generally forms above areas of spongiosis. Dermal changes include oedema to varying degrees and a superficial perivascular infiltrate with lymphocytes, histiocytes and occasional neutrophils and eosinophils (9). The main aim of therapy for atopic dermatitis is to restore the function of the epidermal barrier in order to reduce skin inflammation and pruritus (10). Traditional / conventional topical treatment options for atopic dermatitis include over the counter skin emollients through to corticosteroids, immunomodulators, calcineurin inhibitors and phototherapy. Systemic medications include methotrexate, cyclosporine, corticosteroids, azathioprine, interferon- $\gamma$  and mycophenolate mofetil (11), however, it is important to note that these systemic medications are not officially approved for their use in AD and treatment with these agents is considered "off-label" (11). Furthermore, systemic corticosteroids, although effective as an immunosuppressive treatment for severe AD, have associated side effects which limit their long-term use. Antibiotics may also be prescribed for coverage of secondary infections.

The need for new and effective treatment options for atopic dermatitis with a limited side-effect profile is warranted, particularly for difficult-to-treat cases, such as cases demonstrating incomplete remission, children, pregnant and breastfeeding mothers. Thus, herbal therapies are a plausible option.

The aim of this study was to evaluate the efficacy and tolerability of Dr Michaels<sup>®</sup> (Eczitinex<sup>®</sup> and Itchinex<sup>®</sup>) product family in the treatment of atopic dermatitis in children.

## MATERIALS AND METHODS

The clinical study was conducted in 30 patients (17 female, 13 male), aged 5 to 13 years-of-age (mean age: 9), affected by atopic dermatitis since they were newborn. All

patients had been unsuccessfully treated with conventional anti-inflammatory therapies.

The clinical features were classic. All the subjects presented a xerotic and itchy skin and rashes in the antecubital and popliteal fossae. Eighteen of them also had an axillae inflammation, of which 9 on the face and neck.

The study period was 14 weeks with assessment at 0, 2, 4, 6, 8, 10, 12 and 14 weeks. Patients discontinued all forms of treatment 2 weeks before the trial. We used Eczema Area and Severity Index (EASI) scores for the assessment (12). Patient improvement was determined by the percentage reduction of the EASI scores and photographic analysis. Side effects and tolerability were also evaluated.

#### *EASI score*

An EASI score is a tool used to measure the extent (area) and severity of atopic eczema. EASI score does not include a grade for dryness or scaling. EASI includes assessment of the following features:

#### *Body regions*

There are four body regions:

- Head and neck
- Trunk (including genital area)
- Upper limbs
- Lower limbs (including buttocks)

#### *Area score*

Area score is recorded for each of the four regions of

the body. The area score is the percentage of skin affected by eczema (as shown in Table I).

#### *Severity score*

Severity score is recorded for each of the four regions of the body. The severity score is the sum of the intensity scores for four signs. The four signs are:

- Redness (erythema, inflammation)
- Thickness (induration, papulation, swelling-acute eczema)
- Scratching (excoriation)
- Lichenification (lined skin, prurigo nodules-chronic eczema).

The average intensity of each sign in each body region is assessed as none (0), mild (1), moderate (2) and severe (3) (as shown in Table II)..

The 16 images were chosen as typical examples of different intensities of each sign (as shown in Table III).

#### *Tested Products*

Dr Michaels® (Eczitinx® and Itchinex®) product family includes:

- Moisturising bar: Used for its cleansing and soothing properties. Cleansing removes unwanted dirt, soil, and bacteria from skin and also removes endogenous dirt (crusts, scales etc.), preparing the permeability of the skin barrier to better absorb subsequently applied topical medication. The ingredients in the moisturising bar include tocopheryl acetate, and various essential oils (lavender oil, evening primrose oil). These

**Table I.** *Area score.*

Area score	Percentage of skin affected by eczema in each region
0	0: no eczema in this region
1	1-9%
2	10-29%
3	30-49%
4	50-69%
5	70-89%
6	90-100%: the entire region is affected by eczema

**Table II.** *Severity score.*

Score	Intensity of redness, thickness/swelling, scratching, lichenification
0	None, absent
1	Mild
2	Moderate
3	Severe

ingredients are known to have anti-pruritic properties and form a moisturising foamy lather when combined with water. Many of the ingredients are classified as skin conditioning and emollients. Dr Michaels® (Eczitinex® and Itchinex®) Moisturising Bar is gentle enough to use on the entire body including the most sensitive skin.

- Topical ointment: an anti-inflammatory that provides barrier repair while restoring skin lipid imbalances. The ointment contains a synergistic blend including zinc oxide, castor oil, emu oil in a petroleum jelly, glycerine base. Zinc is required for collagen and protein synthesis as low levels of zinc are associated with impaired wound healing. Zinc is also required for cellular growth and replication and may assist in wound healing by reducing free radical activity and inhibiting bacterial growth. Zinc serves as a cofactor in numerous transcription factors and enzyme systems including zinc-dependent matrix metalloproteinases (MMP) that augment autodebridement and keratinocyte migration during wound repair. Zinc confers resistance to epithelial apoptosis through stabilizing cellular membranes, cytoprotection against reactive oxygen species and bacterial toxins through anti-oxidant activity of the cysteine-rich metallothioneins (MT) and superoxide dismutase (13). The constituent ingredients of this carefully blended formula, addresses the different factors that contribute to dry skin and restores epidermal differentiation. The essential oils and herbal

extracts in topical ointment not only addresses the different factors that contribute to dry skin but also restores epidermal differentiation by restoring the lipid lamellae, improve skin hydration, skin elasticity and prevent itching.

- Dr Michaels® (Eczitinex® and Itchinex®) PSC 900 (2ml/ twice daily): a zinc and folic acid based supplement which facilitates the improvement and maintenance of general wellbeing and contains zinc, pyridoxine hydrochloride (B6), folic acid and ferrous gluconate. It facilitates the improvement and maintenance of general wellbeing, the symptomatic relief and management of dry skin and is necessary for the production and maintenance of new cells and DNA and RNA synthesis.

The patients were prescribed the Dr Michaels® (Eczitinex® and Itchinex®) product family including a moisturising bar, topical ointment and oral herbal formulation - PSC 900. The treatment was evaluated clinically and photographically at 0, 2, 4, 6, 8, 10 and 12 weeks.

## RESULTS

Twenty-eight patients showed a significant improvement of cutaneous rashes and pruritus by the first week of treatment. Two patients worsened and discontinued treatment.

Before the application of Dr Michaels®

Table III. Intensity score.

Intensity	None	Mild	Moderate	Severe
Redness	 Score 0	 Score 1	 Score 2	 Score 3
Thickness/ swelling	 Score 0	 Score 1	 Score 2	 Score 3
Scratching	 Score 0	 Score 1	 Score 2	 Score 3
Lichenification/ prurigo	 Score 0	 Score 1	 Score 2	 Score 3

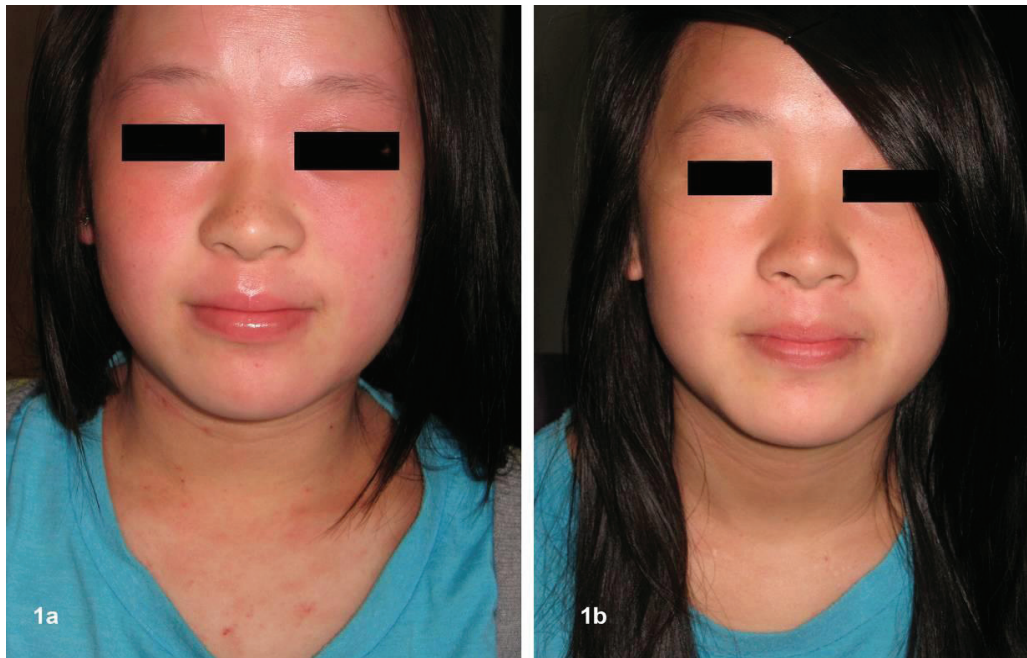(Eczitinex<sup>®</sup> and Itchinex<sup>®</sup>) product family, the mean EASI scores was 6.9+/-2.2 SD. After 12 weeks of application of Dr Michaels product family, the mean EASI scores was 1.2+/-1.4 SD, which is equivalent to an EASI score reduction of 82%. Seventy-two% of the patients achieved total resolution after 10-12 weeks of treatment.

Only two patients, respectively brother and sister, showed a slow response to treatment after 6 weeks and reported an increasing itching. We were advised that the patients were having swimming lessons in chlorinated public pools. The parents were advised to stop the swimming lessons, as chlorine was aggravating their condition. There was noticeable increase in pruritus after swimming. The patients

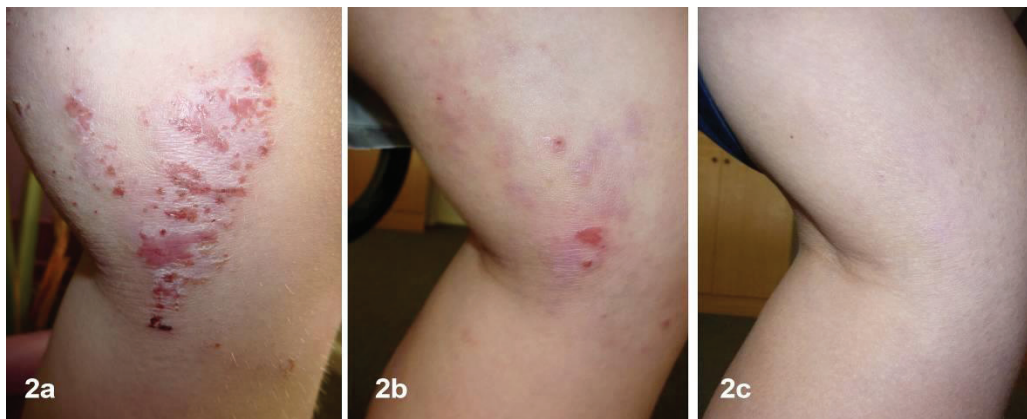
discontinued swimming. After a further 6 weeks of treatment with the Dr Michaels<sup>®</sup> (Eczitinex<sup>®</sup> and Itchinex<sup>®</sup>) product family, the majority of the lesions had resolved. We present 6 cases below:

## DISCUSSION

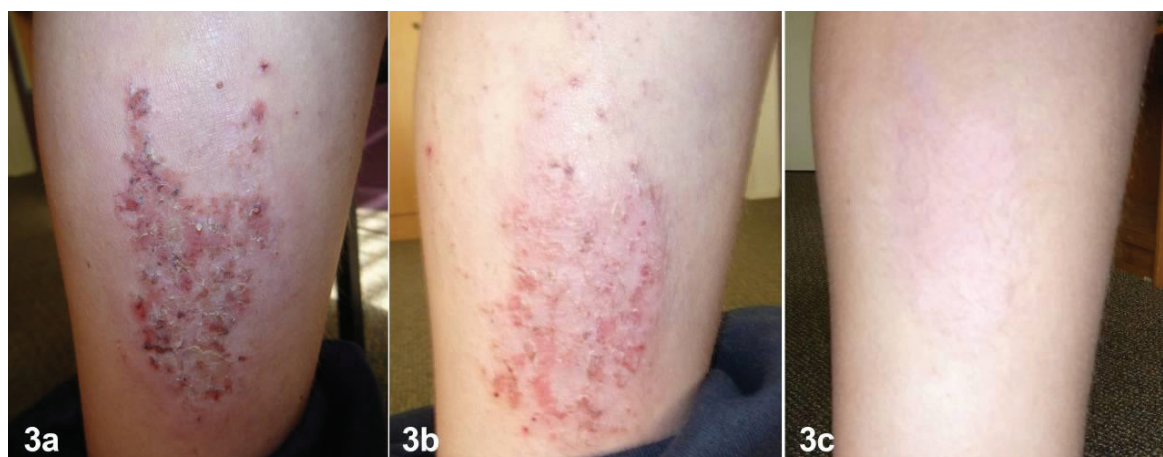It has been found that debris on eczematous skin such as scales, has the ability to promote the growth of *staphylococcus aureus*. On the other hand, the diversity of skin microbiome reduces during AD flares (13). *Staphylococcus aureus* (*S. aureus*) has a peculiar ability to colonize the skin of patients with eczema and atopic dermatitis (AD) and is consistently found in eczematous skin lesions in



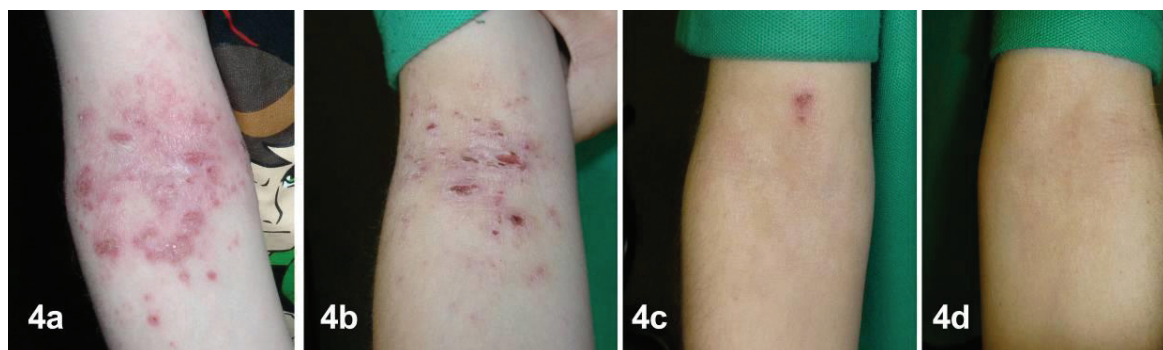
**Fig. 1.** 13-year-old girl **a)** Prior to treatment with Dr Michaels® (Eczitinex®) product family, the patient presented with AD on the face, neck and chest regions. Excoriations were evident on the chest and there was oedema of the eyelids and lips. The Patient experienced severe pruritus; **b)** Following 8 weeks of treatment with Dr Michaels® (Eczitinex®) product family, the patient had achieved remission with all lesions, erythema and oedema resolved. Patient no longer experienced pruritus.



**Fig. 2.** 12-year-old girl. **a)** Prior to treatment with Dr Michaels® (Eczitinex®) product family, the patient presented with extensive excoriations, with an erythematous base and serous exudate; **b)** Following 4 weeks of treatment with Dr Michaels® (Eczitinex®) product family, the patient showed a significant improvement in her AD with a reduction of excoriations, parakeratosis and pruritus. Some hyperpigmentation is evident; **c)** Following 8 Weeks of treatment with Dr Michaels® (Eczitinex®) product family the AD has completely resolved. Specifically, excoriations, erythema and hyperpigmentation are no longer observed.



**Fig. 3.** 13-year-old boy. **a)**: Prior to treatment with Dr Michaels® (Eczitinex®) product family, the patient presented with extensive excoriations, with an erythematous base and serous exudate on the calf region; **b)**: Following 4 weeks of treatment with Dr Michaels® (Eczitinex®) product family, the patient showed a significant improvement in his AD with a reduction of excoriations, parakeratosis and pruritus; **c)**: Following 10 Weeks of treatment with Dr Michaels® (Eczitinex®) product family, showed continued improvement in his AD. The AD has completely resolved. Specifically, excoriations, erythema is no longer observed. Some hypopigmentation can be observed.

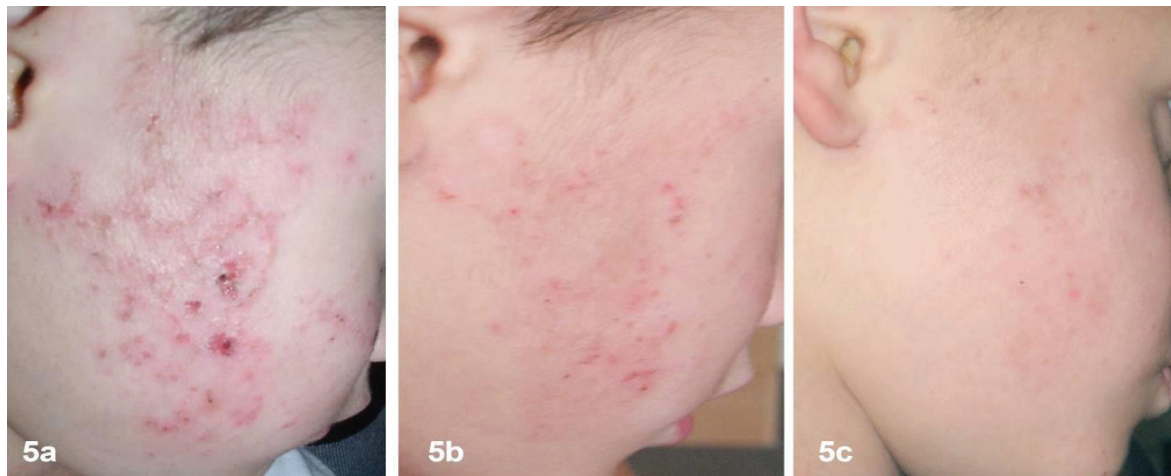


**Fig. 4.** 5-year-old boy. **a)**: Prior to treatment with Dr Michaels® (Eczitinex®) product family, the patient presented with extensive excoriations, with an erythematous base and serous exudate on the cubital fossa; **b)**: Following 2 weeks of treatment with Dr Michaels® (Eczitinex®) product family, the patient showed a significant improvement in his AD with a reduction of excoriations, parakeratosis and pruritus; **c)**: Following 6 weeks of treatment with Dr Michaels® (Eczitinex®) product family, showed continued improvement in his AD. The AD had almost completely resolved. Specifically, excoriations, erythema are no longer observed. Some hypopigmentation can be observed; **d)**: Following 8 weeks of treatment with Dr Michaels® (Eczitinex®) product family, showed continued improvement in his AD. The AD has completely resolved. Specifically, excoriations, erythema and hypopigmentation are no longer observed.

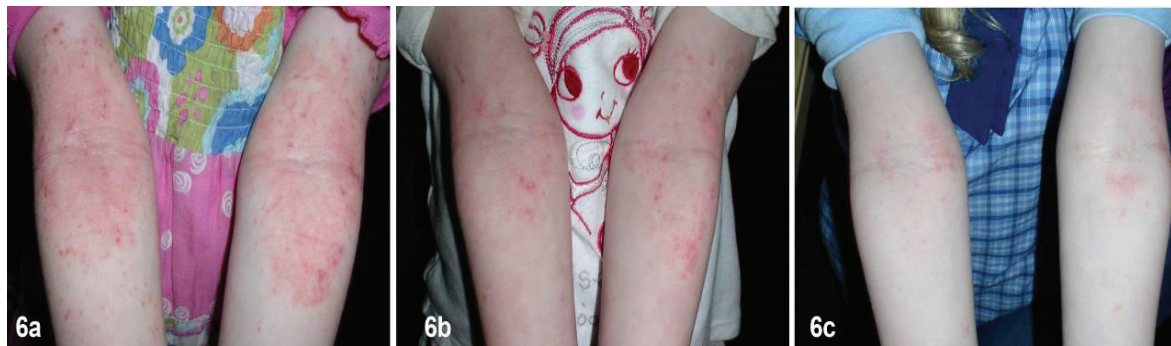these patients. A correlation between the severity of the eczema and colonization with *S. aureus* has been demonstrated. Bacterial colonization is an important factor aggravating skin lesions (14, 15). Cleansing of the skin is important as it removes both endogenous and exogenous dirt (15).

The skin barrier defect observed in AD, causes an

increase in Transepidermal Water Loss (TEWL) which favours xerosis, an increase of allergen and irritant substances penetration, provoking inflammation and a reduction of AMP production which could provoke an increase in skin adhesion and proliferation of bacteria such as *S. aureus* which could initiate AE flare episodes (14, 15). Dryness of the skin is a hallmark of AD



**Fig. 5.** 5-year-old boy. **a)** Prior to treatment with Dr Michaels® (Eczitinex®) product family, the patient presented with excoriations with an erythematous base and serous exudate on the cheeks; **b)** Following 2 weeks of treatment with Dr Michaels® (Eczitinex®) product family, the patient showed a significant improvement in his AD with a reduction of excoriations, parakeratosis and pruritus; **c)** Following 6 weeks of treatment with Dr Michaels® (Eczitinex®) product family, showed continued improvement in his AD. The AD had almost completely resolved. Specifically, excoriations, erythema are no longer observed.



**Fig. 6.** 6-year-old girl. **a)** Prior to treatment with Dr Michaels® (Eczitinex®) product family, the patient presented with extensive excoriations, with an erythematous base, lichenification and serous exudate on the cubital fossa; **b)** Following 4 weeks of treatment with Dr Michaels® (Eczitinex®) product family, the patient showed a significant improvement in his AD with a reduction of excoriations, and lichenification. **c)** Following 6 weeks of treatment with Dr Michaels® (Eczitinex®) product family, showed continued improvement in her AD. The AD had almost completely resolved. Specifically, excoriations, erythema is no longer observed. Some hypopigmentation can be observed.

and results from an impaired epidermal barrier with increased TEWL as well as from defective production of the natural moisturizing factor. An altered skin barrier is the initial step, which initiates a kind of “vicious circle” with dryness, itching and scratching, risk of super-infection and inflammation. The skin barrier function improvement offered by emollient products such as the Dr Michaels® (Eczitinex® and Itchinex®) ointment, is relevant in the long term management of AD especially considering that the

application of topical corticosteroid actually reduced skin barrier function with an increase in TEWL. This underlies the importance of a daily care treatment of skin in this clinical setting (16).

The antibacterial, anti-inflammatory, moisturizing and humectant agents contained in the Dr Michaels® (Eczitinex® and Itchinex®) range of topicals play an ameliorative role in replenishing the skin lipids lost during the wash period and results in a more rapid SC barrier repair.



The active ingredients in the Dr Michaels® (Eczitinex® and Itchinex®) ointment includes zinc oxide and various essential oils in a mineral oil base. The essential oils (including lavender oil, rosemary oil, jojoba oil, avocado oil and evening primrose oil) were selected based on their proven efficacy, specifically for AD. Lastly, the PSC 900 (5ml/ twice daily) is a zinc and folic acid based supplement and facilitates the improvement and maintenance of general wellbeing.

A limitation of this study is the relatively small sample. Twenty-eight patients showed a marked improvement in their condition within 6 days of treatment with most of the lesions and symptoms totally resolved within 10-12 weeks of treatment with Dr Michaels® (Eczitinex® and Itchinex®) family of products.

### CONCLUSION

This clinical report highlights that the Dr Michaels® (Eczitinex® and Itchinex®) product family is a safe and effective treatment option for AD.

### ACKNOWLEDGEMENTS

We gratefully acknowledge Tirsell Pty Ltd (Melbourne, Australia) and Frankl Pharma Global Ltd. (2 Parklands Place, Guilford, Surrey, United Kingdom) for providing the products for the studies.

### REFERENCES

1. Zeppa L, Bellini V, Lisi P. Atopic dermatitis in adults. *Dermatitis* 2011; 22(1):40-6.
2. Mrabet-Dahbi S, Maurer M. Innate immunity in atopic dermatitis. *Curr Probl Dermatol* 2011; 41:104-11.
3. Odhiambo JA, Williams HC, Clayton TO, Robertson CF, Asher MI; ISAAC Phase Three Study Group. Global variations in prevalence of eczema symptoms in children from ISAAC Phase Three. *J Allergy Clin Immunol* 2009; 124:1251-8.
4. Kanchongkittiphon W, Gaffin JM, Phipatanakul W. Child with atopic dermatitis. *Ann Allergy Asthma Immunol* 2015; 114(1):6-11.
5. Ong P. New insights in the pathogenesis of atopic dermatitis. *Pediatr Res* 2014; 75(1-2):171-5.
6. Ahmad-Nejad P, Mrabet-Dahbi S, Breuer K, et al. The toll-like receptor 2 R753Q polymorphism defines a subgroup of patients with atopic dermatitis having severe phenotype. *J Allergy Clin Immunol* 2004; 113(3):565-7.
7. Oh DY, Schumann RR, Hamann L, Neumann K, Worm M, Heine G. Association of the toll-like receptor 2 A-16934T promoter polymorphism with severe atopic dermatitis. *Allergy* 2009; 64:1608-15.
8. Niebuhr M, Heratizadeh A, Wichmann K, Satzger I, Werfel T. Intrinsic alterations of pro-inflammatory mediators in unstimulated and TLR-2 stimulated keratinocytes from atopic dermatitis patients. *Exp Dermatol* 2011; 20:468-72.
9. Bieber T. Atopic dermatitis. *N Engl J Med* 2008; 358(14):1483-94.
10. Chong M, Fonacier L. Treatment of eczema: corticosteroids and beyond. *Clin Rev Allergy Immunol* 2015; [Epub ahead of print].
11. Simon D, Bieber T. Systemic therapy for atopic dermatitis. *Allergy* 2014; 69(1):46-55.
12. Hanifin JM, Thurston M, Omoto M, Cherill R, Tofte SJ, Graeber M. The eczema area and severity index (EASI): assessment of reliability in atopic dermatitis. EASI Evaluator Group. *Exp Dermatol* 2001; 10(1):11-8.
13. Wiegand C, Hipler UC, Boldt S, Strehle J, Wollina U. Skin-protective effects of a zinc oxide-functionalized textile and its relevance for atopic dermatitis. *Clin Cosmet Investig Dermatol* 2013; 6:115-21.
14. Yun Y, Kim K, Choi I, Ko SG. Topical herbal application in the management of atopic dermatitis: a review of animal studies. *Mediators Inflamm* 2014; 2014:752103.
15. Williams MR, Gallo RL. The role of the skin microbiome in atopic dermatitis. *Curr Allergy Asthma Rep* 2015; 15(11):65.
16. Lynde CW, Andriessen A, Bertucci V, McCuaig C, Skotnicki S, Weinstein M, Wiseman M, Zip C. The skin microbiome in atopic dermatitis and its relationship to emollients. *J Cutan Med Surg* 2016; 20(1):21-8.



## TREATMENT OF ICHTHYOSIS LAMELLARIS USING A SERIES OF HERBAL SKIN CARE PRODUCTS FAMILY

M. TIRANT<sup>1</sup>, P. BAYER<sup>1</sup>, J. HERCOGOVÁ<sup>2,3</sup>, M. FIORANELLI<sup>4</sup>, S. GIANFALDONI<sup>5</sup>,  
A.A. CHOKOEVA<sup>6,7</sup>, G. TCHERNEV<sup>8</sup>, U. WOLLINA<sup>9</sup>, F. NOVOTNY<sup>10</sup>,  
M.G. ROCCIA<sup>11</sup>, G.K. MAXIMOV<sup>12</sup>, K. FRANÇA<sup>13,14</sup> and T. LOTTI<sup>15</sup>

<sup>1</sup>Psoriasis & Skin Clinic, Melbourne, Australia; <sup>2</sup>2nd Medical Faculty, Charles University, Bulovka Hospital, Prague, Czech Republic; <sup>3</sup>Institute of Clinical and Experimental Medicine, Prague, Czech Republic; <sup>4</sup>Department of Nuclear Physics, Sub-nuclear and Radiation, Guglielmo Marconi University, Rome, Italy; <sup>5</sup>Dermatological Department University of Pisa, Pisa, Italy; <sup>6</sup>“Onkoderma”-Polclinic for dermatology and dermatologic surgery, Sofia, Bulgaria; <sup>7</sup>Department of Dermatology and Venereology, Medical University of Plovdiv, Medical faculty, Plovdiv, Bulgaria; <sup>8</sup>Medical Institute of Ministry of Interior (MVR), Department of Dermatology, Venereology and Dermatologic Surgery, Sofia, Bulgaria; <sup>9</sup>Department of Dermatology and Allergology, Academic Teaching Hospital Dresden-Friedrichstadt, Dresden, Germany; <sup>10</sup>PRO SANUM Ltd, Sanatorium of Prof. Novotný, Štěpánská Prague 1, Czech Republic; <sup>11</sup>University B.I.S. Group of Institutions, Punjab Technical University, Punjab, India; <sup>12</sup>Department “Medicinal Information and Non-interventional studies”, Bulgarian Drug Agency; Sofia, Bulgaria; <sup>13</sup>Department of Dermatology & Cutaneous Surgery Department of Psychiatry & Behavioral Sciences Institute for Bioethics & Health Policy, University of Miami, Miller School of Medicine, Miami, FL, USA; <sup>14</sup>Centro Studi per la Ricerca Multidisciplinare e Rigenerativa, Università Degli Studi “G. Marconi”, Rome, Italy; <sup>15</sup>Chair of Dermatology, University of Rome “G. Marconi” Rome, Italy

Lamellar ichthyosis (LI) is a genetically heterogeneous group of disorders of keratinization that are inherited in an autosomal recessive fashion, occurring in approximately 1 in 300,000 live births. The treatment of the large, dark, plate-like scales that characterize the classic manifestation of the disease are still a challenge. The aim of this study was to evaluate the efficacy and tolerability of Dr. Michaels<sup>®</sup> skin-care products for the management of LI. A multi-centre European prospective study was conducted, including 10 patients (3 female/7 male) with lamellar ichthyosis, aged 38-54 years old (mean age: 46). Each patient had been treated with emollients plus other different systemic therapies, such as corticosteroids, Cyclosporin A or retinoids in the past. All patients were treated with Dr Michaels<sup>®</sup> product family including both topical and oral herbal supplements. The topical treatments used were the cleansing gel, activator formula and ointment. The oral medications were PSC 200, PSC 400 and PSC 900. Within 3 weeks of initiation of treatment, there were improvements observed on the skin including a reduction in scaling, fissuring, and intensity in erythema and pruritus with thinning of the hyperkeratotic plate. After 12-15 weeks, most of the plates and scales had been removed to reveal a normalised skin colour. Evidence of hair, eyelash and eyebrow growth was observed. There was partial nail resolution with a reduction in subungual hyperkeratosis. No adverse reactions were observed. Our patients showed excellent symptomatic response to treatment within a 14-week period, follow-up by an on-going regular assessment on a quarterly basis. The results show that Dr Michaels<sup>®</sup> product family is an effective and safe treatment option for IL.

Lamellar ichthyosis (LI) is a genetically heterogeneous group of disorders of keratinization that are inherited in an autosomal recessive fashion. LI has an equal incidence in male and

*Key words: Ichthyosis vulgaris, lamellar ichthyosis, erythroderma, hyperkeratosis, palmar, rhagades, ectropion, Collodion baby, Harlequin foetus.*

Mailing address:  
Professor Torello Lotti  
Chair of Dermatology,  
University of Rome “G. Marconi”,  
Rome, Italy  
e-mail: professor@torelloitti.it

female individuals and is estimated to occur in approximately 1 in 300,000 live births (1). The large, dark, plate-like scales that characterize classic LI represent one end of the phenotypic spectrum of autosomal recessive congenital ichthyosis (1). The erythroderma and fine, white scales, which typify nonbullous congenital ichthyosiform erythroderma (NBCIE), lie at the opposite end of this spectrum, and various intermediate phenotypes have been observed (1).

It has a genetic predisposition due to mutation on chromosomes Iq21 and Iq22 and is related mainly to an alteration in the synthesis of filaggrin (2). Filaggrin is an epidermal protein that normally functions as a barrier molecule against environmental allergens, water loss, and infection (2). Ichthyosis can be broadly divided into genetic, acquired and ichthyosis associated with various syndromes. The most common or well-known types are as follows<sup>2</sup>:

*Genetic ichthyoses:*

- Ichthyosis vulgaris
- X-linked ichthyosis
- Congenital ichthyosiform erythroderma (nbCIE)
- Epidermolytic hyperkeratosis (bullous ichthyosis, bCIE)
- Harlequin type ichthyosis
- Ichthyosis bullosa of Siemens
- Ichthyosis hystrix
- Ichthyosis lamellaris (lamellar ichthyosis)

*Non-genetic ichthyosis:*

- Ichthyosis acquisita
- Ichthyoses with syndromes
- KID (keratitis, ichthyosis, and deafness)
- CHIME (coloboma of the eye, heart defects, ichthyosiform dermatosis, mental retardation, and ear defects)
- Netherton syndrome (ichthyosis, erythroderma, hair shaft defects, atopic features)
- Sjögren-Larsson (ichthyosis, spastic diplegia, pigmentary retinopathy, and mental retardation)
- Refsum disease (ichthyosis and pigmentary retinopathy).

The clinical course of ichthyosis is highly variable. It cannot be cured but the symptoms can be controlled

and complications can be prevented with appropriate treatment. The aim of this study was to evaluate the efficacy and tolerability of Dr. Michaels® skin-care products for the management of LI.

## MATERIALS AND METHODS

We performed a multi-centre Australian and European prospective study. After obtaining written consent, 10 patients (3 female/7 male) with lamellar ichthyosis had been considered for testing the efficacy of Dr. Michaels® product family. Patients were aged 38-54 years old (mean age: 46) and presented ichthyosis since birth. In the past, each patient was treated with emollients plus other different therapies, such as systemic corticosteroids, Cyclosporin A or retinoids. Even if the different therapies conducted to good clinical results, their use was time-limited for side effects and patients showed a rebound of ichthyosis, feeling more depressed, dejected and lethargic.

Prior to starting the protocol study, patients did not perform any specific wash out. The clinical examination of the subjects revealed a generalized scaling and dryness all over the body including face and scalp. The scales were usually large in size, brown to black in colour, polygonal in shape and thick and adherent to skin.

In 5 patients, the palms and soles were affected with presence of hyperkeratosis and painful fissures. The nails were involved in 6 patients, with pitting, ridges, discolouration and subungual hyperkeratosis. Four patients had a scarring alopecia with thinning of hair; 3 patients showed eye changes, such as loss of eyelashes, ectropion of lower eyelids, congestion of conjunctiva, keratitis, and photophobia.

All patients were treated with Dr. Michaels® product family including both topical and oral herbal supplements. The topical treatments used were the cleansing gel, activator formula and ointment. The oral medications were PSC 200, PSC 400 and PSC 900.

The cleansing gel has keratolytic, anti-inflammatory and a weak antiseptic action. This reduces the thickening and scaling of the skin and clears up psoriasis plaques. The cleansing gel contains the keratolytic, salicylic acid. Salicylic acid is indicated as a topical aid in the removal of excessive keratin in hyperkeratotic skin disorders. The activator formula contains salicylic acid, glycolic, citric and acetic acids which are keratolytic agents that promote

shedding of the keratinized epithelial cells on the surface of the skin. The keratolytic agents also possess varying levels of antimicrobial activity, which contributes to their effectiveness. Keratolytic agents facilitate desquamation of the lesions by solubilizing the intercellular cement that binds scales in the stratum corneum, thereby loosening the keratin/epidermis and facilitating the penetration of other medicaments into the skin and produce their action against the skin lesion.

The ointment contains a synergistic blend including zinc oxide, castor oil, emu oil, essential oils in a petroleum jelly base. The ointment has anti-inflammatory properties and provides barrier repair while restoring skin lipid imbalances. Zinc is required for collagen and protein synthesis as low levels of zinc are associated with impaired wound healing. Zinc is also required for cellular growth and replication and may assist in wound healing by reducing free radical activity and inhibiting bacterial growth. Zinc serves as a cofactor in numerous transcription factors and enzyme systems including zinc-dependent matrix metalloproteinases that augment autodebridement and keratinocyte migration during wound repair. Zinc confers resistance to epithelial apoptosis through stabilizing cellular membranes, and cytoprotection against reactive oxygen species and bacterial toxins through antioxidant activity of the cysteine-rich metallothionines and superoxide dismutase (3). The constituent ingredients of this carefully blended formula, addresses the different factors that contribute to dry skin and restores epidermal differentiation. The essential oils and herbal extracts in topical ointment not only addresses the different factors that contribute to dry skin but also restores epidermal differentiation by restoring the lipid lamellae, improve skin hydration, skin elasticity and prevent itching.

The PSC 200 (2 tablets/twice daily) contains herbs including dandelion, echinacea, ginseng, licorice and astragalus, and acts as an anti-inflammatory, anti-bacterial and immune stimulating product. It was prescribed for the symptomatic relief and management of dry, flaking skin and its wound healing and skin renewal properties. It also inhibits prostaglandin synthesis through the inhibition of COX-1 and COX-2 and activates T-Cells and natural killer (NK) cells.

PSC 400 (2 tablets/twice daily) contains folic acid, cyanocobalamin–Vitamin B12, lecithin, alpha Lipoic Acid, and herbs including *Zingiber officinale* (Ginger),

*Scutellaria baicalensis* (Baical skullcap), *Silybum marianum* and *Bupleurum falcatum*. Lecithin also contains fatty acids, which are primarily omega-6 fatty acids and a small amount of omega-3 fatty acids. When taken orally, lecithin increases omega-6 fatty acid levels, but does not affect omega-3 levels (4).  $\alpha$ -Lipoic acid is a potent antioxidant in both fat- and water-soluble mediums. Its antioxidant activity extends to both the oxidized form and its reduced form dihydrolipoic acid (DHLA). DHLA is capable of regenerating ascorbic acid from dehydroascorbic acid, directly regenerating vitamin C and indirectly regenerating vitamin E3 (5). Ginger has been found to inhibit prostaglandin biosynthesis and interfere with the inflammatory cascade and the vanilloid nociceptor and has been shown to share pharmacological properties with non-steroidal anti-inflammatory drugs (NSAIDs) because it suppresses prostaglandin synthesis through the inhibition of cyclooxygenase-1 and cyclooxygenase-2. However, ginger can be distinguished from NSAIDs based on its ability to suppress leukotriene biosynthesis by inhibiting 5-lipoxygenase.

It was also discovered that a ginger extract (EV. EXT.77) derived from *Zingiber officinale* and *Alpinia galanga* inhibits the induction of several genes involved in the inflammatory response, including genes encoding cytokines, chemokines, and the inducible enzyme cyclooxygenase-2 (6). Whilst the PSC 900 (5ml/twice daily) containing zinc, pyridoxine hydrochloride (B6), folic acid and ferrous gluconate (iron) facilitates the normalization of dry skin.

## RESULTS

Within 3 weeks of initiation of treatment, there were improvements observed on the skin including a reduction in scaling, fissuring, and intensity in erythema and pruritus with thinning of the hyperkeratotic plate. After 12-15 weeks, most of the plates and scales had been removed to reveal a normalised skin colour. Evidence of hair, eyelash and eyebrow growth was observed after 20 weeks. There was partial nail resolution with a reduction in subungual hyperkeratosis. No adverse reactions were observed.

From continued treatment with topicals and oral supplementation over a 12-month period, the patients

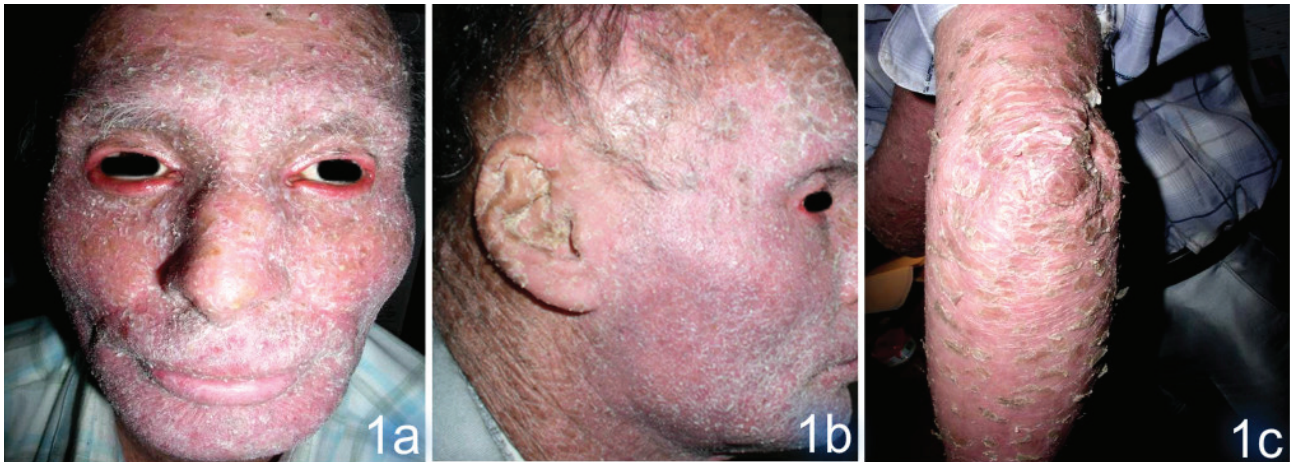
continue to improve. The patients were happier and more energetic.

### DISCUSSION

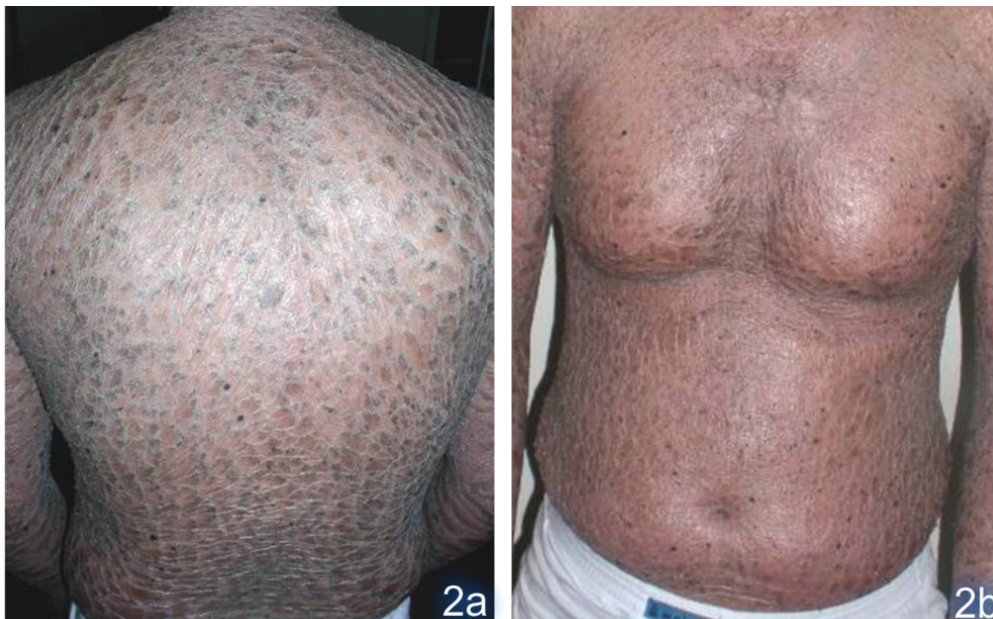The term ichthyosis derives from the ancient Greek root *ichthys*, meaning fish (7). IL is associated with a complex alteration bringing to deficiency

of the enzyme keratinocyte transglutaminase and mutation in genes TGM1, ABCA12, and CYP4F22 (8). The defective gene is located on an autosome, and both parents must carry one copy of the defective gene in order to have a child born with the disorder (2). Carriers of a recessive gene usually do not show any signs or symptoms of the disorder (2).

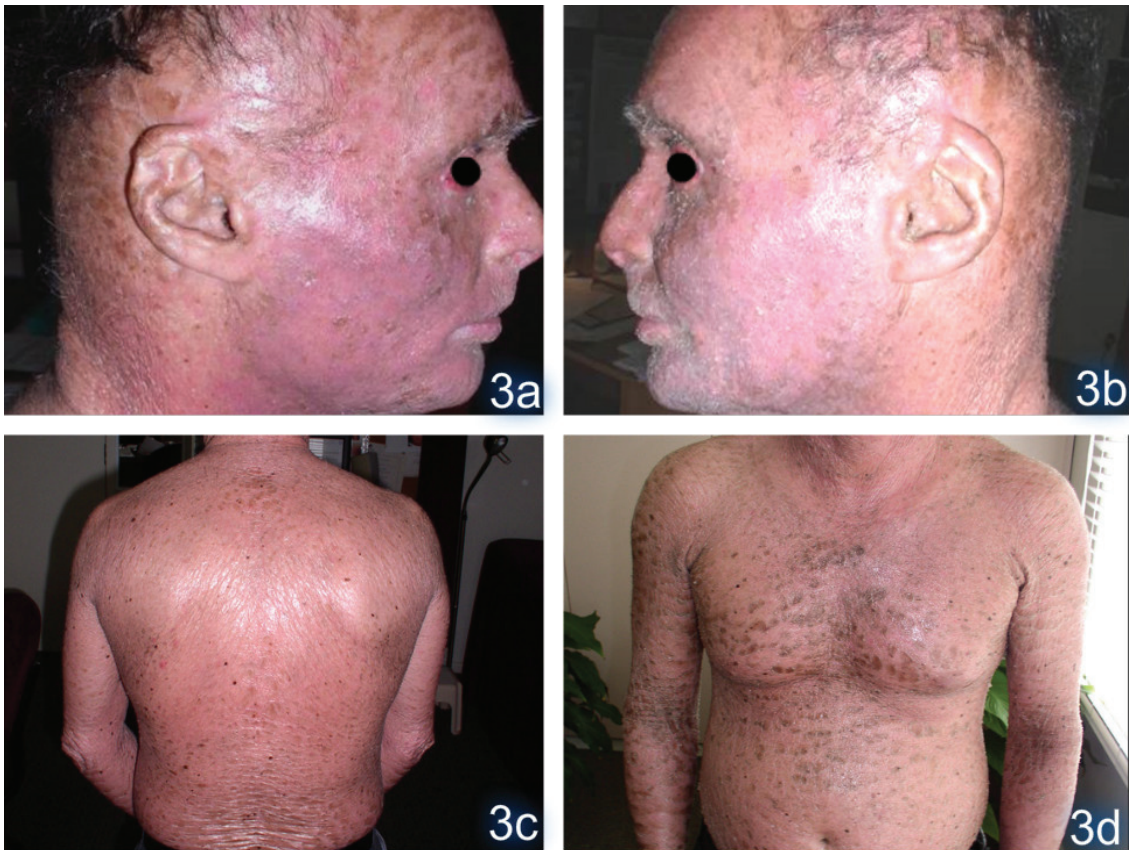
In seven cases, it presents as collodion baby soon



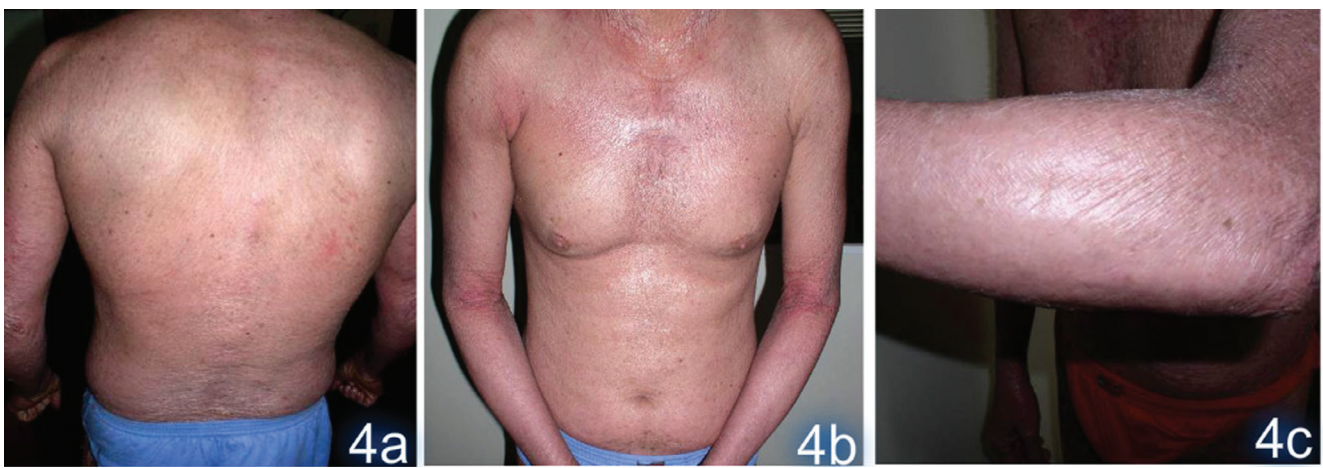
**Fig. 1. a):** Patient 1 Before treatment. Thick crusts and scales on an erythematous base all over the face with ectropion of eyelids and partial loss of eyelashes; **b):** Before treatment. The patient demonstrated thick crusting and scaling all over the face, ears and neck; **c):** Before treatment. Loose scales on an erythematous base over the arm.



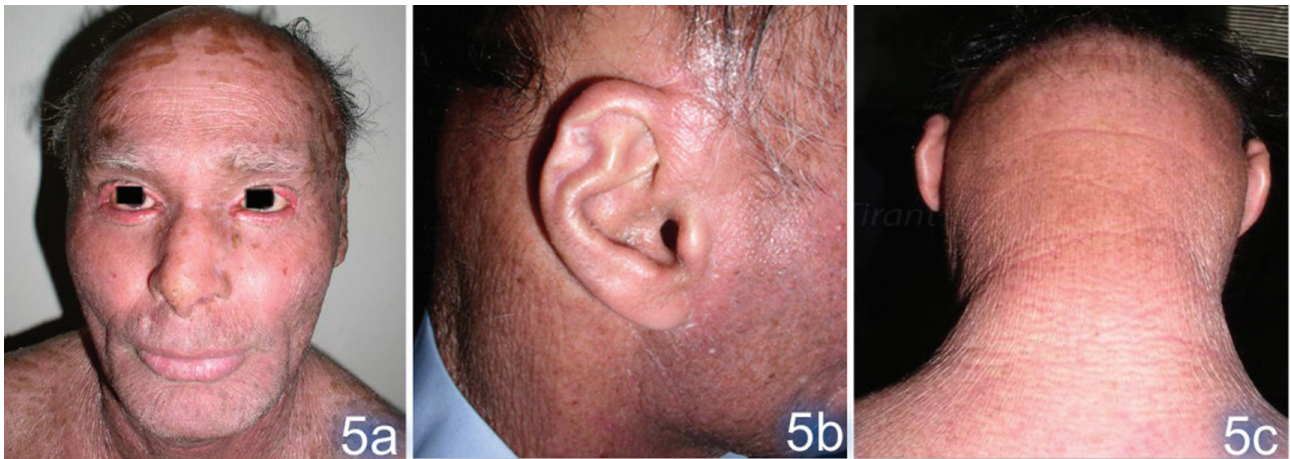**Fig. 2. a):** Patient 1. Before treatment. Thick fish-like scales over the neck, back and arms; **b):** Before treatment. Thick fish-like scales over the neck, chest and stomach.



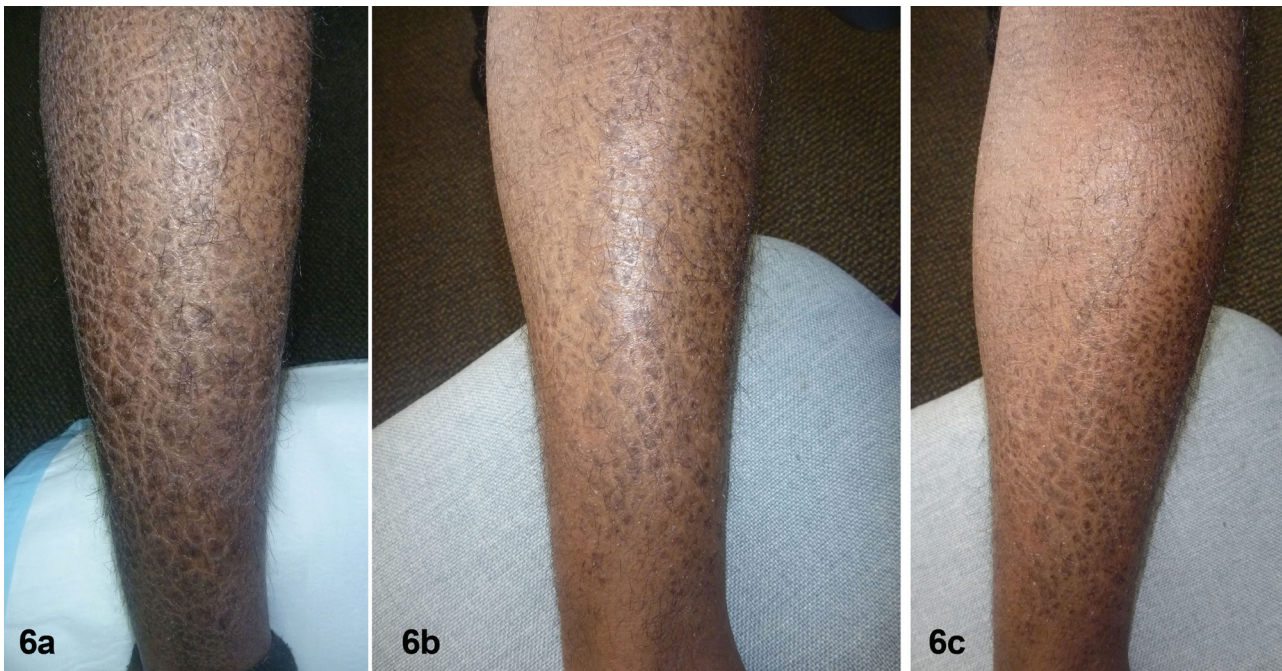**Fig. 3. a, b):** Patient 1. after 3 weeks of treatment with Dr. Michaels® product family. The patient demonstrated marked improvement over the face and neck. Note the significant reduction of scale within the ears; **c, d):** Patient 1. After 3 weeks of treatment with Dr. Michaels® product family. The patient showed significant improvement with the removal of all of the excessive scale and plaques.



**Fig. 4. a, b, c):** Patient 1 after 14 weeks of treatment with Dr. Michaels® product family. The patient demonstrates significant improvement with the removal of all of the excessive scale and plaques.

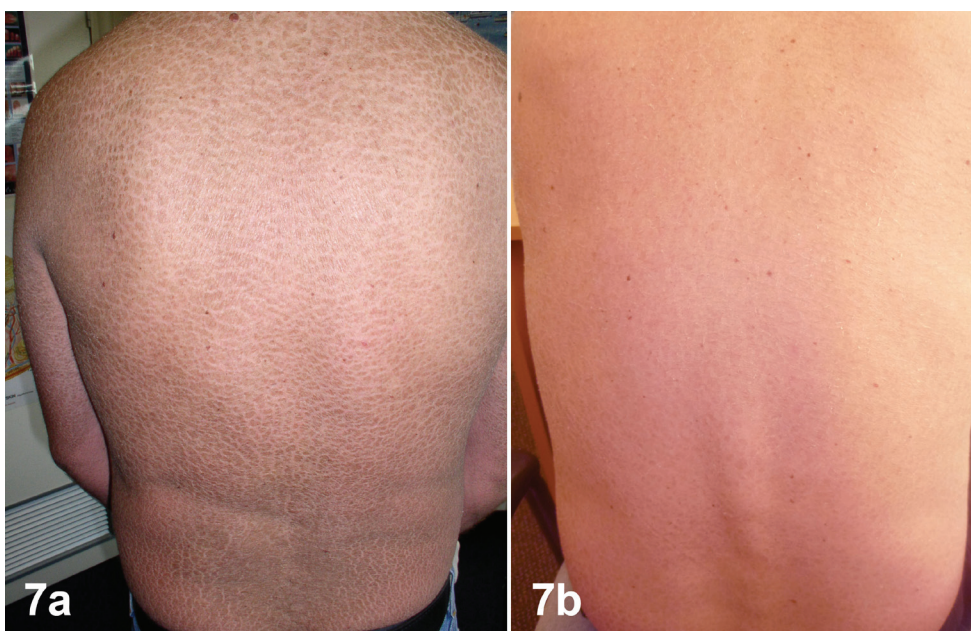


**Fig. 5. a):** Patient 1 after 14 weeks of treatment with Dr. Michaels® product family. The patient showed a significant decrease in crusts and scales over face. Partial resolution of the redness of the eyes and a reduction in the swelling of the upper and lower eyelids. Partial regrowth of upper eyelashes was also observed; **b, c):** After 14 weeks of treatment with the Dr. Michaels® product family, the patient showed a significant decrease in crusts and scales over and in the ears, neck and scalp. A partial regrowth of hair was also observed.



**Fig. 6. a):** Patient 2. Before treatment. Thick fish-like scales over the legs; **b):** after 3 weeks of treatment with the Dr. Michaels® product family the scale over the legs reduced. **c):** Further reduction seen in scale over the legs after 14 weeks of treatment with the Dr. Michaels® product family, with upper calf almost cleared.





**Fig. 7. a):** Patient 3. Before treatment. Slightly thickened fish-like scales over the back; **b):** After 14 weeks of treatment with the Dr. Michaels® product family. Only very fine scale now evident, some slight hypopigmentation remaining, skin almost has the appearance of being “normal”.

after birth, where whole foetal body is covered with a membrane which desquamates over 2-3 weeks of life. Less severe cases (approximately 75%) of collodion baby will go on to develop a type of autosomal recessive congenital ichthyosis (either LI or congenital ichthyosiform erythroderma (8)). In about 10% of cases, the baby sheds this layer of skin and has normal skin for the rest of its life. This is known as self-healing collodion baby (9).

Patients with LI have accelerated epidermal turnover which involves a mutation in the gene for enzyme transglutaminase 1 (TGM1). The TGM1 enzyme is involved in the formation of the cornified cell envelope, thus mutations in the TGM1 secondarily cause defects in the intercellular lipid layers in the stratum corneum, leading to defective barrier function of the stratum corneum and to the ichthyotic phenotype seen in lamellar ichthyosis patients (8, 10).

Generalized scales, which range from fine and white to thick, dark, and platelike (2), characterize the disease and they are arranged in a mosaic pattern resembling fish skin. The lesions involve the entire body and increase in flexural surfaces such as the axilla, groin, antecubital fossa and neck (2). The

individual scales tend to be larger over the legs and in some areas, are centrally attached and raised at the edges. Many patients show nail abnormalities, such as nail fold inflammation, subungual hyperkeratosis, and longitudinal or transverse stippling. The nails may grow 2-3 times the normal rate (2, 3).

Scarring alopecia may occur. It can result from the overall tightness of skin and the thick stratum corneum entrapping hairs. The hair may be thin and fine but similar to the nails, can grow at 2-3 times the normal rate (4). Diagnosis is made on the basis of clinical presentation and histopathology findings. Skin biopsy shows hyperkeratosis with increased mitoses, and a perivascular lymphocytic infiltrate. The stratum corneum shows compact hyperkeratosis. The granular layer is usually one-layer thick or absent (1). Our patients had LI and showed excellent symptomatic response with our treatment within a 14-week period, followed-up by an on-going regular assessment on a quarterly basis.

## CONCLUSIONS

The results show that Dr. Michaels® product family is an effective and safe treatment option for IL.

## ACKNOWLEDGEMENTS

We gratefully acknowledge Tirsell Pty Ltd (Melbourne, Australia) and Frankl Pharma Global Ltd (Surrey, UK) for providing the samples for the study.

## REFERENCES

1. Takeichi T, Akiyama M. Inherited ichthyosis: Non-syndromic forms. *J Dermatol* 2016; 43(3):242-51.
2. Kypriotou M, Huber M, Hohl D. The human epidermal differentiation complex: cornified envelope precursors, S100 proteins and the 'fused genes' family. *Exp Dermatol* 2012; 21(9):643-9.
3. Lansdown AB, Mirastschijski U, Stubbs N, Scanlon E, Agren MS. Zinc in wound healing: theoretical, experimental, and clinical aspects. *Wound Repair Regen* 2007; 15(1):2-16.
4. Lecithin; Natural Medicines Database; [www.naturaldatabase.com](http://www.naturaldatabase.com).
5. Firuzi O, Miri R, Tavakkoli M, Saso L. Antioxidant therapy: current status and future prospects. *Curr Med Chem* 2011; 18(25):3871-88.
6. Ahmad B, Rehman MU, Amin I, Arif A, Rasool S, Bhat SA, Afzal I, Hussain I, Bilal S, Mir Mu. A review on pharmacological properties of zingerone (4-(4-hydroxy-3-methoxyphenyl)-2-butanone). *ScientificWorldJournal* 2015; 2015:816364.
7. Van Gysel D, Lijnen RL, Moekti SS, de Laat PC, Oranje AP. Collodion baby: a follow-up study of 17 cases. *J Eur Acad Dermatol Venereol* 2002; 16(5):472-5.
8. Akiyama M, Shimizu H. An update on molecular aspects of the non-syndromic ichthyoses. *Exp Dermatol* 2008; 17(5):373-82.
9. Huber M, Rettler I, Bernasconi K, et al. Mutations of keratinocyte transglutaminase in lamellar ichthyosis. *Science* 1995; 267(5197):525-8.
10. Schwartz RA, Elston DM. Hereditary and Acquired Ichthyosis Vulgaris Workup; Available at: <http://emedicine.medscape.com/article/1112753-workup#c7>. Access on 05.26.2016.

## INVESTIGATION OF THE EFFICACY OF DR MICHAELS® (SORATINEX®) FAMILY IN MAINTAINING A SYMPTOM-FREE STATE FOR PATIENTS WITH PSORIASIS IN REMISSION. A RETROSPECTIVE, COMPARATIVE STUDY

J. HERCOGOVÁ<sup>1,2</sup>, M. FIORANELLI<sup>3</sup>, S. GIANFALDONI<sup>4</sup>, A.A. CHOKOEVA<sup>5,6</sup>,  
G. TCHERNEV<sup>7</sup>, U. WOLLINA<sup>8</sup>, M. TIRANT<sup>9</sup>, F. NOVOTNY<sup>10</sup>, M.G. ROCCIA<sup>11</sup>,  
G.K. MAXIMOV<sup>12</sup>, K. FRANÇA<sup>13,14</sup> and T. LOTTI<sup>15</sup>

<sup>1</sup>2nd Medical Faculty, Charles University, Bulovka Hospital, <sup>2</sup>Institute of Clinical and Experimental Medicine, Prague, Czech Republic; <sup>3</sup>Department of Nuclear Physics, Sub-nuclear and Radiation, G. Marconi University, Rome, Italy; <sup>4</sup>Dermatological Department University of Pisa, Pisa, Italy; <sup>5</sup>"Onkoderma"-Policlinic for dermatology and dermatologic surgery, Sofia, Bulgaria; <sup>6</sup>Department of Dermatology and Venereology, Medical University of Plovdiv, Medical faculty, Plovdiv, Bulgaria; <sup>7</sup>Medical Institute of Ministry of Interior (MVR), Department of Dermatology, Venereology and Dermatologic Surgery, Sofia, Bulgaria; <sup>8</sup>Department of Dermatology and Allergology, Academic Teaching Hospital Dresden-Friedrichstadt, Dresden, Germany; <sup>9</sup>Psoriasis & Skin Clinic, Melbourne, Australia; <sup>10</sup>PRO SANUM Ltd, Sanatorium of Prof. Novotný, Štěpánská Prague 1, Czech Republic; <sup>11</sup>University B.I.S. Group of Institutions, Punjab Technical University, Punjab, India; <sup>12</sup>Department "Medicinal Information and Non-interventional studies", Bulgarian Drug Agency, Sofia, Bulgaria; <sup>13</sup>Department of Dermatology & Cutaneous Surgery, Department of Psychiatry & Behavioral Sciences, Institute for Bioethics & Health Policy, University of Miami, Miller School of Medicine, Miami, FL, USA; <sup>14</sup>Centro Studi per la Ricerca Multidisciplinare e Rigenerativa, Università Degli Studi "G. Marconi", Rome, Italy; <sup>15</sup>Chair of Dermatology, University of Rome "G. Marconi" Rome, Italy

Psoriasis is a chronic inflammatory disease, affecting about 3% of the worldwide population. Although there are many therapeutic options available today for psoriasis, none of them can be considered as the gold standard treatment for maintaining a sustained period of remission. The aim of this study was to investigate whether a maintenance dosage of Michaels® Soratinex® product family is effective in maintaining a symptom-free state for patients in remission. Fifty patients (23 male, 27 female), aged 18-58-years-old (mean age: 38.3), affected by mild to severe plaque psoriasis (mean duration: 29.5), were included in this retrospective study. All of them had completed previous treatment and achieved remission. Twenty-eight had been previously treated with an Australian series of herbal skin-care products (Dr. Michaels® Soratinex® skincare products for psoriasis) and 22 treated with biologics. We evaluated the clinical condition of the member of each group every 4 weeks, for 16 times following remission. Maintenance group continued treatment with Dr Michaels® (Soratinex®). Non-Maintenance group discontinued both forms of treatment. The evaluation was based on the PASI score, assuming that at baseline it was zero. Out of 34 patients who continued treatment with Dr Michaels® (Soratinex®) product family in the Maintenance group (22 previously treated with Dr Michaels and 12 previously treated with Biologic), 26 remained symptom free with baseline PASI of zero. Six patients had a mild flare with a PASI increase of 0-25%. Two patients were in the moderate group with a PASI increase of 26-50% and were initially treated with biologic. Out of 6 patients in Dr Michaels non-maintenance group, 3 patients remained symptom free, 1 had a rebound starting on week 36 and 2 rebounded at week 44. Out of 10 patients who were in the non-maintenance from the biologic group, 6 rebounded

*Mailing address:*

Professor Jana Hercogová,  
2nd Medical Faculty, Charles University,  
Bulovka Hospital, Prague, Czech Republic  
e-mail: jana.hercogova@gmail.com

at week 12, 2 rebounded at week 16, 1 rebounded at week 24 and 1 rebounded at week 32. In the maintenance group no side effects were described, except for a mild form of folliculitis in 3 patients. Treatment did not have to be discontinued and all 3 patients cleared. Based on the results of this study, Dr. Michaels® (Soratinex®) product family can be safely and successfully applied to maintain a symptom-free state, after patients go into remission following treatment with Dr. Michaels® (Soratinex®) product family or biologics in mild to very severe psoriasis, when considering the exclusion criteria.

*Key words: psoriasis, treatment maintenance, Australian herbal skin-care products, symptom-free state, effectiveness, safety, patient satisfaction*

Psoriasis is a chronic inflammatory disease, affecting about the 3% of the worldwide population (1, 2). It is a T-cell mediated autoimmune inflammatory skin disease, characterized by cutaneous inflammation, hyperkeratosis, increased epidermal proliferation, angiogenesis and abnormal keratinization (3). Psoriasis is also associated with various co-morbidities resulting in socioeconomic costs and a decreased life expectancy (4, 5). Psychosomatic and stressful events play an important role in inducing or worsening psoriasis (6, 7, 8). Traditional systemic therapies for psoriasis can cause long-term toxicity and may not always provide sufficient treatment of the lesions (9, 10). Because the chronic recurrent course of the disease and profound effects on quality of life, it is fundamental to maintain a symptom-free state for patients (2, 11).

Many therapeutic options are available today for psoriasis (11), however, none of them can be considered the gold standard treatment for maintaining the period of remission.

The aim of this study was to investigate whether a maintenance dosage of Dr. Michaels® (Soratinex®) product family is effective in maintaining a symptom-free state for patients in remission.

## MATERIALS AND METHODS

This is a retrospective study, which was conducted in 50 patients (23 male, 27 female), aged 18-58 -years-old (mean age: 38.3). All the patients were affected by mild to severe plaque psoriasis (mean duration: 29.5), 28 patients had been previously treated with an Australian series of herbal skin-care products [Dr. Michaels® (Soratinex®) skin-care products for psoriasis] and 22 patients had been previously treated with biologics. All patients obtained complete remission of the lesions.

Out of 28 patients treated with Dr. Michaels® (Soratinex®) product family, 22 continued the triphasic application of Dr. Michaels® (Soratinex®) products (Cleansing Gel, Ointment and Skin Conditioner) two times per week (the first and fourth day of the week) on previously affected areas, on a maintenance dosage (Maintenance group) and 6 patients discontinued treatment (Non-maintenance group).

Out of 22 patients treated with biologics, 12 joined the Dr. Michaels Maintenance group and continued the triphasic application of Dr. Michaels® (Soratinex®) products (Cleansing Gel, Ointment and Skin Conditioner) two times per week (the first and fourth day of the week) on previously affected areas. Ten patients discontinued treatment.

We evaluated the clinical condition of the member of each group every 4 weeks, for 16 times (total 64 weeks). The evaluation was based on the PASI score, assuming that at baseline it was zero, using the following indicators:

- Symptom-free – PASI score same as baseline
- Mild – PASI increase 0-25%
- Moderate – PASI increase 26-50%
- Severe – PASI increase 51-75%
- Very Severe – PASI increase 76-100%

## RESULTS

The data presented here are the results for 50 patients over a 64-week period. Forty-six patients completed the study and 4 patients in the non-maintenance group (previously treated with biologics) discontinued, electing to seek further biologic treatment.

Out of 34 patients in Dr. Michaels® (Soratinex®) maintenance group [22 previously treated with Dr. Michaels® (Soratinex®) and 12 previously treated with Biologic], 26 remained symptom free with baseline PASI of zero. Six patients had a mild flare with a PASI increase of 0-25%. Two patients were

in the moderate group with a PASI increase of 26-50% and were initially treated with biologic. Out of 6 patients in Dr Michaels® (Soratinex®) non-maintenance group, 3 patients remained symptom free, 1 had a rebound starting on week 36 and 2 rebounded at week 44. Out of 10 patients who were in the biologic non-maintenance group, 6 rebounded at week 12, 2 rebounded at week 16, 1 rebounded at week 24 and 1 rebounded at week 32.

In the Dr Michaels® (Soratinex®) maintenance group, no side effects were observed except for a mild form of folliculitis in 3 patients starting from week 48. Treatment was not discontinued and all 3 patients cleared.

### DISCUSSION

The results show that Dr Michaels® (Soratinex®) product family can maintain a symptom free state after remission, both in patients who have been treated with Dr Michaels® (Soratinex®) product family and more importantly, in those who have been treated with biologics. As biologic treatment is very expensive, although effective, there is normally a rebound reaction after 3-4 months on cessation of treatment. To increase the benefits following remission from biologic treatment, there is an opportunity for patients to go on a maintenance program using Dr Michaels® (Soratinex®) product family to extend their symptom free state and have longterm benefits. In this perspective, we suggest that Soratinex® should be used in combination treatment with systemic therapy of psoriasis (including biological treatment) and continued after the withdrawal of the systemic treatment. According to our data, we envision a very safe and effective combination treatment approach.

### CONCLUSION

This study concludes that the Dr Michaels® (Soratinex®) product family can be safely and successfully applied to maintain a symptom-free state, after patients go into remission following treatment with Dr Michaels® (Soratinex®) topicals or biologics, in mild to very severe psoriasis when considering the exclusion criteria.

### ACKNOWLEDGEMENTS

We gratefully acknowledge Tirsell Pty Ltd (Melbourne, Australia) and Frankl Pharma Global Ltd. (2 Parklands Place, Guilford, Surrey, United Kingdom) for providing the products for the studies.

### REFERENCES

1. Meier M, Sheth PB. Clinical spectrum and severity of psoriasis. *Curr Probl Dermatol* 2009; 38:1-20.
2. Naldi L. Epidemiology of psoriasis. *Curr Drug Targets Inflamm Allergy* 2004; 3(2):121-8.
3. Weger W. Current status and new developments in the treatment of psoriasis and psoriatic arthritis with biological agents. *Br J Pharmacol*. 2010; 160(4):810-20.
4. Vena GA, Altomare G, Ayala F, et al. Incidence of psoriasis and association with comorbidities in Italy: a 5-year observational study from a national primary care database. *Eur J Dermatol* 2010; 20(5):593-8.
5. Prignano F, Ruffo G, Ricceri F, Pescitelli L, Lotti T. A global approach to psoriatic patients through PASI score and Skindex-29. *G Ital Dermatol Venereol* 2011; 146(1):47-52.
6. Dubertret L, Mrowietz U, Ranki A, van de Kerkhof PC, Chimenti S, Lotti T, Schäfer G. EUROPSO Patient Survey Group. European patient perspectives on the impact of psoriasis: the EUROPSO patient membership survey. *Br J Dermatol* 2006;155(4):729-36.
7. Campolmi E, Zanieri F, Santosuosso U, D'Erme AM, Betti S, Lotti T, Cossidente A. The importance of stressful family events in psoriatic patients: a retrospective study. *J Eur Acad Dermatol Venereol* 2012; 26 10):1236-9.
8. França K, Chacon A, Ledon J, Savas J, Nouri K. Psychodermatology: a trip through history. *Anais Brasileiros de Dermatologia* 2013; 88(5):842-3.
9. Edlich RF, Fisher AL, Chase ME, Brock CM, Gubler KD, Long WB 3rd. Modern concepts of the diagnosis and treatment of psoriasis. *J Environ Pathol Toxicol Oncol* 2009; 28(3):235-40.
10. Salgo R, Thaçi D. Treatment of moderate-to-severe plaque psoriasis. *G Ital Dermatol Venereol* 2009; 144(6):701-11.
11. Scarpa R, Altomare G, Marchesoni A, et al. Psoriatic disease: concepts and implications. *J Eur Acad Dermatol Venereol* 2010; 24(6):627-30.



## DR MICHAELS<sup>®</sup> PRODUCT FAMILY (ALSO BRANDED AS SORATINEX<sup>®</sup>) VERSUS METHYLPREDNISOLONE ACEPONATE- A COMPARATIVE STUDY OF THE EFFECTIVENESS FOR THE TREATMENT OF PLAQUE PSORIASIS

J. HERCOGOVÁ<sup>1,2</sup>, M. FIORANELLI<sup>3</sup>, S. GIANFALDONI<sup>4</sup>, A.A. CHOKOEVA<sup>5,6</sup>,  
G. TCHERNEV<sup>7</sup>, U. WOLLINA<sup>8</sup>, M TIRANT<sup>9</sup>, F.NOVOTNY<sup>10</sup>, M.G.ROCCIA<sup>11</sup>,  
G.K. MAXIMOV<sup>12</sup>, K. FRANÇA<sup>13,14</sup>, and T. LOTTI<sup>15</sup>

<sup>1</sup>2nd Medical Faculty, Charles University, Bulovka Hospital, <sup>2</sup>Institute of Clinical and Experimental Medicine, Prague, Czech Republic; <sup>3</sup>Department of Nuclear Physics, Sub-nuclear and Radiation, G. Marconi University, Rome, Italy; <sup>4</sup>Dermatological Department University of Pisa, Pisa, Italy; <sup>5</sup>"Onkoderma"-Policlinic for dermatology and dermatologic surgery, Sofia, Bulgaria; <sup>6</sup>Department of Dermatology and Venereology, Medical University of Plovdiv, Medical faculty, Plovdiv, Bulgaria; <sup>7</sup>Medical Institute of Ministry of Interior (MVR), Department of Dermatology, Venereology and Dermatologic Surgery, Sofia, Bulgaria; <sup>8</sup>Department of Dermatology and Allergology, Academic Teaching Hospital Dresden-Friedrichstadt, Dresden, Germany; <sup>9</sup>Psoriasis & Skin Clinic, Melbourne, Australia; <sup>10</sup>PRO SANUM Ltd., Sanatorium of Prof. Novotný, Štěpánská Prague 1, Czech Republic; <sup>11</sup>University B.I.S. Group of Institutions, Punjab Technical University, Punjab, India; <sup>12</sup>Department of Medicinal Information and Non-interventional studies, Bulgarian Drug Agency, Sofia, Bulgaria; <sup>13</sup>Department of Dermatology & Cutaneous Surgery, Department of Psychiatry & Behavioral Sciences, Institute for Bioethics & Health Policy, University of Miami, Miller School of Medicine, Miami, FL, USA; <sup>14</sup>Centro Studi per la Ricerca Multidisciplinare e Rigenerativa, Università Degli Studi "G. Marconi", Rome, Italy; <sup>15</sup>Chair of Dermatology, University of Rome "G.Marconi" Rome, Italy

As one of the most common dermatologic chronic-recurrent disease, variable therapeutic options are available today for management of psoriasis. Although topical high potency corticosteroids, alone or in association with salicylic acid or vitamin D analogues, are still considered the best treatment, they do not seem to possess the capability for a long-term control of the disease or prevent recurrences, as their side effects are major contraindications for continuative use. The aim of this study was to investigate whether Dr. Michaels<sup>®</sup> product family is comparable to methylprednisolone aceponate (MPA) as a viable alternative treatment option for the treatment and management of stable chronic plaque psoriasis. Thirty adults (13 male, 17 female, mean age 40 years) with mild to severe stable chronic plaque psoriasis, were included in the study. Patients were advised to treat the lesions of the two sides of their body (left and right) with two different unknown modalities for 8 weeks; the pack of Dr. Michaels<sup>®</sup> products on the left side (consisting of a cleansing gel, an ointment and a skin conditioner) and a placebo pack on the right side, consisting of a cleansing gel, methylprednisolone ointment and a placebo conditioner. Assessment was done using the Psoriasis Activity Severity Index (PASI) scores before treatment and after 2, 4, 6 and 8 weeks. The results achieved with the Dr. Michaels<sup>®</sup> (Soratinex<sup>®</sup>) product family for the treatment of chronic plaque psoriasis were better than the results achieved with methylprednisolone aceponate (MPA), even though quicker resolution was achieved with the steroid with 45% of patients achieving resolution within 8-10 days in comparison to 5-6 weeks in the Dr. Michaels<sup>®</sup> (Soratinex<sup>®</sup>) group. Before therapy, the mean PASI score of the LHS in Dr. Michaels<sup>®</sup> (Soratinex<sup>®</sup>) group was 13.8±4.1 SD and 14.2±4.2 SD in the RHS methylprednisolone aceponate (MPA) group.

Mailing address:

Professor Torello Lotti,  
Department of Dermatology,  
University of Rome "G. Marconi",  
Rome, Italy  
e-mail: professor@torellolotti.it

0393-974X (2016)

Copyright © by BIOLIFE, s.a.s.

This publication and/or article is for individual use only and may not be further reproduced without written permission from the copyright holder.

Unauthorized reproduction may result in financial and other penalties  
DISCLOSURE: ALL AUTHORS REPORT NO CONFLICTS OF INTEREST RELEVANT TO THIS ARTICLE.

**After 8 weeks of treatment 62% of the Dr. Michaels® (Soratinex®) group had achieved resolution whilst in the methylprednisolone aceponate (MPA) group, the figure remained at 45%. The mean PASI score after 8 weeks of treatment was calculated and in the LHS Dr. Michaels® (Soratinex®) group it was  $2.8 \pm 1.6$  SD and  $6.8 \pm 2.4$  SD in the RHS methylprednisolone aceponate group. In the RHS -methylprednisolone aceponate (MPA) group, 22% of patients failed to respond to the treatment in comparison to 6% in the LHS Dr. Michaels® (Soratinex®) group. Based on the results of this study, Dr. Michaels® products are a more effective treatment option, with insignificant side effects, compared to local treatment with methylprednisolone aceponate (MPA).**

*Key words: plaque psoriasis, alternative treatment, methylprednisolone aceponate, Dr. Michaels® (Soratinex®) products, comparative study*

Psoriasis is a chronic skin disorder characterized by autoinflammatory features and severe association with other comorbid conditions such as cardiovascular, metabolic, inflammatory bowel disease, ocular and psychological disorders (1, 2, 3). It is a T cell-mediated autoimmune disease of skin and joints, affecting 1-3% of the world population. The pathogenesis includes genetic susceptibility, environmental factors and innate immune response (3). Psychological factors play an important role, triggering or worsening the disease (4, 5). Due to intensive research and cooperation between academia and pharmaceutical industry, there was an increase in the number of psoriasis treatment options in the past years (6). Many therapeutic options are nowadays available, however, topical high potency corticosteroids, alone or in association with salicylic acid or vitamin D analogues, are still considered the best treatment for mild to moderate cases (7). This approach is effective in a large percentage of patients, yet does not seem to possess the capability for a long-term control of the disease, does not prevent the recurrences or the event of tachyphylaxis, while the side effects are major contraindications for its continuative use (8). The development of novel therapies are needed to provide efficient treatment of psoriatic lesions (9, 10). This study aims to investigate whether Dr. Michaels® (Soratinex®) product family is comparable to methylprednisolone aceponate (MPA) as a viable alternative treatment option for the treatment and management of stable chronic plaque psoriasis.

## MATERIALS AND METHODS

The study was conducted in 30 Chinese adults (13

male, 17 female) with a mean age of 40 years old. All the patients had mild to severe stable chronic plaque psoriasis, previously treated with different therapeutic options. Exclusion criteria were severe psoriasis, arthropathic psoriasis, intertriginous psoriasis, palmoplantar psoriasis, use of any antipsoriatic treatment modality and any medication, which may influence or interfere with the course of the disease.

After obtaining written consent, patients were advised to treat the lesions of the two side of their body (left and right) with two different modalities for 8 weeks. They did not know the composition of the drugs.

On the left side, patients had to use the pack of Dr Michaels® (Soratinex®) products (marked as LHS), consisting in a cleansing gel, an ointment and a skin conditioner. The characteristics of the products are presented in table I.

On the right side, they had to use a pack (marked as RHS) consisting in a placebo cleansing gel, methylprednisolone ointment and a placebo conditioner. Patients were instructed to use the two packs two times a day, taking great care when applying each product.

Assessment, using the Psoriasis Activity Severity Index (PASI) scores (Table II), was done before treatment and after 2, 4, 6 and 8 weeks.

## RESULTS

The results achieved with the Dr. Michaels® (Soratinex®) product family for the treatment of chronic plaque psoriasis were better than the results achieved with methylprednisolone aceponate (MPA), even though quicker resolution was achieved with the steroid with 45% of patients achieving resolution within 8-10 days in comparison to 5-6 weeks in the Dr. Michaels® (Soratinex®) group.



**Table I.** Characteristics of the Tested Products Dr Michaels® (Soratinex®).

PRODUCT	HOW TO APPLY	EFFECT	ACTIVE INGREDIENTS
Dr Michaels® (Soratinex®) Scalp and Body Cleansing Gel	<ul style="list-style-type: none"> <li>• Applied before the use of the ointment</li> <li>• Scalp: Wet scalp and apply a small amount of cleansing gel.</li> <li>• Massage thoroughly and leave for 2-3 minutes. Wash off with lukewarm water.</li> <li>• Body: Wet body and apply small amount of cleansing gel to the psoriatic plaques. Leave for 2-3 minutes then rinse off with lukewarm water.</li> </ul>	Decreases parakeratosis	<ul style="list-style-type: none"> <li>• Salicylic acid</li> <li>• Citric acid</li> <li>• Glycolic acid</li> </ul>
Dr Michaels® (Soratinex®) Scalp and Body Ointment	Applied to the psoriatic plaques of the scalp and body after using and washing off the cleansing gel	Decreases inflammation and infiltration	<ul style="list-style-type: none"> <li>• Paraffinum liquidum</li> <li>• Paraffinum solidum</li> <li>• Solanum tuberosum</li> <li>• Zinc oxide</li> <li>• Salicylic acid</li> <li>• Prunus amygdalus dulcis oil</li> <li>• Simmondsia chinensis oil</li> <li>• Persea gratissima oil</li> <li>• Daucus carota oil</li> <li>• Calendula officinalis extract</li> <li>• Citrus sinensis oil</li> <li>• Triticum vulgare germ oil</li> <li>• Prunus armeniaca kernel oil</li> <li>• Lavendula augustifolia</li> <li>• Santalum album oil</li> <li>• Pogostemon cablin oil</li> <li>• Pelargonium graveolens</li> <li>• Rosemary officinalis extract</li> <li>• Dromiceius oil</li> <li>• Citrus aurantium SSP bergamia oil</li> <li>• Pinus sylvestris leaf oil</li> <li>• Chamomilla recutita oil</li> <li>• Commiphora myrrha oil</li> <li>• Citrus aurantium amara flower oil</li> </ul>
Dr Michaels® (Soratinex®) Skin Conditioner	Applied to the psoriatic plaques two minutes after using the ointment (without washing it off)	Improves flexibility and elasticity of the skin	<ul style="list-style-type: none"> <li>• Olive oil,</li> <li>• Sesame seed oil</li> <li>• Emu oil</li> <li>• Lavender oil</li> <li>• Eucalyptus oil</li> <li>• Natural vitamin E</li> </ul>

**Table II.** PASI assessment.

Score	0	1	2	3	4		
Erythema	0 = none	1 = mild	2 = moderate	3 = severe	4 = very severe		
Infiltration	0 = none	1 = mild	2 = moderate	3 = severe	4 = very severe		
Parakeratosis	0 = none	1 = mild	2 = moderate	3 = severe	4 = very severe		
Score	0	1	2	3	4	5	6
Area %	0	>10	10<30	30<50	50<70	70<90	90<100

Before therapy, the mean PASI score of the LHS–Dr. Michaels® (Soratinex®) group was 13.8±4.1 SD and 14.2±4.2 SD in the RHS-methylprednisolone aceponate (MPA) group (table IIIa, IIIb).

After 8 weeks of treatment, 62% of the Dr. Michaels® (Soratinex®) group had achieved resolution whilst in the methylprednisolone aceponate (MPA) group the figure remained at 45%. The mean PASI score after 8 weeks of treatment was calculated and in the LHS–Dr. Michaels® (Soratinex®) group it was 2.8±1.6 SD and 6.8±2.4 SD in the RHS-methylprednisolone aceponate group. In the RHS -methylprednisolone aceponate (MPA) group, 22% of patients failed to respond to the treatment in comparison to 6% in the LHS–Dr. Michaels® (Soratinex®) group.

#### DISCUSSION

Topical corticosteroids are considered the first approach to the treatment of cutaneous psoriasis in

large areas of the scientific community. The potential risks of topical corticosteroids can be avoided when other alternatives with less side effects are available. This study evaluated the efficacy of a herbal-based remedy topical treatment for mild to moderate psoriasis compared to methylprednisolone aceponate. Dr Michaels® product family (also branded as Soratinex®) showed to be a viable, safe and effective alternative treatment option for the treatment and management of stable chronic plaque psoriasis.

#### CONCLUSION

Dr Michaels® (Soratinex®) products are a more effective and safer treatment option, with minimal side effects, compared to methylprednisolone aceponate (Advantan®). The large psoriasis population with mild-to-moderate cases deserves safe and effective topical agents with less side effects and long-lasting clinical efficacy.

**Table IIIa.** Comparative results of the improvement of psoriasis achieved by Dr. Michaels® (Soratinex®) products (LHS) and methylprednisolone aceponate (RHS).

RESULTS	LHS (Dr Michaels®)	RHS (MPA)
Total Resolution	62%	45%
75% Improvement	17%	22%
50% Improvement	7%	2%
Minimal or No Improvement	6%	22%
Non-Compliant &/or discontinued	6%	5%

**Table IIIb.** comparative reductions of the PASI score in the two investigative treated body sides.

RESULTS	LHS (Dr Michaels)	RHS (MPA)
Mean reduction in PASI Scores from Week 0 to Week 8	79%	53%

#### ACKNOWLEDGEMENTS

We gratefully acknowledge Tirsell Pty Ltd (Melbourne, Australia) and Frankl Pharma Global Ltd. (2 Parklands Place, Guilford, Surrey, United Kingdom) for providing the products for the studies.

#### REFERENCES

- Schäkel K, Schön MP, Ghoreschi K. (Pathogenesis of psoriasis). *Hautarzt* 2016.
- Rivas Bejarano JJ, Valdecantos WC. Psoriasis as autoinflammatory disease. *Dermatol Clin* 2013; 1(3):445-60.
- Prignano F, Tripo L, Amato L, et al. Tuscany consensus for the diagnosis, treatment and follow-up of moderate-to-severe psoriasis. *G Ital Dermatol Venereol* 2015.
- Campolmi E, Zanieri F, Santosuosso U, D'Erme AM, Betti S, Lotti T, Cossidente A. The importance of stressful family events in psoriatic patients: a retrospective study. *J Eur Acad Dermatol Venereol* 2012; 26(10):1236-9.
- França K, Chacon A, Ledon J, Savas J, Nouri K. Psychodermatology: a trip through history. *Anais Brasileiros de Dermatologia* 2013;8(5):842-3.
- Philipp S, Kokolakis G, Sabat R. [Systemic treatments for psoriasis and psoriatic arthritis]. *Hautarzt* 2016.
- Laws PM, Young HS. Topical treatment of psoriasis. *Expert Opin Pharmacother* 2010; 11(12):1999-2009.
- Tempark T, Phatarakijnurund V, Chatproedprai S, Watcharasindhu S, Supornsilchai V, Wananukul S. Exogenous Cushing's syndrome due to topical corticosteroid application: case report and review literature. *Endocrine* 2010; 38(3):328-34.
- Weger W. Current status and new developments in the treatment of psoriasis and psoriatic arthritis with biological agents. *Br J Pharmacol* 2010; 160(4):810-20.
- Tempark T, Phatarakijnurund V, Chatproedprai S, Watcharasindhu S, Supornsilchai V, Wananukul S. Exogenous Cushing's syndrome due to topical corticosteroid application: case report and review literature. *Endocrine* 2010; 38(3):328-34.



## SUCCESSFUL TREATMENT OF ALOPECIA AREATA WITH DR. MICHAELS® (ALOPINEX) PRODUCT FAMILY

U. WOLLINA<sup>1</sup> J. HERCOGOVÁ<sup>2,3</sup>, M. FIORANELLI<sup>4</sup>, S. GIANFALDONI<sup>5</sup>, A.A. CHOKOEVA<sup>6,7</sup>,  
G. TCHERNEV<sup>8</sup>, M. TIRANT<sup>9</sup>, F. NOVOTNY<sup>10</sup>, M.G. ROCCIA<sup>11</sup>,  
G.K. MAXIMOV<sup>12</sup>, K. FRANÇA<sup>13,14</sup> and T. LOTTI<sup>15</sup>

<sup>1</sup>Department of Dermatology and Allergology, Academic Teaching Hospital Dresden-Friedrichstadt, Dresden, Germany; <sup>2</sup>2nd Medical Faculty, Charles University, Bulovka Hospital, <sup>3</sup>Institute of Clinical and Experimental Medicine, Prague, Czech Republic; <sup>4</sup>Department of Nuclear Physics, Sub-nuclear and Radiation, G. Marconi University, Rome, Italy; <sup>5</sup>Dermatological Department University of Pisa, Pisa, Italy; <sup>6</sup>“Onkodermat”-Policlinic for Dermatology and Dermatologic Surgery, Sofia, Bulgaria; <sup>7</sup>Department of Dermatology and Venereology, Medical University of Plovdiv, Medical faculty, Plovdiv, Bulgaria; <sup>8</sup>Medical Institute of Ministry of Interior (MVR), Department of Dermatology, Venereology and Dermatologic Surgery, Sofia, Bulgaria; <sup>9</sup>Psoriasis & Skin Clinic, Melbourne, Australia; <sup>10</sup>PRO SANUM Ltd, Sanatorium of Prof. Novotný, Štěpánská Prague 1, Czech Republic; <sup>11</sup>University B.I.S. Group of Institutions, Punjab Technical University, Punjab, India; <sup>12</sup>Department “Medicinal Information and Non-interventional studies”, Bulgarian Drug Agency; Sofia, Bulgaria; <sup>13</sup>Department of Dermatology & Cutaneous Surgery, Department of Psychiatry & Behavioral Sciences, Institute for Bioethics & Health Policy, University of Miami, Miller School of Medicine, Miami, FL, USA; <sup>14</sup>Centro Studi per la Ricerca Multidisciplinare e Rigenerativa, Università Degli Studi “G. Marconi”, Rome, Italy; <sup>15</sup>Chair of Dermatology, University of Rome “G. Marconi” Rome, Italy

**Alopecia areata is a highly prevalent organ restricted autoimmune disorder that leads to disfiguring hair loss and is thought to involve a T cell-mediated response to the hair follicle. The treatment of alopecia areata is often problematic and very frustrating, partly due to the unknown aetiology of the condition. The aim of this study was to evaluate the efficacy and tolerability of complementary medicine, Dr. Michaels® product family, in the treatment of alopecia areata. Materials and methods: 40 patients (27 female/13 male), with a mean age of 20.3 years, all of them with 1-3 lesions of stable alopecia areata localized on the scalp were included in this trial. Four patients suffered from Hashimoto thyroiditis, and one had a familial history of LES. Exclusion criteria were the use of any treatment or medication, which may influence or interfere with the course of the disease. All patients were treated with Dr. Michaels® StimOils - applied twice daily (morning and night), Hair Lotion – applied twice daily (morning and night), and oral herbal formulation - PSC 900 2ml twice daily with food for 16 weeks. For each patient, photographs of typical lesions were taken at the beginning, and 4, 8, 12 and 16 weeks follow-up. Patient improvement was determined by the percentage of hair regrowth for each lesion. Results: After 10 weeks of treatment using StimOils, Hair Lotion and PSC 900 from Dr. Michaels® product family, 18 patients had achieved an excellent response with regrowth in all the affected alopecia areata patches. 17 patients achieved the same results after 12 weeks of treatment; the other 5 patients had to continue the therapeutic protocol for another 2-3 weeks. Conclusion: This study demonstrates that the Dr. Michaels® StimOils, Hair Lotion and PSC 900 are an effective therapeutic option for the treatment of alopecia areata. This has important implications for resistant cases of alopecia areata where traditional systemic and topical corticosteroid therapies have failed. In addition, this treatment approach may be an attractive option for patients who have growing concern regarding side-effects of long-term corticosteroid therapy.**

*Key words: alopecia areata, pathogenesis, treatment, Dr. Michaels® products*

Mailing address:  
Professor Torello Lotti,  
Department of Dermatology,  
University of Rome “G. Marconi”,  
Rome, Italy  
e-mail: professor@torellolotti.it

*Alopecia areata* is a highly prevalent organ restricted autoimmune disorder that leads to disfiguring hair loss and is thought to involve a T cell-mediated response to the hair follicle (1). The lifetime incidence is about 2% worldwide. Alopecia areata is often associated with significant psychological distress, particularly in children and teenagers where sudden and widespread scalp hair loss (alopecia areata totalis), or complete body hair loss (*alopecia areata universalis*) can cause negative effects on not only the quality of life but also on psychoemotional and psychosocial parameters (1, 2).

The pathogenesis of alopecia areata is yet to be fully elucidated, however, to date it is thought to be an autoimmune disorder on a genetic background. A critical step in this process is the breakdown of the natural immune privilege of hair follicles followed by exposure of autoantigens and MHC class I molecules. This will activate autoreactive CD8-positive lymphocytes. The autoimmune cascade is further mediated by proinflammatory substances like interferon-gamma or interleukin-15, which are signalling by the Janus kinase pathway (3). This can also lead to extreme oxidative stress (4).

New genetic findings have been generated by the human genome project. A number of genes could be identified which are either unique to the hair follicle or are regulating immune functions such as *cytotoxic T-lymphocyte-associated protein 4*, *IL-2/IL-21*, *ULBP* gene cluster, or *syntaxin-17* (5).

AA is characterised by isolated, round areas of complete hair loss without clinical signs of skin inflammation or scarring (1, 2). The disease onset occurs abruptly with one or more multiple patches of hair loss that usually enlarge in a centrifugal manner. Generally, the scalp is the most common site affected; however, any hair bearing skin may be affected by this condition. The extent and location of alopecia can vary greatly between patients and within individuals over time. A pathognomonic sign is the “exclamation mark” hair, this term describes a broken hair that is thicker towards the distal end and thinner at the base, usually found at the edge of an active area of hair loss (1, 2). Nail changes such as pitting are occasionally observed in alopecia areata patients (1).

The treatment of alopecia areata is often problematic and very frustrating. Current evidence-based guidelines for the treatment of alopecia areata remain to be developed, partly due to the unknown aetiology of the condition. Furthermore, there have been no proven therapies that have been shown to induce and/or sustain remission (6). As a result, dermatologists resort to off-target effects of a range of drugs, including topical steroids, intralesional steroids, systemic steroids, topical immunotherapy, topical anthralin, phototherapy, laser therapy and platelet-rich plasma injections (6, 7). Generally, the milder form of alopecia areata, where there is limited hair loss, is often easier to treat and is associated with higher success rates. However, the more severe forms of alopecia, such as AA totalis and AA universalis, often exhibit poorer responses to treatment (2).

#### *Objective of the study*

The aim of this study was to evaluate the efficacy and tolerability of complementary medicine, Dr. Michaels® product family, in the treatment of alopecia areata.

## MATERIALS AND METHODS

The study has been conducted in 40 patients (27 female/13 male), with a mean age of 20.3 years. All the patients showed 1-3 lesions of stable alopecia areata, localized on the scalp. In past, 13 patients had the same dermatological problem, which was been successfully treated with topical corticosteroids. 4 of all patients had a Hashimoto thyroiditis, and one had a familial history of LES.

Exclusion criteria were instable alopecia areata, use of any treatment or medication which may influence or interfere with the course of the disease.

After obtaining a written consent, all patients were treated with Dr. Michaels® StimOils: applied twice daily morning and night; Hair Lotion: applied twice daily (morning and night); oral herbal formulation: PSC 900 2ml twice daily with food.

StimOils contains essential oils including *Rosmarinus officinalis* (Rosemary), *Eucalyptus globulus* (Eucalyptus), *Juniperus communis* (Juniper oil) and *Lavandula*

*angustifolia* (Lavender oil). Studies have shown that the rosemary plant, due to its dilatory properties, can increase blood flow and its external use has vasodilatory effects on the skin. Most studies have focused on the antioxidant effects of di-terpenoids, especially carnosic acid and carnosol and its antioxidant effect has been credited with stabilizing erythrocyte membranes and inhibiting superoxide generation (8). Rosemary has also been reported to decrease capillary permeability and fragility. Research on the topical anti-inflammatory properties of *Rosmarinus officinalis* leaf extracts support the traditional use of the plant leaves against cutaneous inflammatory diseases (9).

Eucalyptus oil, which is made from the leaves and branches of eucalyptus, contains 60% to 90% eucalyptol (1.8-cineole). Eucalyptol appears to have analgesic and anti-inflammatory effects. Preliminary research suggests eucalyptol might block the production of arachidonic acid metabolites that mediate pain. It might also inhibit cyclooxygenase pathways. It also seems to inhibit the production of cytokines responsible for inflammation such as tumor necrosis factor (TNF)-alpha, interleukin (IL)-1beta, leukotriene B4 and thromboxane B2. Ethanolic extracts of eucalyptus leaf also seem to have anti-inflammatory activity (10). In previous Clinical Trials *Eucalyptus globulus* oil demonstrated that long-term topical application of Eucalyptus extract on human scalp improved physical factors, which determine the appearance, elasticity, luster, bounce and manageability of hair (11).

*Eucalyptus globulus* oil creams and lotions stimulate circulation and act as a safe and effective rubefacient that produces local vasodilation and an increase in blood supply to the area of application (12).

Hair Lotion contains *Urtica Dioica* (Nettle) and *Taraxacum officinale* (Dandelion). Topically, *Urtica dioica* has been used as a remedy to cure dandruff and oily hair and to improve hair appearance. The anti-inflammatory property of *urtica dioica* that functions at a hormonal level has been associated with interfering or blocking hormone related chemical processes in the body, including the activity of DHT (13).

PSC 900 (2ml/ twice daily) containing zinc, pyridoxine hydrochloride (B6), folic acid and ferrous gluconate (Iron) facilitates the improvement and maintenance of general wellbeing. Zinc may impact hair biology via its long-recognized, potent and immunomodulatory effects. It exerts

an indirect antioxidant action by induction of substances that serve as the ultimate antioxidant; these substances are "metallothionein". Zinc is an essential cofactor for over 300 enzymes (zinc metalloenzymes), many of which (e.g. alkaline phosphatase, dopachrome tautomerase, metallothionein and metalloproteases) exert important functional activities in the hair follicle. It is a potent inhibitor of endonucleases, the key constituents of the apoptotic machine. Given the crucial role of keratinocytes apoptosis in hair follicle regression during the involution phase of the hair cycle (catagen), zinc-mediated inhibition of endonuclease activity is a strong candidate for an inhibitor of hair follicle regression. Zinc also inhibits the expression or activity of several enzymes important in hair biology (e.g. tyrosinase, the rate limiting enzyme of hair follicle melanogenesis). It is important for DNA stability and repair-parameters of evident importance in hair biology, since the epithelial hair matrix is one of the most rapidly proliferating and most damage-sensitive tissues in the mammalian organism (16).

Research has found that patients with *alopecia areata* have a lower level of erythrocyte folate, which is in negative correlation with both severity and extension of AA (15). Folic acid, which is required for cellular turnover in a variety of tissues and organs including the hair follicle, may serve as an effective therapeutic agent in some types of alopecia triggered by a deficiency of either folic acid or the co-enzymes involved in the synthetic pathway of DNA (15).

For each patient, photographs of typical lesions were taken at the beginning and at 4, 8, 12 and 16 weeks follow-up. Patient improvement was determined by the percentage of hair regrowth for each lesion.

## RESULTS

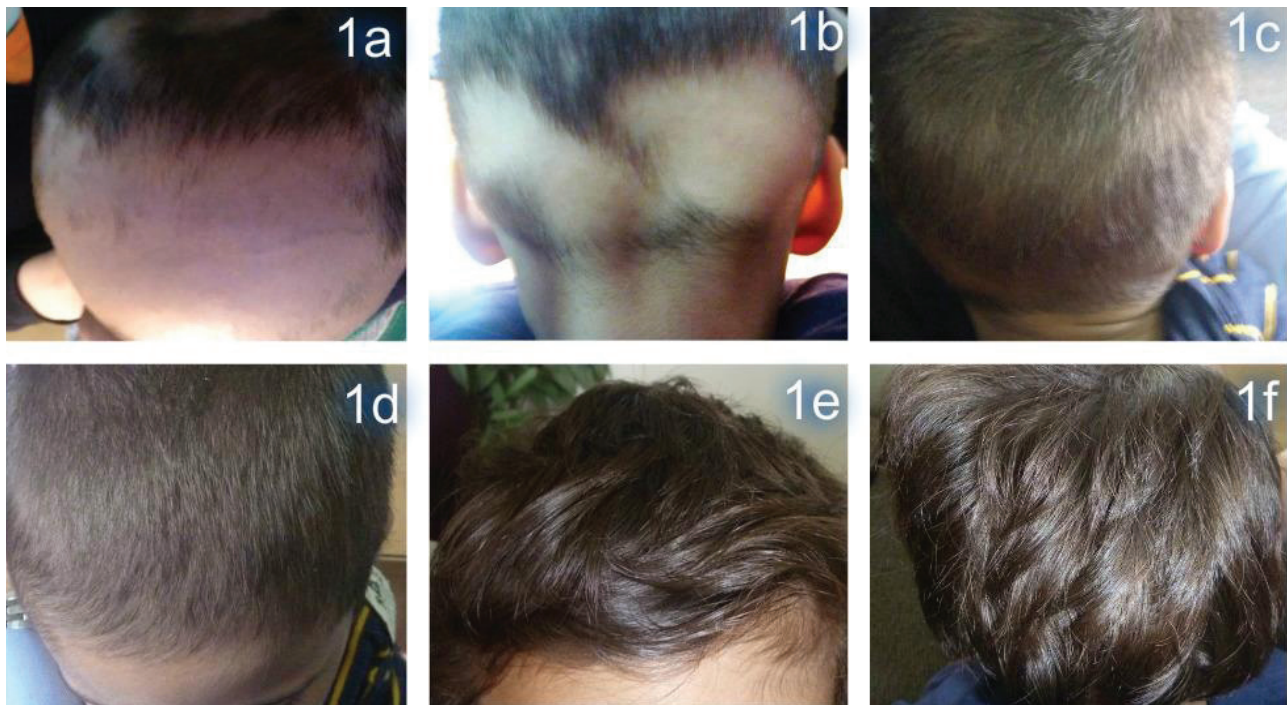The data presented here are the results of a group of 40 patients who had completed the 16 weeks treatment course. After 10 weeks of treatment using StimOils, Hair Lotion and PSC 900 from the Dr Michaels® product family, 18 patients had achieved an excellent response with regrowth in all the affected alopecia areata patches. The regrowth were of similar density to the unaffected scalp. The hair appeared shiny and luxurious with strong tensile strength. 17 patients achieved the

same results after 12 weeks of treatment; the other 5 patients had to continue the therapeutic protocol for another 2-3 weeks.

## DISCUSSION

*Alopecia areata* is a common autoimmune disorder (1). Hair is formed from hair follicles. The lower part of the hair follicle consists of hair papilla, hair matrix, hair shaft, inner root sheath, and outer root sheath. Hair papilla is located in papilla-like projections of the hair follicle's lower dermis, the source of hair growth, and consists of a number of blood tissues and cells. The hair matrix is a collection of epithelial cells called "hair mother cells", often interspersed with the pigment-producing cells called melanocytes. The matrix

wraps completely around the papilla and provides access for the capillary. The hair matrix epithelium is supplied with nutrients from the capillaries. Therefore, improvement of blood circulation in the scalp can have a very close relationship with healthy hair, and a blood circulation disorder caused by compression of the capillaries is one of the causes of hair loss. The cause of hair loss has shown us that the circulation and nutritional disorder of the blood surrounding the hair papilla and hair follicles are the main factor in hair loss. Hair grows when it is supplied with water and nutrients through the capillary around the hair mother cell, so a lack of nutrition through the capillaries results in hair being unable to grow and falling out. Therefore, the development of blood capillaries around the hair is very important for its growth. In addition, recent



**Fig. 1.** *a):* Before treatment with Dr. Michaels® product family, the patient presented with severe alopecia areata on the frontal and mid-scalp area; *b):* Before treatment with Dr. Michaels® product family, the patient presented with severe alopecia areata on the occipital area of the scalp with slight areas of sparing in the posterior aspect of the occipital scalp; *c):* Following 12 weeks of treatment with the Dr. Michaels® product family, the patient achieved complete resolution of the alopecia in the occipital area of the scalp; *d):* Following 12 weeks of treatment with the Dr. Michaels® product family, the patient achieved complete resolution of the alopecia in the frontal and mid-scalp area; *e):* Following 12 months of treatment with the Dr. Michaels® product family, the patient had maintained complete resolution of the alopecia of the frontal aspect of the scalp; *f):* Following 12 months of treatment with the Dr. Michaels® product family, the patient had maintained complete resolution of the alopecia.



increase in physical and mental stress also affects the growth of the hair (16).

The herbal extracts and essential oils contained in the StimOils and Hair Lotion provide anti-inflammatory and vasodilator actions. The need for evidence-based treatments, that have few adverse effects, is strongly warranted for *alopecia areata*. In our study, the patients demonstrated an excellent resolution of their *alopecia areata* following 10-15 weeks of treatment.

### CONCLUSION

This study demonstrates that the Dr Michaels® StimOils, Hair Lotion and PSC 900 are an effective therapeutic option for the treatment of *alopecia areata*. This has important implications for resistant cases of *alopecia areata* where traditional systemic and topical corticosteroid therapies have failed. In addition, this treatment approach may be an attractive option for patients who have growing concerns regarding side effects of long-term corticosteroid therapy.

### ACKNOWLEDGEMENTS

We gratefully acknowledge Tirsell Pty Ltd (Melbourne, Australia) and Frankl Pharma Global Ltd (Surrey, UK) for providing the samples for the study.

### REFERENCES

- Spano F, Donovan JC. Alopecia areata: Part 1: pathogenesis, diagnosis, and prognosis. *Can Fam Physician* 2015; 61(9):751-5.
- Villasante Fricke AC, Miteva M. Epidemiology and burden of alopecia areata: a systematic review. *Clin Cosmet Investig Dermatol* 2015; 8:397-403.
- Gilhar A, Schrum AG, Etzioni A, Waldmann H, Paus R. Alopecia areata: Animal models illuminate autoimmune pathogenesis and novel immunotherapeutic strategies. *Autoimmun Rev* 2016;15(7):726-35
- Prie BE, Voiculescu VM, Ionescu-Bozdog OB, et al. Oxidative stress and alopecia areata. *J Med Life* 2015; 8(S):43-6.
- Petukhova L, Christiano AM. The genetic architecture of alopecia areata. *J Investig Dermatol Symp Proc* 2013; 16(1S):16-22.
- Shapiro J. Current treatment of alopecia areata. *J Investig Dermatol Symp Proc* 2013; 16(1):S42-4.
- Hordinsky MK. Current treatments for alopecia areata. *J Investig Dermatol Symp Proc* 2015; 17(2):44-6.
- Nabavi SF, Tenore GC, Daglia M, Tundis R, Loizzo MR, Nabavi SM. The cellular protective effects of rosmarinic acid: from bench to bedside. *Curr Neurovasc Res* 2015; 12(1):98-105.
- Suggs A, Oyetakin-White P, Baron ED. Effect of botanicals on inflammation and skin aging: analyzing the evidence. *Inflamm Allergy Drug Targets* 2014; 13(3):168-76.
- Goodger JQ, Woodrow IE.  $\alpha,\beta$ -Unsaturated monoterpene acid glucose esters: structural diversity, bioactivities and functional roles. *Phytochemistry* 2011; 72(18):2259-66.
- Mamada A, Ishihama M, Fukuda R, Inoue S. Changes in hair properties by Eucalyptus extract. *J Cosmet Sci* 2008; 59(6):481-96.
- Hong CZ, Shellock FG. Effects of a topically applied counterirritant (Eucalyptamint) on cutaneous blood flow and on skin and muscle temperatures. A placebo-controlled study. *Am J Phys Med Rehabil* 1991; 70(1):29-33.
- Di Lorenzo C, Dell'Agli M, Badea M, Dima L, Colombo E, Sangiovanni E, Restani P, Bosisio E. Plant food supplements with anti-inflammatory properties: a systematic review (II). *Crit Rev Food Sci Nutr* 2013; 53(5):507-16.
- Abdel Fattah NS, Atef MM, Al-Qaradaghi SM. Evaluation of serum zinc level in patients with newly diagnosed and resistant alopecia areata. *Int J Dermatol* 2016; 55(1):24-9.
- Yousefi M, Namazi MR, Rahimi H, Younespour S, Ehsani AH, Shakoei S. Evaluation of serum homocysteine, high-sensitivity CRP, and RBC folate in patients with alopecia areata. *Indian J Dermatol* 2014; 59(6):630.
- Wollina U. Histochemistry of the human hair follicle. *Experientia* 1997; S78:31-58.



## SUCCESSFUL TREATMENT OF RECALCITRANT CANDIDAL INTERTRIGO WITH DR MICHAELS® (FUNGATINEX®) PRODUCT FAMILY

J. HERCOGOVA<sup>1,2</sup>, M. TIRANT<sup>3</sup>, P. BAYER<sup>3</sup>, M. COBURN<sup>3</sup>, B. DONNELLY<sup>3</sup>,  
T. KENNEDY<sup>3</sup>, J. GAIBOR<sup>3</sup>, M. ARORA<sup>3</sup>, L. CLEWS<sup>3</sup>, M. FIORANELLI<sup>4</sup>,  
S. GIANFALDONI<sup>5</sup>, A.A.CHOKOEVA<sup>6,7</sup>, G.TCHERNEV<sup>8</sup>, U.WOLLINA<sup>9</sup>,  
F. NOVOTNY<sup>10</sup>, M.G. ROCCIA<sup>11</sup>, G.K. MAXIMOV<sup>12</sup>, K. FRANÇA<sup>13,14</sup> and T. LOTTI<sup>15</sup>

<sup>1</sup>2nd Medical Faculty, Charles University, Bulovka Hospital, <sup>2</sup>Institute of Clinical and Experimental Medicine, Prague, Czech Republic; <sup>3</sup>Psoriasis & Skin Clinic, Melbourne, Australia; <sup>4</sup>Department of Nuclear Physics, Sub-nuclear and Radiation, Guglielmo Marconi University, Rome, Italy; <sup>5</sup>Dermatological Department University of Pisa, Pisa, Italy; <sup>6</sup>“Onkoderma”-Policlinic for dermatology and dermatologic surgery, Sofia, Bulgaria; <sup>7</sup>Department of Dermatology and Venereology, Medical University of Plovdiv, Medical faculty, Plovdiv, Bulgaria; <sup>8</sup>Medical Institute of Ministry of Interior (MVR), Department of Dermatology, Venereology and Dermatologic Surgery, Sofia, Bulgaria; <sup>9</sup>Department of Dermatology and Allergology, Academic Teaching Hospital Dresden-Friedrichstadt, Dresden, Germany; <sup>10</sup>PRO SANUM Ltd, Sanatorium of Prof. Novotný, Štěpánská Prague 1 Czech Republic; <sup>11</sup>University B.I.S. Group of Institutions, Punjab Technical University, Punjab, India; <sup>12</sup>Department “Medicinal Information and Non-interventional studies”, Bulgarian Drug Agency, Sofia, Bulgaria; <sup>13</sup>Department of Dermatology & Cutaneous Surgery, Department of Psychiatry & Behavioral Sciences, Institute for Bioethics & Health Policy, University of Miami, Miller School of Medicine, Miami, FL, USA; <sup>14</sup>Centro Studi per la Ricerca Multidisciplinare e Rigenerativa, Università Degli Studi “G. Marconi”, Rome, Italy; <sup>15</sup>Chair of Dermatology, University of Rome “G. Marconi” Rome, Italy

Candidal intertrigo is an infection of the skin caused by *Candida albicans* that typically occurs in opposing cutaneous or muco-cutaneous surfaces. Because Candidiasis requires a damaged and moist environment for infection, it typically occurs in areas of friction such as the skin folds of the body. Candidal intertrigo is often difficult to treat and results are often unsatisfactory. In addition, there is a lack of evidence-based literature supporting prevention and treatments for candidal intertrigo. The aim of the study was to evaluate the efficacy of Dr Michaels® (also branded as Fungatinex®) products in the treatment of fungal intertrigo, in 20 women and 2 men with a mean age of 72. Five patients (3 female and 2 male) had type 2 diabetes and 16 (14 female and 2 male) were obese. The patients were treated with Dr Michaels® (Fungatinex®) moisturising bar, topical ointment (twice daily application) and oral herbal formulation, PSC 200 two tablets twice daily with food. After 2 weeks of treatment, the lesions had mostly resolved in all patients with only slight erythema evident. After six weeks of treatment using the moisturising bar, topical ointment and oral herbal formulations from the Dr Michaels® (Fungatinex®) product family, the lesions had totally resolved in 18 patients, while 4 patients had to continue the therapeutic protocol for another 2 weeks. Our results demonstrate that the Dr Michaels® (Fungatinex®) complementary product family is efficacious in the treatment of recalcitrant candidal intertrigo. Furthermore, this study highlights that the Dr Michaels® (Fungatinex®) product family is fast-acting and well tolerated with no serious adverse events reported. These data have important implications for resistant cases of candidal intertrigo where traditional therapies have failed.

*Key words: candida intertrigo, adults, inflammatory fold, therapy, resistant, Dr Michaels (Fungatinex®) products*

Mailing address:  
Professor Torello Lotti,  
Department of Dermatology,  
University of Rome “G. Marconi”,  
Rome, Italy  
e-mail: professor@torelloitti.it

Candidal intertrigo is an infection of the skin caused by fungus *Candida albicans* which typically occurs in opposing cutaneous or muco-cutaneous surfaces (1). Candidiasis is found worldwide and any age group can be affected, however, infants and the elderly are more commonly affected with no gender preference noted (2, 3). Infants are at high risk for intertrigo because they have short necks, relative chubbiness, and flexed posture (4). Because Candidiasis requires a damaged and moist environment for infection, it typically occurs in areas of friction such as the skin folds of the body (4). Thus, candidal intertrigo is commonly found in large skin folds such as the inframammary folds, inguinal, abdominal and perianal skin folds. However, it may also affect minor skin folds, such as the, inter-digital areas and folds of the eyelids (1, 2).

Clinically, intertrigo begins as mild erythema that initially presents as red plaques in a mirror format, on each side of the skinfold, and are often moist (4). The erythema may progress to more intense inflammation with erosions, oozing, fissures, exudation, maceration and crusting. Patients often complain about the associated pruritus, burning feeling, pain and odour (3, 4). Once intertrigo is established, various secondary fungal superinfections may exacerbate the condition, including yeasts, moulds, and dermatophytes. However, *Candida* is the most commonly associated fungus with intertrigo (2, 5, 6). Signs of secondary infection with *Candida* include a prominent inflammatory response with satellite papules and pustules and an associated foul-smelling odour (2) whilst bacterial superinfections typically demonstrate plaques and abscesses (6).

The diagnosis of candidal intertrigo is often based on the clinical manifestation and direct microscopic investigation on the presence of abnormal levels of *Albicans* in the skin surface. Generally, intertrigo demonstrates no characteristic histological features (5), however, if a secondary infection is suspected then relevant cultures can be performed (6). The main diagnostic test for infection with *candida* is a potassium hydroxide preparation positive for pseudohyphae and spores, blankophore fluorescent microscopy or mycological culture (2).

The conventional approach to managing simple intertrigo is to minimize moisture and friction (6, 7). The use of absorptive powders, such as talc or cornstarch is obsolete. In addition, it is recommended that patients wear light, non-constrictive, and absorbent clothing and should avoid wool, nylon and synthetic fibres (1, 2, 3), whilst the main treatment recommended for intertrigo with concomitant *candida* infection is topical anti-fungal lotions, creams, or ointments (1, 2).

Topical anti-fungals can be subdivided into specific and non-specific agents (8, 9, 10). Specific agents such as polyenes are generally used for the treatment of *Candida* and although generally well-tolerated, they are associated with causing skin-irritations and striae, whilst systemic anti-fungal treatments are associated with various adverse reactions which are considered mild, transient, and reversible after discontinuation of therapy. The most frequently reported adverse effects are those associated with gastrointestinal system.

This study shows that the Dr Michaels® (Fungatinex®) complementary product family is efficacious in the treatment of recalcitrant candidal intertrigo in elderly patients, independent of traditional therapies. Furthermore, this case report highlights that the Dr Michaels® (Fungatinex®) product family is fast-acting and well tolerated with no serious adverse events reported.

#### *Objective of the study*

To evaluate Dr Michaels® (Fungatinex®) moisturising bar, topical ointment (twice daily application) and oral herbal formulation, in the treatment of fungal intertrigo.

## MATERIALS AND METHODS

We evaluated the efficacy of Dr Michaels® (Fungatinex®) products in the treatment of fungal intertrigo, in 20 women and 2 men with a mean age of 72 over an 8-week period.

In detail, 19 women had a fungal infection in the inframammary folds; the other patients had the same infection in the inguinal region.

No other family members were known to be affected by a similar condition. Five patients (3 females and 2 males)

had diabetes and 16 (14 females and 2 males) were obese.

Patients' clinical examination revealed a symmetric involvement of erythematous, thin scaly plaques with macerations under the folds. The conditions were extremely pruritic and had a foul-smelling odour. The erythematous plaques were surrounded by small satellite erythematous macules, papules and pustules. Direct microscopic evaluation demonstrated in all cases the presence of *Candida Albicans* infection.

The patients were treated with Dr Michaels® moisturising bar, topical ointment twice daily and oral herbal formulation, PSC 200, two tablets twice daily with food.

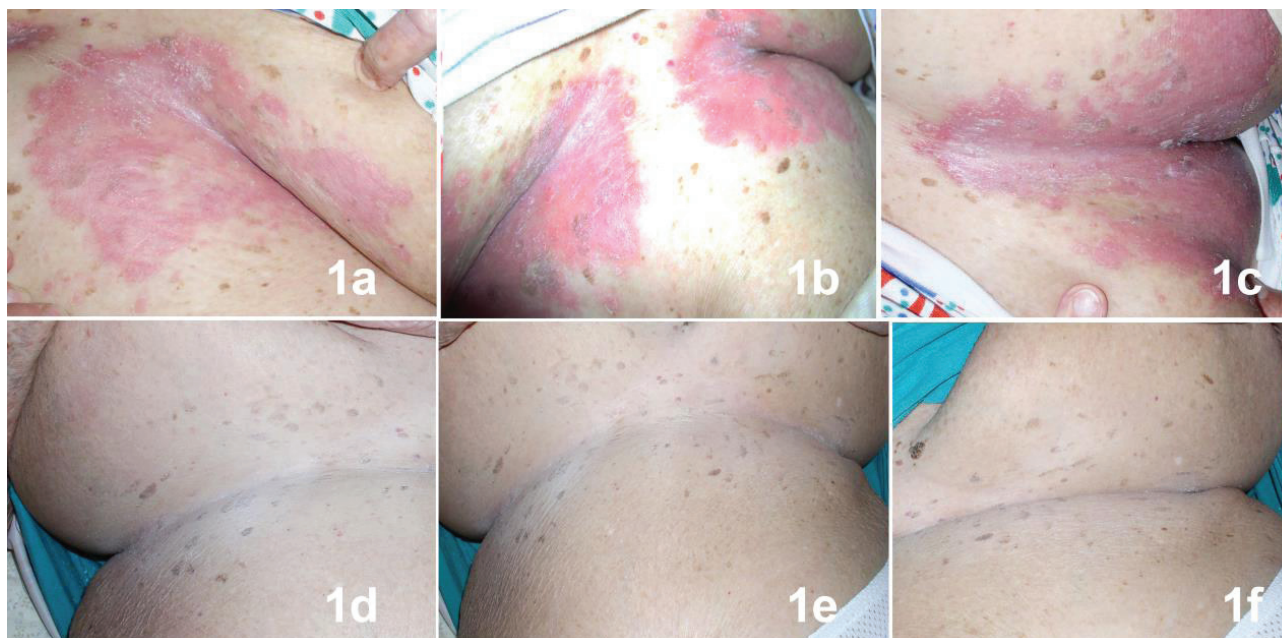
Dr Michaels Moisturising bar was used for its cleansing and soothing properties. Cleansing removes unwanted material, soil and bacteria from skin and also removes endogenous dirt (crusts, scales etc.), preparing the permeability of the skin barrier to better absorb subsequently applied topical medication. The ingredients in the moisturising bar include tocopheryl acetate, and various essential oils (lavender oil and evening primrose oil). These ingredients are known to have anti-pruritic properties and form a moisturising foamy lather when combined with water. Many of the ingredients are classified as skin conditioning and emollients. Dr Michaels® Moisturising

Bar is gentle enough to use on the entire body including the most sensitive skin.

The Dr Michaels® (Fungatinex®) ointment contains zinc oxide, salicylic acid and essential oils including calendula, orange, lavender, emu, rosemary, eucalyptus and chamomile. The oral formulation PSC 200 contains a range of herbal extracts including *berberis vulgaris* stem bark, *astragalus membranaceus* root, *taraxacum officinale* root, *Thymus vulgaris* and panax ginseng root. Research has shown that thyme has antimicrobial activity and modest antibacterial effects. Thyme has also shown to have activity against fungi such as *Candida albicans* and other *Candida* species. The combination of herbal extracts act as an antibacterial, anti-fungal and anti-viral agent.

## RESULTS

After 2 weeks of treatment, the lesions had mostly resolved in all patients with only slight erythema evident. In addition, all patients noted that the associated pain and pruritus had ceased. The patients were asked to continue with treatment and to have a follow up after 4 weeks. Pruritus was measured by the 5-D Pruritus Scale involving five



**Fig. 1. a, b, c):** Prior to treatment with Dr Michaels® (Fungatinex®) product family, the patient demonstrated severe intertrigo in the inframammary fold infected by *C. albicans*. Note the satellite papules and pustules; **d, e, f):** After 6-weeks of treatment with the Dr Michaels® (Fungatinex®) product family, the patient demonstrated complete resolution of the inframammary candidal intertrigo.

categories (duration, degree, direction, disability and distribution) (11).

After six-weeks of treatment using the moisturising bar, topical ointment and oral herbal formulations from the Dr Michaels® (Fungatinex®) product family, the lesions had totally resolved in 18 patients, while 4 patients had to continue the therapeutic protocol for another 2 weeks.

## DISCUSSION

Intertrigo is characterized primarily by mild erythema that initially presents as red plaques, almost in a mirror image, on each side of the skin fold (3). The erythema may progress to more intense inflammation with erosions, oozing, fissures, exudation, maceration, and crusting (3). In addition, patients may present with pruritus and burning in the affected areas (2). Generally, more prominent inflammation and the presentation of satellite lesions is a sign of secondary fungal infection with *C. albicans* (1).

In our patients, chronic candidal intertrigo led to discomfort in the form of severe pruritus and pain, as also seen in various other case reports (8, 9, 10). However, after 2 weeks of treatment with the Dr Michaels® (Fungatinex®) product family, the patients demonstrated a rapid resolution of their candidal intertrigo and associated pruritus. At the 6-8 weeks review, they continued to show total resolution.

The resolution of the candidal intertrigo observed following Dr Michaels® (Fungatinex®) product family treatment, is attributed to the synergistic effect of the moisturising bar topical ointment and oral supplements. Specifically, the moisturising and humectant agents found in the Dr Michaels moisturising bar replenish the skin lipids lost during washing and result in rapid stratum corneum repair. Whilst the ointment contains anti-inflammatory, anti-fungal, anti-septic, anti-pruritic, analgesic and emollient properties which promote normal epithelialisation.

## CONCLUSION

In conclusion, our open clinical study demonstrates

that the Dr Michaels® moisturising bar, ointment and oral formulations are an effective therapeutic option for the treatment of candidal intertrigo. Moreover, it highlights the rapid improvement and safety profile of the Dr Michaels® (Fungatinex®) product family for the treatment of candidal intertrigo compared to traditional first-line treatments. These data have important implications for resistant cases of candidal intertrigo where traditional therapies have failed.

## ACKNOWLEDGEMENTS

We gratefully acknowledge Tirsell Pty Ltd (Melbourne, Australia) and Frankl Pharma Global Ltd. (2 Parklands Place, Guilford, Surrey, United Kingdom) for providing the products for the studies.

## REFERENCES

1. Tüzün Y, Wolf R, Bağlam S, Engin B. Diaper (napkin) dermatitis: A fold (intertriginous) dermatosis. *Clin Dermatol* 2015; 33(4):477-82.
2. Metin A, Dilek N, Demirseven DD. Fungal infections of the folds (intertriginous areas). *Clin Dermatol* 2015; 33(4):437-47.
3. Mistiaen P, Poot E, Hickox S, Jochems C, Wagner C. Preventing and treating intertrigo in the large skin folds of adults: a literature overview. *Dermatol Nurs* 2004; 16:43-6,49-57.
4. Mistiaen P, van Halm-Walters M. Prevention and treatment of intertrigo in large skin folds of adults: a systematic review. *BMC Nurs* 2010; 9:12.
5. Janniger CK, Thomas I. Diaper dermatitis: an approach to prevention employing effective diaper care. *Cutis* 1993; 52:153-5.
6. Kalra MG, Higgins KE, Kinney BS. Intertrigo and secondary skin infections. *Am Fam Physician* 2014; 89(7):569-73.
7. Aste N, Atzori L, Zucca M, Pau M, Biggio P. Gram-negative bacterial toe web infection: a survey of 123 cases from the district of Cagliari, Italy. *J Am Acad Dermatol* 2001; 45(4):537-41.
8. Valenti L. Topical treatment of intertriginous candidal infection. *Mycoses* 2008; 51(S1):44-5.
9. Dogan B, Karabudak O. Treatment of candidal intertrigo with a topical combination of isoconazole nitrate and

- diflucortolone valerate. *Mycoses* 2008; 51(S4):42-3.
10. Veraldi S. Rapid relief of intertrigo-associated pruritus due to *Candida albicans* with isoconazole nitrate and diflucortolone valerate combination therapy. *Mycoses* 2013; 56(S1):41-3.
  11. Elman S, Hynan LS, Gabriel V, Mayo MJ. The 5-D itch scale: a new measure of pruritus. *Br J Dermatol* 2010; 162(3):587-93.





## SUCCESSFUL TREATMENT OF FACIAL SYSTEMIC LUPUS ERYTHEMATOSUS LESIONS WITH DR MICHAELS® (SORATINEX®) PRODUCT FAMILY. A CASE REPORT

M. TIRANT<sup>1</sup>, P. BAYER<sup>1</sup>, J. HERCOGOVÁ<sup>2,3</sup>, M. FIORANELLI<sup>4</sup>, S. GIANFALDONI<sup>5</sup>, A.A. CHOKOEVA<sup>6,7</sup>, G. TCHERNEV<sup>8</sup>, U. WOLLINA<sup>9</sup>, F. NOVOTNY<sup>10</sup>, M.G.ROCCIA<sup>11</sup>, G.K. MAXIMOV<sup>12</sup>, K. FRANÇA<sup>13,14</sup> and T. LOTTI<sup>15</sup>

<sup>1</sup>*Psoriasis & Skin Clinic, Melbourne, Australia;* <sup>2</sup>*2nd Medical Faculty, Charles University, Bulovka Hospital,* <sup>3</sup>*Institute of Clinical and Experimental Medicine, Prague, Czech Republic;* <sup>4</sup>*Department of Nuclear Physics, Sub-nuclear and Radiation, G. Marconi University, Rome, Italy;* <sup>5</sup>*Dermatological Department University of Pisa, Pisa, Italy;* <sup>6</sup>*“Onkoderma”-Policlinic for dermatology and dermatologic surgery, Sofia, Bulgaria;* <sup>7</sup>*Department of Dermatology and Venereology, Medical University of Plovdiv, Medical faculty, Plovdiv, Bulgaria;* <sup>8</sup>*Medical Institute of Ministry of Interior (MVR), Department of Dermatology, Venereology and Dermatologic Surgery, Sofia, Bulgaria;* <sup>9</sup>*Department of Dermatology and Allergology, Academic Teaching Hospital Dresden-Friedrichstadt, Dresden, Germany;* <sup>10</sup>*PRO SANUM Ltd, Sanatorium of Prof. Novotný, Štěpánská Prague 1, Czech Republic;* <sup>11</sup>*University B.I.S. Group of Institutions, Punjab Technical University, Punjab, India;* <sup>12</sup>*Department of Medicinal Information and Non-interventional studies, Bulgarian Drug Agency, Sofia, Bulgaria;* <sup>13</sup>*Department of Dermatology & Cutaneous Surgery, Department of Psychiatry & Behavioral Sciences, Institute for Bioethics & Health Policy, University of Miami, Miller School of Medicine, Miami, FL, USA;* <sup>14</sup>*Centro Studi per la Ricerca Multidisciplinare e Rigenerativa, Università Degli Studi “G. Marconi”, Rome, Italy;* <sup>15</sup>*Chair of Dermatology, University of Rome “G. Marconi” Rome, Italy*

**Systemic lupus erythematosus (SLE) is a complex autoimmune disease in which the body’s immune system mistakenly attacks healthy tissue. It can affect the skin, joints, kidneys, brain and other organs. We report the case of a 7-year-old female patient with facial lesions of SLE since the age of 5. There was no significant family history and patient had been a healthy child from birth. The child presented with a malar rash, also known as a butterfly rash, with distribution over the cheeks but sparing the nasal bridge. This case represents the efficacy of the Dr. Michaels® (Soratinex®) product family in the successful resolution of facial lesions of SLE.**

Systemic lupus erythematosus (SLE) is a chronic autoimmune disease that can involve any organ system with a wide range of disease manifestations and can lead to significant morbidity and even mortality. Childhood-onset SLE (cSLE) is a rare disease with an incidence in the USA of 0.3-0.9 per 100.000 children-years and a prevalence of 3.3-8.8 per 100.000 children (1). A higher frequency of cSLE is reported in Asians, African Americans, Hispanics and Native Americans (2).

The diagnosis of cSLE can be difficult but early recognition of the disease is important to limit adverse outcomes, as cSLE follows a more severe disease course than adult SLE onset, having a higher frequency of morbidity and lower survival rates (1). The classical facial rash presentation of SLE is the malar, or butterfly rash as seen in 60-85% of children with SLE and is generally described as erythematous, raised, non-pruritic, and non-scarring (2, 3). The rash often extends over the nasal bridge and can affect

*Key words: systemic lupus erythematosus, facial lesions, skin rash, butterfly erythema, malar rash*

Mailing address:  
Professor Torello Lotti,  
Department of Dermatology,  
University of Rome “G. Marconi”,  
Rome, Italy  
e-mail: professor@torelloitti.it

95(S3)

0393-974X (2016)  
Copyright © by BIOLIFE, s.a.s.  
This publication and/or article is for individual use only and may not be further reproduced without written permission from the copyright holder.  
Unauthorized reproduction may result in financial and other penalties  
**DISCLOSURE: ALL AUTHORS REPORT NO CONFLICTS OF INTEREST RELEVANT TO THIS ARTICLE.**

the chin and ears, but spares the nasolabial folds thus distinguishing itself apart from seborrhoeic dermatitis. cSLE can present a diverse range of skin manifestations and children and adolescents with cSLE can develop a rash of (almost) any morphology, location and distribution, presenting the primary care physician with a diagnostic challenge (3).

#### *The Common Clinical Feature*

Recent evidence has demonstrated that T cells are crucial in the pathogenesis of SLE in that they enhance the production of autoantibodies by offering complex and substantial help to B cells through stimulating the latter to differentiate, proliferate, and mature, in addition to their support on class-switching of autoantibodies which B cells are releasing (4, 5, 6, 7). Therefore, SLE is currently believed to be a complex T cell-driven condition (8, 9, 10).

SLE patients in general are immunocompromised due to immune dysfunction intrinsic to the disease itself and due to the frequent use of high dose corticosteroids and other immunosuppressive treatments. Secondary infection is frequently

bacterial (60-80%), including pneumococcus, meningococcus, type B hemophilus, influenza and salmonella. Epstein-Barr virus (EBV) and cytomegalovirus (CMV) infections may be related to the development of systemic lupus erythematosus (lupus) in certain cases (11). All SLE patients have a great risk in becoming compromised with EBV, CMV, herpes zoster and herpes simplex. Pneumonia, bacterial sepsis and CMV all present a serious risk and subsequent infections may be severe or even fatal in the immunocompromised cSLE patient (11).

Although mortality rates have decreased significantly over the past two decades, with 10 and 15 year survival exceeding 85% due to improvement in treatment options, by the time cSLE patients aged 12 (the median age of disease onset) reach the age of 22 to 27, up to 15 % of them would have died (3, 12, 13). Mortality in the first several years of disease is most commonly secondary to infection, ESRD or severe systemic lupus flare, while cardiovascular and other organ disease plays a significant role in late mortality (3).

<b>Clinical Feature</b>	<b>Prevalence of Involvement</b>
<b>Constitutional and generalized symptoms</b>	
Fever	37 – 100%
Lymphadenopathy	13 – 45%
Weight loss	21 – 32%
<b>Mucocutaneous</b>	60 – 90%
<b>Musculoskeletal</b>	60 – 90%
<b>Nephritis</b>	48 – 78%
<b>Neuropsychiatric disease (NPSLE)</b>	15 – 95%
<b>Gastrointestinal</b>	24 – 40%
<b>Hematologic</b>	50 – 100%
<b>Cardiovascular</b>	25 – 60%
<b>Pulmonary</b>	18 – 81%

### *Current treatments for SLE*

Studies have shown that patients with SLE rarely achieve long lasting drug free remission. The majority of patients who have chronic active disease are usually on long term immunosuppressive treatment regimens (12, 13). Treatment also varies greatly due to disease severity and the organs involved. The USA Federal Drug Agency (FDA) have only approved acetyl salicylic acid and prednisone for use in patients with cSLE, indicating that the use of multiple immunosuppressants treatments used are on an “off-label” basis (14). All of these drugs have potential serious side effects. The balance of risk versus benefit is always at the forefront of a treatment regimen (14, 15). The other treatments that are used for mild symptoms particularly rash and arthritis include anti-malarials, hydroxychloroquine and chloroquine. Non-steroidal anti-inflammatory drugs (NSAIDs) are prescribed primarily for musculoskeletal symptoms (3). More than 90% of all cSLE patients will receive either oral or intravenous corticosteroids at some point in their disease course. The dose and duration of which will depend upon the active manifestation(s) being treated (16).

This has implications for juvenile patients with SLE in that treatment is aimed at suppressing the immune system. The immunosuppression achieved with these treatments, such as corticosteroids, is nonspecific, not always effective, and often associated with significant toxicities; the most significant being growth retardation, accelerated atherosclerosis and severe infectious complications. A systematic review of the side effects of short-course oral corticosteroids in children analysed 38 studies including 22 randomised controlled trials (RCTs), and a total of 3200 children. Here, 850 adverse drug reactions (ADRs) were reported. The three most frequent ADRs were vomiting, behavioural changes and sleep disturbance, with respective incidence rates of 5.4%, 4.7% and 4.3% of patients. Infection was one of the most serious ADRs; one child died after contracting varicella zoster infection.

### *Case report*

We report the case of a 7-year old girl who presented with erythematous patches on both cheeks.

Onset was 18 months prior to attending our clinic. The butterfly rash had been previously diagnosed as cutaneous SLE at the Children’s Hospital (Melbourne, Australia). There was no family history. She had a history of recurrent viral and bacterial infections, especially streptococcal, ear infections and fever. Her mother also mentioned that she had been experiencing weight loss and extreme fatigue and occasional leg pain. Although she attended school, she was frequently absent. She did not like school and thought of it as a chore and would not interact with the other children. The mother described the child as quick tempered and would normally refuse to follow directions or adhere to treatment regime. Her mother explained that she had a negative outlook towards anything that was suggested to her and reluctant to become involved in activities, especially sports. She would normally keep to herself and had minimal interaction during her consultation preferring to look at her laptop. Her mother described that she would normally take out a lot of her frustration on her younger sibling. Although she felt tired, her sleeping pattern was poor. There was occasional generalised pruritus.

The patient had been treated by the family doctor with topical hydrocortisone 1% for 2 months with no improvement. She was also given a short-term course of systemic corticosteroids with no noticeable benefit. This was discontinued and she was given Hydrazole Cream 1%, which claimed to provide relief for the erythema, itching and discomfort associated with the inflamed skin. The patient did not respond and the lesions worsened after one month. The patient was then treated with antibiotics and when the patient again failed to respond, she was then referred to the Dermatologist at the Royal Children’s Hospital (Melbourne, Australia) where she was diagnosed with cSLE and treated with higher doses of systemic steroids. Although minor improvement was seen, the patient failed to fully respond and this was discontinued as her mother did not want her to be on long-term steroid therapy because of potential adverse effects. There was no other systemic organ involvement.

Examination revealed maculo-papular lesions involving the cheeks and forehead. The lesions were

mildly pruritic (Fig. 1a). The patient was treated with Dr Michaels® (Soratinex®) product family including moisturising bar, topical ointment and oral herbal formulation, PSC 900 – 2 ml twice daily with food.

Dr Michaels® Moisturising bar was used for its cleansing and soothing properties. Cleansing removes unwanted material soil, and bacteria from skin and also removes endogenous material (crusts, scales etc.), preparing the permeability of the skin barrier to better absorb subsequently applied topical medication. The ingredients in the moisturising bar include tocopheryl acetate, and various essential oils (lavender oil, evening primrose oil). These ingredients are known to have anti-pruritic properties and these form a moisturising foamy lather when combined with water. Many of the ingredients are classified as skin conditioning and emollients. Dr Michaels Moisturising bar is gentle enough to use on the entire body including the most sensitive skin.

The topical ointment is an anti-inflammatory and provides barrier repair while restoring skin lipid imbalances. The ointment contains zinc oxide, salicylic acid and essential oils including calendula, orange, lavender, emu, rosemary, eucalyptus and chamomile in a petroleum jelly, glycerine base. Zinc is required for collagen and protein synthesis as low levels of zinc are associated with impaired wound healing. Zinc is also required for cellular growth and replication and may assist in wound healing by reducing free radical activity and inhibiting bacterial growth. Zinc serves as a cofactor in numerous transcription factors and enzyme systems including zinc-dependent matrix metalloproteinases that augment autodebridement and keratinocyte migration during wound repair. Zinc confers resistance to epithelial apoptosis through stabilizing cellular membranes, and cytoprotection against reactive oxygen species and bacterial toxins through antioxidant activity of the cysteine-rich metallothioneins and superoxide dismutase (12).

Chamomile oil contains alpha-bisabolol, alphasabolol oxides A & B, and matricin (usually converted to chamazulene and other flavonoids, which possess anti-inflammatory and antiphlogistic properties. A study in human volunteers demonstrated that chamomile flavonoids and essential oils penetrate

below the skin surface into the deeper skin layers. This is important for its use as topical antiphlogistic (anti-inflammatory) agent. One of chamomile's anti-inflammatory activities involve the inhibition of LPS-induced prostaglandin E(2) (PGE2) release and attenuation of cyclooxygenase (COX-2) enzyme activity without affecting the constitutive form, COX-1 (13). Polyphenols in chamomile oil possess anti-inflammatory effects due to the inhibition of pro-inflammatory biomarkers in THP1 macrophages and which can reduce inflammation in neurovascular units (NVU) at the site of migraine pain. Chamomile has neuroprotective effects because of reduced tissue NO levels (14).

The constituent ingredients of this carefully blended formula, address the different factors that contribute to dry skin and restores epidermal differentiation. The essential oils and herbal extracts in topical ointment not only address the different factors that contribute to dry skin but also restores epidermal differentiation by restoring the epidermal lipids, improve skin hydration, skin elasticity and prevent itching.

PSC 900, a zinc and folic acid based supplement, which facilitates the improvement and maintenance of general wellbeing and also contains pyridoxine hydrochloride (B6) and ferrous gluconate (Iron) facilitates the symptomatic relief and management of dry skin and is necessary for the production and maintenance of new cells and DNA and RNA synthesis. Vitamins B6 and folate, are important cofactors in its metabolism and promote a reduction in homocysteine levels. In addition, those vitamins also influence the serum levels of some inflammatory markers, such as pro-inflammatory cytokines and C-reactive protein (CRP). Studies with patients with SLE have shown that anaemia can be detected in up to 70% of patients during the course of disease. The most often found type of anaemia is that of chronic disease (characterized by deficient mobilization of iron to the bone marrow, despite the normal or increased values of iron reserves) (14, 15).

## RESULTS

Following 2 weeks of local treatment (Fig. 1b)

using Dr Michaels® (Soratinex®) product family of moisturising bar, ointment and PSC900, there was a marked improvement in the condition, with a reduction in erythema. During treatment, the patient contracted a streptococcal infection with associated sore throat and fever. She felt very tired and lethargic, could not attend school, and was bed-ridden. Her parents explained that normally in these circumstances, her condition would have worsened. They were surprised that her skin was still improving in spite of these complications.

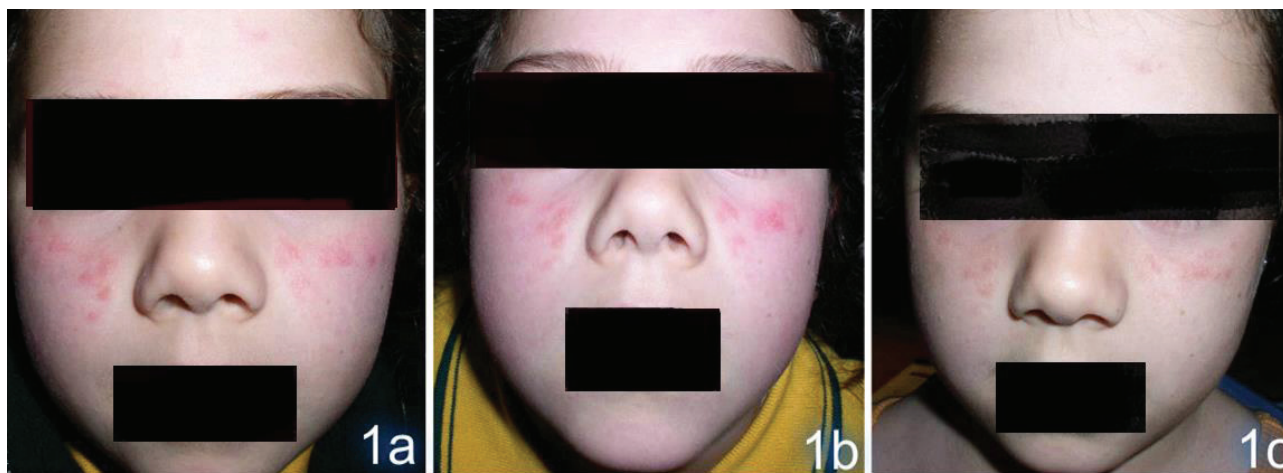
After 4 weeks of treatment (Fig. 1c), further improvement was seen, with significant reduction in the underlying erythema. There was a significant reduction in the size of the lesions, as well as infiltration and scale. The parents had also indicated that the child was more even tempered and calmer and not displaying her normal “tantrum” behaviour.

Following 8 weeks of treatment with Dr Michaels® (Soratinex®) product family (Fig. 2a), the patient continued to improve, only slight scale and mild hyperpigmentation remaining on the cheeks. This pigmentation continued to improve as can be seen at 12 weeks (Fig. 2b). After 16 weeks (Fig. 2c) of treatment, only 4 small areas of pigmentation were visible, as the lesions had totally resolved.

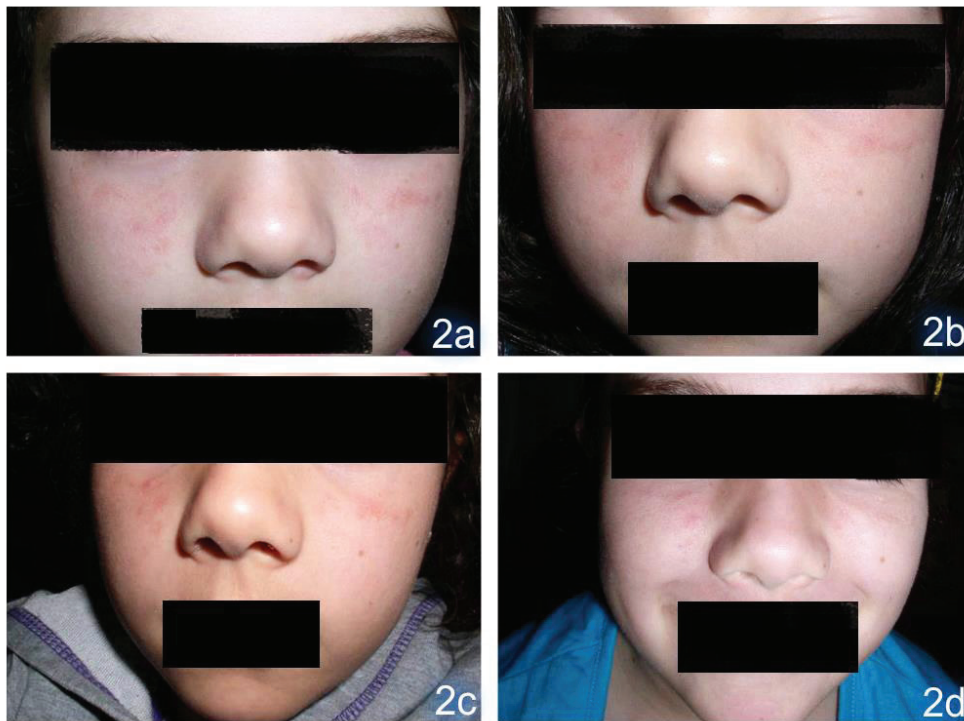The patient was advised to go on a maintenance program using Dr Michaels® (Soratinex®) product family once daily in the evening. After 12 months of treatment, she returned for a follow up consultation (Fig. 2d). She continued to be symptom free and had no new lesions during that period. The patient was very happy. Her parents described her as a totally new child. She started to interact with other school children and getting along really well with her sibling. She was happy to attend school and was actually performing very well academically. She was involved in more sporting activities. Her mood swings had markedly improved and her “quick temper” had been well managed. She interacted well at her consultation and was actually telling stories and jokes.

## DISCUSSION

The autoimmune nature of lupus and its predominant inflammatory component is accompanied by the expression of cyclooxygenase-2 (COX-2) in the inflammatory areas, with the subsequent release of arachidonic acid via membrane-bound phospholipase A2. The biosynthesis of arachidonic acid by COX-2 led to an enhancement of prostanoid production of PGE2



**Fig. 1. a):** Prior to treatment with Dr. Michaels®(Soratinex®) product family, the patient demonstrated moderately severe inflammatory papules on the face; **b):** Following 2-weeks of treatment with the Dr. Michaels® (Soratinex®) product family, the patient demonstrated good improvement; **c):** Following 4-weeks of treatment with the Dr. Michaels® (Soratinex®) product family, the patient demonstrated good improvement.



**Fig. 2. a):** Following 8-weeks of treatment with the Dr. Michaels® (Soratinex®) product family, the patient demonstrated good improvement; **b):** Following 12-weeks of treatment with the Dr. Michaels® (Soratinex®) product family. Only some hyperpigmentation remains; **c):** After 16 weeks of treatment with Dr. Michaels® (Soratinex®) product family, with almost total resolution of the lesions; **d):** After 12 Months maintenance program with Dr. Michaels® (Soratinex®) product family- showing continued remission of the lesions.

series, which conduct to the dysregulation in the production of proinflammatory cytokines (IL-6, IL-10, and nitric oxide) (16). Several of the essential oils have been shown to be effective at inhibiting the production of PGE2 and the subsequent release of COX-2 and are classified as anti-inflammatories.

Systemic lupus erythematosus (SLE) is a multisystem disease characterized by the production of large quantities of antibodies reactive with self-antigens. The immune system of patients with active SLE is characterized by generalized B-cell hyperactivity and impaired T-cell function (3, 4).

Evidence has shown that without the abnormal assistance of the helper T lymphocytes, it would be difficult for B cells to become functional enough to trigger SLE-related inflammation. Studies have provided evidence that zinc functions as an ionic signalling molecule after T cell activation. Cytoplasmic zinc concentrations have been shown

to increase within 1 min after TR cell response (TCR) triggering as the result of an influx via the zinc transporter Zip6. The increase is most pronounced in the immediate sub-synaptic area and enhanced TCR signalling, at least in part, as a result of inhibition of SHP-1 recruitment. Consequently, TCR activation thresholds is lowered and T cell responses is induced under suboptimal conditions. An influx of zinc after TCR stimulation leads to a local increase in cytoplasmic zinc, modifies early TCR signalling events, and selectively lowers TCR activation thresholds. The local confinement of increased zinc concentrations targets the effect to amplifying proximal TCR signals without globally modifying the many different cellular processes regulated by zinc-binding proteins. Because the zinc influx originates from extracellular sources, local manipulation of zinc availability may be a means to enhance T cell responses to antigens.

Vitamin B6 is also thought to influence the acquired cell mediated and humoral immunity. Animal and human studies showed an association between vitamin B6 deficiency and impairment of several immune functions, such as the proliferation of T- and B-lymphocytes, cytotoxicity of T-lymphocytes, delayed type hypersensitivity reactions, antibody production and the production of several interleukins. Therefore, adequate levels of vitamin B6 are required for a normal immune response. Some studies found improvement of immune functions in vitamin B6 supplementation, indicating that vitamin B6 enhances an immune response, but in most studies, the supplemented subjects were vitamin B6 deficient first. Only a few studies showed improvement of immune functions above normal levels in subjects treated with an excess of vitamin B6. In contrast, a few recent studies showed decreased vitamin B6 levels in inflammation, indicating that vitamin B6 has also anti-inflammatory properties.

As the ultimate goal for any topical SLE therapy is to restore homeostasis without affecting protective immune responses to pathogens, we find that the ingredients contained in the PSC 900 provide the patient with the vital nutrients required to regulate and maintain a healthy immune function.

### CONCLUSION

Our patient with juvenile cSLE, showed marked improvement in her skin condition during a period of 16 weeks of treatment, with most of the lesions and symptoms totally resolved within 12 weeks of treatment with Dr. Michaels® (Soratinex®) family of products, as seen in Fig. 1a, b, c, and 2a, b, c, d.

As only 1 in 10 SLE patients will go on to develop severe systemic organ involvement, it is critical to achieve remission of the skin symptoms of SLE as quickly as possible. The aim is to control and maintain this cutaneous remission without the need for systemic corticosteroids. The Dr. Michaels® ointment allows the control of the inflammation of the skin lesions through the inhibition of the production of PGE2 and the release of COX-2. The PSC 900, by regulating and maintaining a healthy immune function, inhibits the production of defective T cells, control B cell

over production and restores the patient's immune homeostasis.

The importance of maintaining the condition in remission is therefore critical and after 12 months on a maintenance program of the Dr Michaels products and PSC 900, the patient was still in remission (Fig. 2d).

### ACKNOWLEDGEMENTS

We gratefully acknowledge Tirsell Pty Ltd (Melbourne, Australia) for providing the products for the study. We gratefully acknowledge the patient and patient's parents for the permission to report her case.

### REFERENCES

1. Kamphuis S, Silverman ED. Prevalence and burden of pediatric-onset systemic lupus erythematosus. *Nat Rev Rheumatol* 2010; 6:538-46.
2. Hiraki LT, Benseler SM, Tyrrell PN, Harvey E, Hebert D, Silverman ED. Ethnic differences in pediatric systemic lupus erythematosus. *J Rheumatol* 2009; 36:2539-46.
3. Levy DM, Kamphuis S. Systemic lupus erythematosus in children and adolescents. *Pediatr Clin North Am* 2012; 59(2): 345-64.
4. Hiraki LT, Benseler SM, Tyrrell PN, Hebert D, Harvey E, Silverman ED. Clinical and laboratory characteristics and long-term outcome of pediatric systemic lupus erythematosus: a longitudinal study. *J Pediatr* 2008; 152:550-6.
5. Ramirez Gomez LA, Uribe Uribe O, Osio Uribe O, et al. Childhood systemic lupus erythematosus in Latin America. The GLADEL experience in 230 children. *Lupus* 2008; 17:596-604.
6. Sibbitt WL Jr, Brandt JR, Johnson CR, Maldonado ME, Patel SR, Ford CC, Bankhurst AD, Brooks WM. The incidence and prevalence of neuropsychiatric syndromes in pediatric onset systemic lupus erythematosus. *J Rheumatol* 2002; 29:1536-42.
7. Wang LC, Yang YH, Lu MY, Chiang BL. Retrospective analysis of mortality and morbidity of pediatric systemic lupus erythematosus in the past two decades. *J Microbiol Immunol Infect* 2003; 36:203-8.
8. Descloux E, Durieu I, Cochat P, Vital-Durand D,

- Ninet J, Fabien N, Cimaz R. Influence of age at disease onset in the outcome of paediatric systemic lupus erythematosus. *Rheumatology (Oxford)* 2009; 48:779-84.
9. Uziel Y, Gorodnitski N, Mukamel M, et al. Outcome of a national Israeli cohort of pediatric systemic lupus erythematosus. *Lupus* 2007; 16:142-6.
  10. Salah S, Lotfy HM, Sabry SM, El Hamshary A, Taher H. Systemic lupus erythematosus in Egyptian children. *Rheumatol Int* 2009; 29:1463-8.
  11. Lansdown AB et al. Zinc in wound healing: theoretical, experimental, and clinical aspects. *Wound Repair Regen* 2007; 15(1):2-16.
  12. Srivastava SK, Shankar E, Gupta S. Chamomile: A herbal medicine of the past with bright future; *Mol Med Report* 2010; 3(6):895-901.
  13. Shah M, Adams-Huet B, Kavanaugh A, Coyle Y, Lipsky P. Nutrient intake and diet quality in patients with systemic lupus erythematosus on a culturally sensitive cholesterol lowering dietary program. *J Rheumatol* 2004; 31(1):71-5.
  14. Chae BS, Shin TY, Kim DK, Eun JS, Leem JY, Yang JH. Prostaglandin E2-mediated dysregulation of proinflammatory cytokine production in pristane-induced lupus in mice. *Arch Pharmacol Res* 2008; 31:503-10.
  15. Chiung-Shu L et al. Rosmanol potently inhibits lipopolysaccharide-induced iNOS and COX-2 expression through downregulating MAPK, NF-KB, STAT3 and C/EBP signaling pathways. *J Agric Food Chem* 2009; 57:10990-8.
  16. Lv X, Zhao S, Ning Z, et al. Citrus fruits as a treasure trove of active natural metabolites that potentially provide benefits for human health. *Chemistry Central Journal* 2015; 9:68.



## SCALP PSORIASIS: A PROMISING NATURAL TREATMENT

U. WOLLINA<sup>1</sup>, J. HERCOGOVÁ<sup>2,3</sup>, M. FIORANELLI<sup>4</sup>, S. GIANFALDONI<sup>5</sup>, A.A. CHOKOEVA<sup>6,7</sup>, G. TCHERNEV<sup>8</sup>, M. TIRANT<sup>9</sup>, F. NOVOTNY<sup>10</sup>, M.G. ROCCIA<sup>11</sup>, G.K. MAXIMOV<sup>12</sup>, K. FRANÇA<sup>13,14</sup> and T. LOTTI<sup>15</sup>

<sup>1</sup>Academic Teaching Hospital Dresden-Friedrichstadt, Dresden, Germany; <sup>2</sup>2nd Medical Faculty, Charles University, Bulovka Hospital, <sup>3</sup>Institute of Clinical and Experimental Medicine, Prague, Czech Republic; <sup>4</sup>Department of Nuclear Physics, Sub-nuclear and Radiation, G. Marconi University, Rome, Italy; <sup>5</sup>Dermatological Department University of Pisa, Pisa, Italy; <sup>6</sup>"Onkoderma"-Polyclinic for dermatology and dermatologic surgery, Sofia, Bulgaria; <sup>7</sup>Department of Dermatology and Venereology, Medical University of Plovdiv, Medical faculty, Plovdiv, Bulgaria; <sup>8</sup>Medical Institute of Ministry of Interior (MVR), Department of Dermatology, Venereology and Dermatologic Surgery, Sofia, Bulgaria; <sup>9</sup>Psoriasis & Skin Clinic, Melbourne, Australia; <sup>10</sup>PRO SANUM Ltd, Sanatorium of Prof. Novotný, Štěpánská Prague 1, Czech Republic; <sup>11</sup>University B.I.S. Group of Institutions, Punjab Technical University, Punjab, India; <sup>12</sup>Department "Medicinal Information and Non-interventional studies", Bulgarian Drug Agency, Sofia, Bulgaria; <sup>13</sup>Department of Dermatology & Cutaneous Surgery, Department of Psychiatry & Behavioral Sciences, Institute for Bioethics & Health Policy, University of Miami, Miller School of Medicine, Miami, FL, USA; <sup>14</sup>Centro Studi per la Ricerca Multidisciplinare e Rigenerativa, Università Degli Studi "G. Marconi", Rome, Italy; <sup>15</sup>Chair of Dermatology, University of Rome "G. Marconi", Rome, Italy

Psoriasis is a lifelong chronic inflammatory disease affecting 2-3% of the worldwide population. Scalp psoriasis is a particular form of psoriasis characterized by lesions on the scalp, which may occur isolated or in association with other skin lesions. The aim of this study was to investigate the efficacy and safeness of an innovative treatment of scalp psoriasis, which is based on the topical application of natural products. Fifty adult subjects with scalp psoriasis (23 females, 27 males) from different European dermatological centres were included in the study. Forty-six patients with severely infiltrated psoriatic lesions were invited to use the products of Dr Michaels® (Soratinex®), according to a three-phase application, twice a day (morning and evening). The other 4 patients followed a different regimen: after a shampoo in the evening, they applied the conditioner in the night and washed it in the morning with the cleansing gel. The application time of Dr Michaels® (Soratinex®) products was 8 weeks. The treatment was evaluated at 0, 1, 2, 3, 4, 5, 6, 7, and 8 weeks. The evaluation was based on the Psoriasis Scalp Severity Index (PSSI) and on a photographic analysis at each of the medical evaluation points. At the end of the study, all patients showed an outstanding improvement. Five patients referred a transient pruritus, which regressed spontaneously without discontinuing the application. No other side effects have been described. We observe that Dr Michaels® (Soratinex®) natural product family can be considered as a valid therapeutic tool for scalp psoriasis when considering the exclusion criteria. The tested products provided an outstanding improvement of lesions in all the patients, without side effects.

Psoriasis (from the Greek word "psora"=scales) is a chronic inflammatory cell-mediated disease, primarily affecting skin and joints. It is a quite common disease, affecting about 1-3 % of worldwide

population (1, 2). About 50-100% of patients show involvement of the scalp, with lesions that can be isolated or associated to more common lesions on different skin areas (3, 4, 5).

*Key words: scalp psoriasis, topical treatments, natural products, effectiveness, safety*

Mailing address:  
Professor Torello Lotti,  
Department of Dermatology,  
University of Rome "G. Marconi",  
Rome, Italy  
e-mail: professor@torellolotti.it

103(S3)

0393-974X (2016)  
Copyright © by BIOLIFE, s.a.s.  
This publication and/or article is for individual use only and may not be further reproduced without written permission from the copyright holder.  
Unauthorized reproduction may result in financial and other penalties  
DISCLOSURE: ALL AUTHORS REPORT NO CONFLICTS OF INTEREST RELEVANT TO THIS ARTICLE.

The clinical features of scalp psoriasis are numerous (2, 4). In the majority of cases, we can observe the classic erythematous-scaly psoriatic lesions, localized on the hairline, in the occipital or in the post-auricular regions (2). Lesions may vary in size and number; in some cases, they are diffuse, involving all the scalp regions (2, 6). Some patients present only scaly (pityriasiform desquamation) or erythematous lesions (6).

Even if today there are several topical preparations for the treatment of scalp psoriasis, the corticosteroids, with or without vitamin D derivatives, are the drugs of first choice (6).

The aim of this study was to investigate the possibility of treating scalp psoriasis with the natural herbal products of Dr Michaels® (Soratinex®).

## MATERIALS AND METHODS

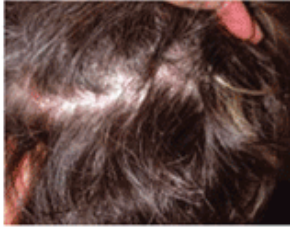
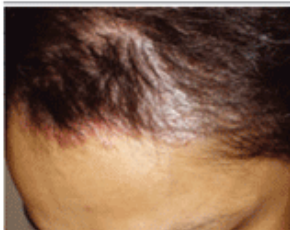

The study was conducted on a sample of 50 adult subjects (23 females, 27 males) from different European dermatological centers. Patients were aged between 18

and 64 years (mean age: 56 years) and had psoriasis limited to the scalp. Inclusion criteria: informed consent, age >18 years old, scalp psoriasis, cooperative patients. Exclusion criteria: psoriasis localized in other skin areas, psoriatic arthritis, systemic antipsoriatic drugs in the previous 3 months, use of topical products currently or in the previous two weeks, known allergic reactions to the components of the tested products.

Patients with severely infiltrated psoriatic lesions (46) were invited to use the products of Dr Michaels® (Soratinex®), according to a three-phase application, twice a day (morning and evening). The other 4 patients followed a different regimen: after a shampoo in the evening, they applied the conditioner in the night and washed it in the morning with the cleansing gel (table I).

The application period of Michaels® (Soratinex®) products was 8 weeks. The treatment was evaluated at 0, 1, 2, 3, 4, 5, 6, 7, and 8 weeks. The evaluation was based on the Psoriasis Scalp Severity Index (PSSI) and on photographic analysis at each of the medical evaluations points (table II).

*Scalp psoriasis should be graded according to a European consensus conference (2)*

Severity	Area	Indicated by the presence of one or more of:	Example
Mild	Affects < 50% of the scalp	Mild erythema Mild scaling Minimal thickness (barely detectable or no infiltration) Mild pruritus	
Moderate	Affects < 50% of the scalp	Moderate erythema Moderate scaling Moderate thickness (some infiltration) Mild to moderate pruritus	
Severe	Affects > 50% of the scalp	Severe erythema Severe scaling Very thick (extensive infiltration) Moderate to severe pruritus Evidence of hair loss with scarring Lesions not limited to the scalp (e.g. hairline or forehead involvement)	

The Psoriasis Scalp Severity Index (PSSI) measures:

- The extent of psoriasis involvement
- Severity of erythema
- Infiltration
- Desquamation of the scalp

Involvement and severity of psoriasis for the PSSI is scored using a scale from 0 to 72 (where 0=no psoriasis, and higher scores indicate more severe disease) (2).

### RESULTS:

The study was conducted on 50 patients (27 male, 23 female), with a mean age of 56 years. They had a mild to moderately severe form of scalp psoriasis, without lesions on different skin areas.

After 8 weeks using Dr Michaels® (Soratinex®) product family, all patients showed an outstanding improvement as depicted in Fig. 1-4.

During the protocol study, 5 patients referred a transient pruritus, which regressed spontaneously without discontinuing the application. No other side

effects have been described. Five patients with hair loss in the affected areas, showed marked hair re-growth following treatment (Fig 3a and 3b).

### CONCLUSIONS

Scalp psoriasis is a common skin disease, affecting more than 50% of psoriatic patients (1). To date, many topical and systemic treatments are available for its treatment. Current clinical guidelines suggest the use of systemic therapies (e.g. phototherapy, cyclosporine, acitretin, methotrexate, retinoids, biologic therapies, apremilast) only for patients with severe and recalcitrant disease, which did not achieve cosmetically pleasing results with medical treatments. Among topical treatments, steroids are considered to be the first-line therapy (6, 7).

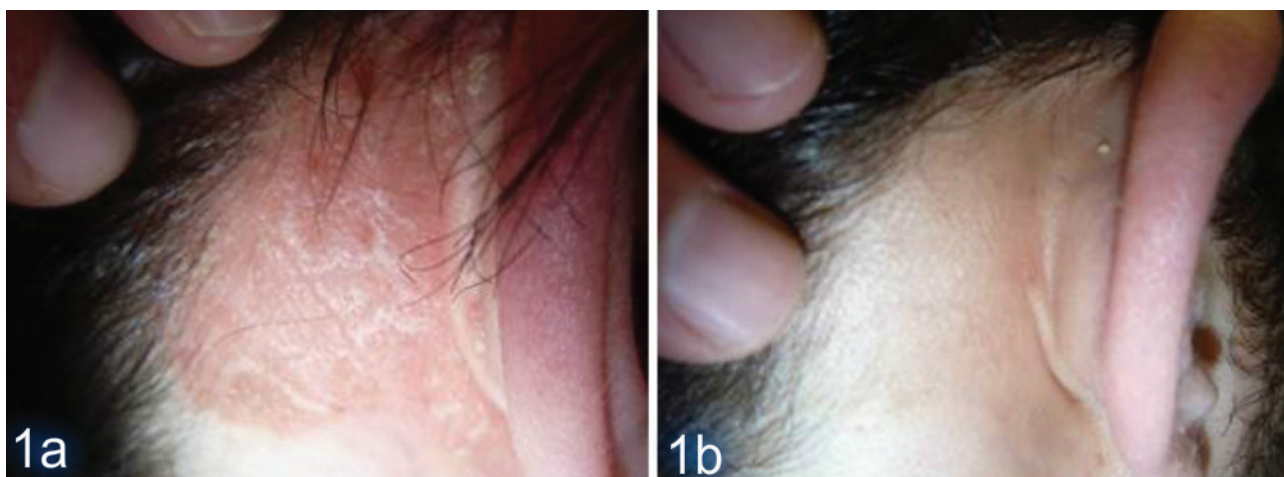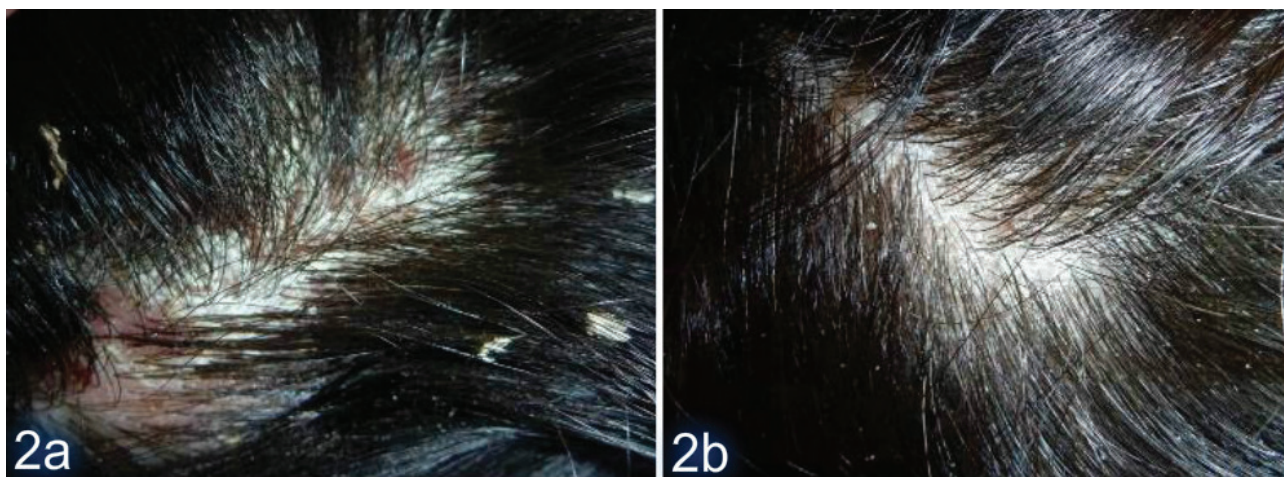
Corticosteroids (CSs) act as anti-inflammatory and immuno-suppressant agents (3). CSs could be used alone or in association with derivatives of vitamin D3, achieving better clinical results (8).

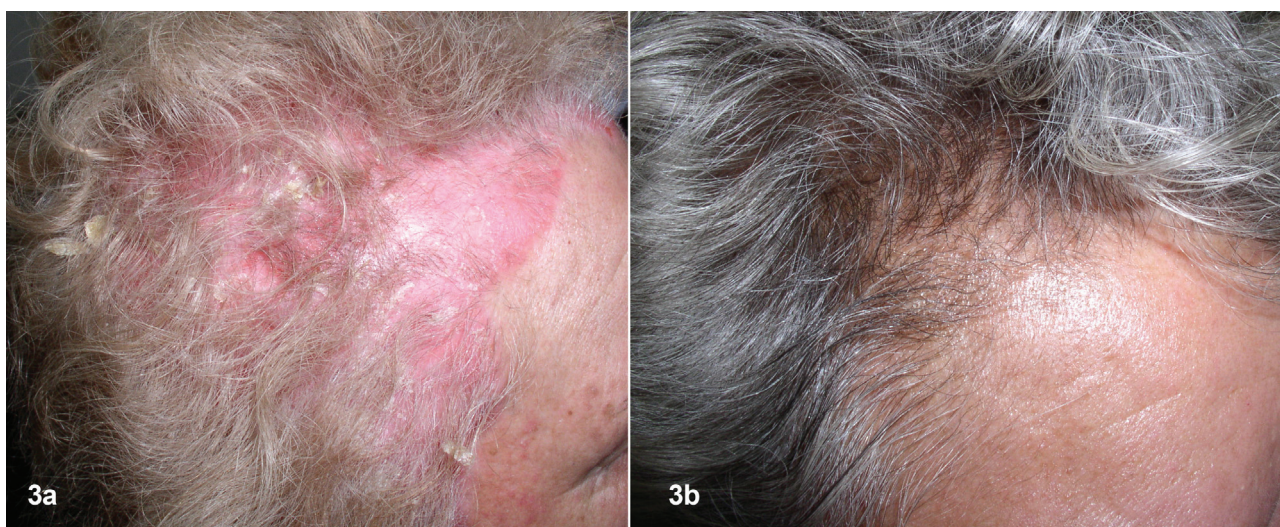
**Table I.** composition and modality of application of the tested products.

Scalp cleansing gel	Ingredients: salicylic acid, citric & glycolic acids Mode of use: Wet scalp and apply a small amount of cleansing gel. Massage thoroughly and leave for 2-3 minutes. Wash off with lukewarm water. (Can be applied to forehead but avoid cheek area).
Scalp ointment	Ingredients: Paraffinum liquidum, Paraffinum solidum, solanum tuberosum, Zinc oxide, Salicylic acid, Prunus amygdalus dulcis oil, Simmondsia chinensis oil, Persea gratissima oil, Daucus carota oil, Calendula officinalis extract, Citrus sinensis oil, Triticum vulgare germ oil, Prunus armeniaca kernel oil, Lavendula augustifolia, Santalum album oil, Pogostemon cablin oil, Pelargonium graveolens, Rosemary officinalis extract, Dromiceius oil, Citrus aurantium SSP bergamia oil, Pinus sylvestris leaf oil, Chamomilla recutita oil, Commiphora myrrha oil, Citrus aurantium amara flower oil Mode of use: Apply only onto severely infiltrated psoriatic plaques of the scalp after using and washing off the cleansing gel.
Skin conditioner	Ingredients: Olive oil, sesame seed oil, emu oil, lavender oil, eucalyptus oil, natural vitamin E. Mode of use: Applied to the psoriatic plaques two minutes after using the ointment (without washing it off). Mode of use without ointment: The conditioner is applied to the scalp at night and washed off in the morning using the cleansing gel. The conditioner is reapplied at night without washing the head, and washed off again using the cleansing gel in the morning.

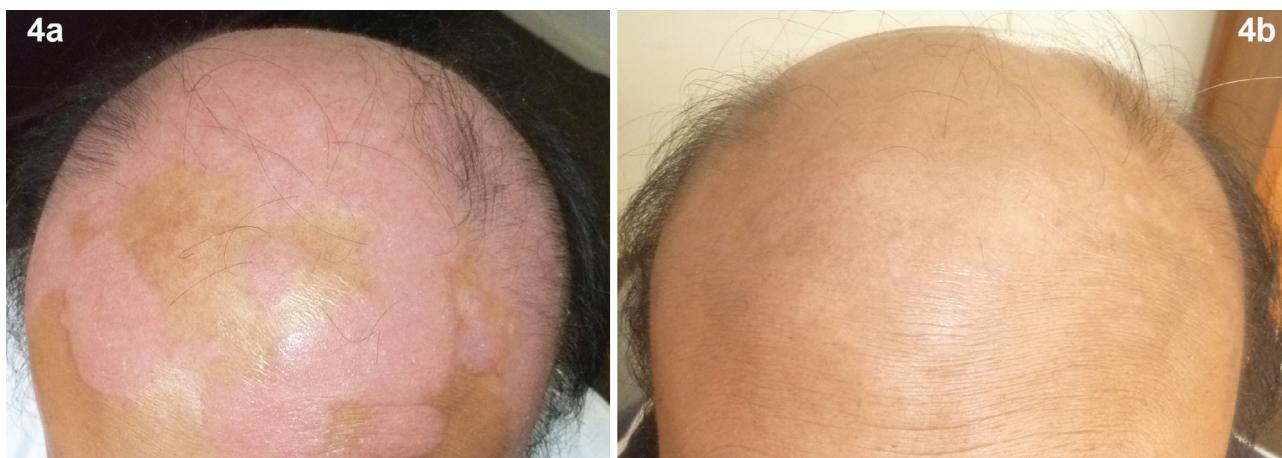**Table II.** PSSI evaluation.

Worsened	PSSI score higher than baseline
Not improved	PSSI decrease 0-25%
Moderate improvement	PSSI decrease 26-50%
Good improvement	PSSI decrease 51-75%
Outstanding improvement	PSSI decrease 76-100%

**Fig. 1. a):** 42 year- old man with scalp psoriasis before the protocol study; **b):** The same man after 6 weeks of treatment with Dr. Michaels® (Soratinex®) products.**Fig. 2. a):** 34 year- old woman with scalp psoriasis in the vertex area; **b):** The same woman after 6 weeks of treatment with the tested products.



**Fig. 3. a):** 68 year- old female with scalp psoriasis in the vertex area; **b):** The same woman after 8 weeks of treatment with the tested products, also showing new hair regrowth.



**Fig. 4. a):** 65 year- old male with scalp psoriasis in the vertex area; **b):** The same man after 8 weeks of treatment with the tested products.

Steroids are quite safe if used for few weeks, and, under this condition, they could be used also in children (8). Unfortunately, the treatment should be time-limited (no more than 2-4 months) to avoid percutaneous adsorption and local side effects such as epidermal atrophy, striae distensae, telangiectasia, hypertrichosis and, more rarely, acneiform eruption(8). Hypersensitivity reactions to corticosteroids have been also described (8).

In our experience, we observe that natural Michaels<sup>®</sup> (Soratinex<sup>®</sup>) product family can be

considered as a valid therapeutic tool for scalp psoriasis when considering the exclusion criteria. The tested products provided an outstanding improvement of lesions in all the patients, without side effects and in some cases, improved hair regrowth was noticeable.

#### ACKNOWLEDGEMENTS

We gratefully acknowledge Tirsell Pty Ltd (Melbourne, Australia) and Frankl Pharma Global

Ltd. (2 Parklands Place, Guilford, Surrey, United Kingdom) for providing the products for the studies.

#### REFERENCES

1. Naldi L. Epidemiology of psoriasis. *Curr Drug Targets Inflamm Allergy* 2004; 3(2):121-8.
2. Ortonne J, Chimenti S, Luger T, Puig L, Reid F, and Trueb R. Scalp psoriasis: European consensus on grading and treatment algorithm. *J Eur Acad Dermatol Venereol* 2009; 23:1435-44.
3. Lotti T, Hercogova J, Prignano F. The concept of psoriatic disease: can cutaneous psoriasis any longer be separated by the systemic comorbidities? *Dermatol Ther* 2010; 23(2):119-22.
4. Lotti T [Successful combination treatment for psoriasis with phototherapy and low-dose cytokines: A spontaneous, retrospective observational clinical study]. *Hautarzt* 2015; 66(11):849-54.
5. Scarpa R, Altomare G, Marchesoni A, et al. Psoriatic disease: concepts and implications. *J Eur Acad Dermatol Venereol* 2010; 24(6):627-30.
6. Schlager JG, Rosumeck S, Werner RN, et al. Topical treatments for scalp psoriasis. *Cochrane Database Syst Rev* 2016; 2:CD009687.
7. Tyring S, Bagel J, Lynde C, et al. Patient-reported outcomes in moderate-to-severe plaque psoriasis with scalp involvement: results from a randomized, double-blind, placebo-controlled study of etanercept. *J Eur Acad Dermatol Venereol* 2013; 27:125-8.
8. Jemec GBE, Ganslandt C, Ortonne JP, et al. A new scalp formulation of calcipotriene plus betamethasone compared with its active ingredients and the vehicle in the treatment of scalp psoriasis: a randomized double blind, controlled trial. *J Am Acad Dermatol* 2008; 59:455-63.

## AN INNOVATIVE, PROMISING TOPICAL TREATMENT FOR PSORIASIS: A ROMANIAN CLINICAL STUDY

S. GIANFALDONI<sup>1</sup>, J. HERCOGOVÁ<sup>2,3</sup>, M. FIORANELLI<sup>4</sup>, A.A. CHOKOEVA<sup>5,6</sup>, G.  
TCHERNEV<sup>7</sup>, U.WOLLINA<sup>8</sup>, M. TIRANT<sup>9</sup>, F. NOVOTNY<sup>10</sup>, M.G. ROCCIA<sup>11</sup>,  
G.K. MAXIMOV<sup>12</sup>, K. FRANÇA<sup>13,14</sup> and T. LOTTI<sup>15</sup>

<sup>1</sup>Dermatological Department University of Pisa, Pisa, Italy; <sup>2</sup>2nd Medical Faculty, Charles University, Bulovka Hospital, <sup>3</sup>Institute of Clinical and Experimental Medicine, Prague, Czech Republic; <sup>4</sup>Department of Nuclear Physics, Sub-nuclear and Radiation, G. Marconi University, Rome, Italy; <sup>5</sup>"Onkoderma"-Polyclinic for dermatology and dermatologic surgery, Sofia, Bulgaria; <sup>6</sup>Department of Dermatology and Venereology, Medical University of Plovdiv, Medical faculty, Plovdiv, Bulgaria; <sup>7</sup>Medical Institute of Ministry of Interior (MVR), Department of Dermatology, Venereology and Dermatologic Surgery, Sofia, Bulgaria; <sup>8</sup>Department of Dermatology and Allergology, Academic Teaching Hospital Dresden-Friedrichstadt, Dresden, Germany; <sup>9</sup>Psoriasis & Skin Clinic, Melbourne, Australia; <sup>10</sup>PRO SANUM Ltd, Sanatorium of Prof. Novotný, Štěpánská Prague 1, Czech Republic; <sup>11</sup>University B.I.S. Group of Institutions, Punjab Technical University, Punjab, India; <sup>12</sup>Department "Medicinal Information and Non-interventional studies", Bulgarian Drug Agency, Sofia, Bulgaria; <sup>13</sup>Department of Dermatology & Cutaneous Surgery, Department of Psychiatry & Behavioral Sciences, Institute for Bioethics & Health Policy, University of Miami, Miller School of Medicine, Miami, FL, USA; <sup>14</sup>Centro Studi per la Ricerca Multidisciplinare e Rigenerativa, Università Degli Studi "G. Marconi", Rome, Italy; <sup>15</sup>Chair of Dermatology, University of Rome "G. Marconi" Rome, Italy

Psoriasis is a chronic inflammatory disease with negative impacts both physically and psychologically. It is a common disorder affecting 2-3% of the total world population, in some cases causing changes to the nail and joints as well as skin lesions. The cutaneous manifestations of psoriasis can vary in morphology and severity and therapy should be tailored accordingly. Even if today many therapeutic options are available for psoriasis treatment, none of them provide excellent clinical results without the risk of side effects. The authors investigate the efficacy of Dr. Michaels® (Soratinex®) natural products in the topical treatments of a group of psoriatic patients. Sixty-two patients (34 male/28 female) from Romania, aged 18-70 years (mean age: 52 years), affected by a mild to severe form of chronic plaque psoriasis were included in this study. Each patient has been treated with a triphasic application of Dr. Michaels® (Soratinex®) natural products, twice a day for six weeks. The products were applied on skin and scalp lesions, but not on the face, genital and flexures. The evaluation of the tested products was based on the PASI of each patient at time 0, 1, 2, 3, 4, 5, and 6 weeks. The tested products were ineffective in five of 57 patients. Eleven patients had a moderate improvement (PASI decrease 26-50%); 11 patients had a good improvement (PASI decrease 51-75%) and 30 patients an outstanding one (PASI decrease 76-100%). Twenty-three% of patients developed folliculitis that regressed upon discontinuation of the application. Five patients developed pruritus, which regressed spontaneously. The cosmetic effect was evaluated as indifferent by 44% of patients, as good by 40 % of patients and as excellent by 16% of patients. Ninety-five% of patients stated that they would continue to use the tested products, because it was effective and with poor side effects since the products were natural. In our experimental study, the topical application of Dr. Michaels® (Soratinex®) natural products proved to be an effective natural therapeutic option for psoriasis treatment.

*Key words: psoriasis, topical treatment, natural products*

Mailing address:  
Professor Torello Lotti,  
Department of Dermatology,  
University of Rome "G. Marconi",  
Rome, Italy  
e-mail: professor@torellolotti.it

109(S3)

0393-974X (2016)  
Copyright © by BIOLIFE, s.a.s.  
This publication and/or article is for individual use only and may not be further reproduced without written permission from the copyright holder.  
Unauthorized reproduction may result in financial and other penalties  
DISCLOSURE: ALL AUTHORS REPORT NO CONFLICTS OF INTEREST RELEVANT TO THIS ARTICLE.

Psoriasis is a common chronic, recurring, inflammatory autoimmune disease, primarily affecting skin and joints (1). Genetic predisposition as well as provoking factors play an important role in its etiology (1). The clinical presentation of psoriasis is variable, but the commonest is the plaque psoriasis, which is characterized by raised, erythematous round or oval lesions, covered by white silvery scales (2). Even if lesions can be localized in any area of skin surface, they are more commonly described on the elbows, knees, scalp, and lumbar-sacral region in a symmetric pattern (2).

Although many topical and systemic treatment options are now available (Table I), none of them provide excellent clinical results without the risk of side effects (2, 3).

#### *Aim of the study*

We investigated the efficacy of Dr. Michaels® (Soratinex®) natural products in the topical treatments of psoriasis.

## MATERIALS AND METHODS

We investigated the efficacy of the tested products in 62 patients (34 male/ 28 female), from Romania. Patients, aged 18- 70-years-old (mean age: 52 years), were affected

by a mild to severe form of chronic plaque psoriasis.

Inclusion criteria: age >18 years old, mild to severe psoriasis without complications, no other current anti-psoriatic therapy, signed informed consent.

Exclusion criteria: pustular and erythrodermic psoriasis, systemic antipsoriatic therapies within the past 3 months or topical therapies in the last 2 weeks, known hypersensitivity to any of the components of the products, low compliance of patients.

Each patient was treated with a triphasic application of Dr. Michaels® (Soratinex®) natural products (Table II), twice a day for 6 weeks. In detail, after using the cleansing oil, patients had to apply an ointment and successively a skin conditioner. The products were applied on skin and scalp lesions, but not on the face, genital and flexures.

The evaluation of the tested products was based on the PASI of each patient at time 0, 1, 2, 3, 4, 5 and 6 weeks (Table III).

The recording of side effects began on week 3. The tolerability of the tested products was evaluated at the end of the study, based on the patients' statements.

## RESULTS

The study was completed in 57 patients; 4 patients dropped out for lack of compliance, 1 for lack of signed informed consent. Fig. 1 and 2 show

**Table I.** *Psoriasis therapeutic options.*

TOPICAL TREATMENTS: corticosteroids, derivates of vitamins D, salicylic acid, alpha-hydroxy acids, anthralin, emollients, tars, retinoids, calcineurin inhibitors
SYSTEMIC TREATMENTS: corticosteroids, retinoids, cyclosporin A, methotrexate, low dose cytokines, fumarates
LIGHT THERAPY: UVA, PUVA, bath-PUVA, narrow-band UVB, excimer laser or light
BIOLOGIC TREATMENTS: infliximab, adalimumab, etanercept, golimumab, tofacitinib, ustekinumab, secukinumab, ixekizumab, brodalumab
COMBINATION THERAPIES

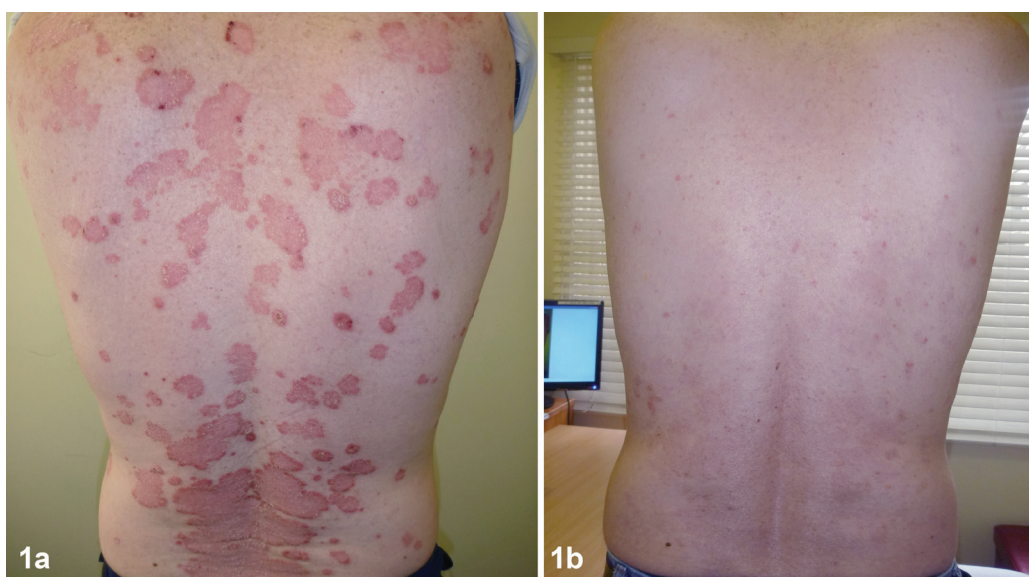


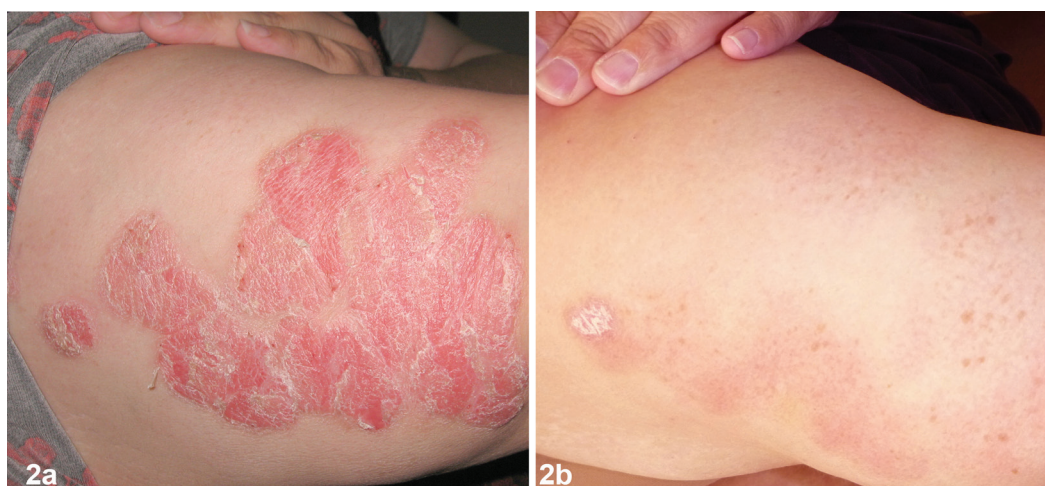**Table II.** Ingredients of Dr. Michaels® (Soratinex®) products.

Dr. Michaels® (Soratinex®) Scalp and Body Cleansing Gel	Ingredients: salicylic acid, citric & glycolic acids
Dr. Michaels® (Soratinex®) Scalp and Body Ointment	Ingredients: <i>Paraffinum liquidum</i> , <i>Paraffinum solidum</i> , <i>solanum tuberosum</i> , Zinc oxide (C.I. 77947) Salicylic acid, <i>Prunus amygdalus dulcis</i> oil, <i>Simmondsia chinensis</i> oil, <i>Persea gratissima</i> oil, <i>Daucus carota</i> oil, <i>Calendula officinalis</i> extract, <i>Citrus sinensis</i> oil, <i>Triticum vulgare</i> germ oil, <i>Prunus armeniaca</i> kernel oil, <i>Lavendula augustifolia</i> , <i>Santalum album</i> oil, <i>Pogostemon cablin</i> oil, <i>Pelargonium graveolens</i> , Rosemary <i>officinalis</i> extract, <i>Dromiceius</i> oil, <i>Citrus aurantium</i> SSP <i>bergamia</i> oil, <i>Pinus sylvestris</i> leaf oil, <i>Chamomilla recutita</i> oil, <i>Commiphora myrrha</i> oil, <i>Citrus aurantium amara</i> flower oil.
Dr. Michaels® (Soratinex®) Skin Conditioner	Ingredients: Olive oil, sesame seed oil, emu oil, lavender oil, eucalyptus oil, natural vitamin E.

**Table III.** Evaluation of improvement.

Worsened	PASI score higher than baseline
No improvement	PASI decrease 0-25%
Moderate improvement	PASI decrease 26-50%
Good improvement	PASI decrease 51-75%
Outstanding improvement	PASI decrease 76-100%

**Fig. 1. a):** Week 0 - 35-year-old male before treatment with Dr. Michaels® (Soratinex®) product family; **Fig. b):** Week 8 - 35-year-old male after treatment with Dr. Michaels® (Soratinex®) product family.



**Fig. 2. a):** Week 0 – 48-year-old female before treatment with Dr. Michaels® (Soratinex®) product family; **b):** Week 8 – 48-year-old female after treatment with Dr. Michaels® (Soratinex®) product family.

the photographs of before and after treatment with Dr Michaels product family.

The tested products proved to be ineffective in five of 57 patients. Eleven patients had a moderate improvement (PASI decrease 26-50%), 11 patients had a good improvement (PASI decrease 51-75%) and 30 patients an outstanding one (PASI decrease 76-100%).

During the protocol study, 23% of patients developed folliculitis that regressed upon discontinuation of the application. Five patients developed pruritus, which regressed spontaneously.

The cosmetic effect was evaluated as indifferent by 44% of patients, as good by 40% of patients and as excellent by 16% of patients. Ninety-five% of patients stated that they would continue to use the tested products, because it was effective and with minor side effects.

## DISCUSSION

Topical treatment of psoriasis had been limited to corticosteroids, derivatives of vitamins D, salicylic acid, alpha-hydroxy acids, anthralin, emollients, tars, retinoids, calcineurin inhibitors and combined therapies.

The majority of patients have mild-to-moderate psoriasis, amenable to topical treatment. Self-

treatment offers more therapeutic independence to patients.

The authors investigated the efficacy of a herbal remedy the treatment of mild to moderate psoriasis. The majority of patients presented a good improvement with the therapy and considered the treatment effective.

## CONCLUSION

Psoriasis is a common inflammatory condition of the skin affecting approximately 1% to 3% of general population (1). It is a chronic recurrent disorder, associated with impaired physical and psychosocial functioning (4).

Treatment selection is determined by the severity and location of the psoriasis as well as medication side effects, patient preferences and compliance, and financial constraints (5). To date many topical and systemic treatment options are now available, but none of them provide excellent clinical results without the risk of side effects (5).

In our experimental study, the topical application of Dr. Michaels® (Soratinex®) natural products provided to be an effective natural therapeutic option for psoriasis treatment. We observed a moderate improvement in 11 patients, a good one in 11 patients and an outstanding one in 30 subjects. The products

were well-tolerated by patients and many of them wanted to continue the treatment.

#### ACKNOWLEDGEMENTS

We gratefully acknowledge Tirsell Pty Ltd (Melbourne, Australia) and Frankl Pharma Global Ltd. (2 Parklands Place, Guilford, Surrey, United Kingdom) for providing the products for the studies.

#### REFERENCES:

1. Lotti T. Successful combination treatment for psoriasis with phototherapy and low-dose cytokines: A spontaneous, retrospective observational clinical study. *Hautarzt* 2015; 66(11):849-54.
2. Stein Gold LF. Topical therapies for psoriasis: improving management strategies and patient adherence. *Semin Cutan Med Surg* 2016; 35(2S2):S36-44; quiz S45.
3. Gisondi P, Di Mercurio M, Idolazzi L, et al. Concept of remission in chronic plaque psoriasis. *J Rheumatol Suppl* 2015; 93:57-60.
4. Mease PJ, Menter MA. Quality-of-life issues in psoriasis and psoriatic arthritis: outcome measures and therapies from a dermatological perspective. *J Am Acad Dermatol* 2006; 54(4):685-704.
5. Gelfand JM, Weinstein R, Porter SB, Neimann AL, Berlin JA, Margolis DJ. Prevalence and treatment of psoriasis in the United Kingdom: a population-based study. *Arch Dermatol* 2005; 141(12):1537-41.



## EFFICACY AND SAFETY OF DR MICHAELS® (SORATINEX®) PRODUCT FAMILY FOR THE TOPICAL TREATMENT OF PSORIASIS: A MONITORED STATUS STUDY

K. FRANÇA<sup>1,13</sup>, F. NOVOTNY<sup>2</sup>, J. HERCOGOVÁ<sup>3,4</sup>, M. FIORANELLI<sup>5</sup>, S. GIANFALDONI<sup>6</sup>, A.A. CHOKOEVA<sup>7,8</sup>, G. TCHERNEV<sup>9</sup>, U. WOLLINA<sup>10</sup>, M. TIRANT<sup>11</sup>, M.G. ROCCIA<sup>12</sup> and T. LOTTI<sup>14</sup>

<sup>1</sup>Department of Dermatology & Cutaneous Surgery, Department of Psychiatry & Behavioral Sciences, Institute for Bioethics & Health Policy, University of Miami, Miller School of Medicine, Miami, FL, USA; <sup>2</sup>PRO SANUM Ltd, Sanatorium of Prof. Novotný, Štěpánská Prague 1, Czech Republic; <sup>3</sup>2nd Medical Faculty, Charles University, Bulovka Hospital, <sup>4</sup>Institute of Clinical and Experimental Medicine, Prague, Czech Republic; <sup>5</sup>Department of Nuclear Physics, Sub-nuclear and Radiation, Guglielmo Marconi University, Rome, Italy; <sup>6</sup>Dermatological Department University of Pisa, Pisa, Italy; <sup>7</sup>"Onkoderma"-Policlinic for dermatology and dermatologic surgery, Sofia, Bulgaria; <sup>8</sup>Department of Dermatology and Venereology, Medical University of Plovdiv, Medical faculty, Plovdiv, Bulgaria; <sup>9</sup>Medical Institute of Ministry of Interior (MVR), Department of Dermatology, Venereology and Dermatologic Surgery, Sofia, Bulgaria; <sup>10</sup>Department of Dermatology and Allergology, Academic Teaching Hospital Dresden-Friedrichstadt, Dresden, Germany; <sup>11</sup>Psoriasis & Skin Clinic, Melbourne, Australia; <sup>12</sup>University B.I.S. Group of Institutions, Punjab Technical University, Punjab, India; <sup>13</sup>Centro Studi per la Ricerca Multidisciplinare e Rigenerativa, Università Degli Studi "G. Marconi", Rome, Italy; <sup>14</sup>Chair of Dermatology, University of Rome "G. Marconi" Rome, Italy

The aim of the study was to investigate the efficacy and safety of Michaels® (Soratinex®) remedies in patients suffering from chronic plaque psoriasis in a Czech population. 75 (34 female/41 male) patients, aged 18-72 years old (mean age: 38.5 years) with mild to severe plaque psoriasis participated in the study. The products, including cleansing gel, ointment and skin conditioner, containing fruit acid complex, herbal oils and emulsifiers, were used twice daily and in the same manner for all the skin lesions. The study period was eight weeks. Histologic variables and various blood picture parameters, including FW, glucose, cholesterol, triacylglyceroles, bilirubin, GMT, ALT, AST, creatinine, uric acid and urea in blood were monitored, before and after therapy with Michaels® (Soratinex®) treatment. Assessment, using the Psoriasis Activity Severity Index (PASI) scores and photographic analysis, was done at time 0, and after 2, 4, 6 and 8 weeks. Patient's improvement was determined by the percentage reduction of the PASI scores. Side effects and tolerability were also evaluated. After 8 weeks using Dr Michaels® (Soratinex®) treatment course, 5 patients had a moderate improvement, with the resolution of 25-50% of skin lesions; 11 patients showed a good improvement, with the resolution of 51-75% of lesions. Another 50 patients had an outstanding improvement, with the regression of 76-100% of lesions. Only 4 patients did not achieve an improvement of psoriasis. Six patients experienced folliculitis, which resolved without cessation of treatment. Three patients worsened and discontinued treatment. Six patients dropped out because of non-compliance. The blood results and histologic findings were all normal. Our investigation shows that Dr Michaels® (Soratinex®) products can be safely and successfully used in the treatment of chronic plaque psoriasis.

Psoriasis is a chronic, remitting and relapsing, T-cell mediated, inflammatory skin disorder, with genetic predisposition as well as triggering factors playing roles in its etiology (1). It affects 1 to 3%

of the world population, can start at any age, and has no gender preference. (2) It is a non-infectious disease that affects all regions of the body, but more commonly, it involves the scalp and extensor

*Key words: psoriasis, plaque psoriasis, herbal products, safety, efficacy, patient satisfaction*

Mailing address:  
Professor Torello Lotti,  
Department of Dermatology,  
University of Rome "G. Marconi",  
Rome, Italy  
e-mail: professor@torelloLotti.it

0393-974X (2016)

Copyright © by BIOLIFE, s.a.s.

This publication and/or article is for individual use only and may not be further reproduced without written permission from the copyright holder.

Unauthorized reproduction may result in financial and other penalties  
**DISCLOSURE: ALL AUTHORS REPORT NO CONFLICTS OF INTEREST RELEVANT TO THIS ARTICLE.**

surfaces of the extremities. Most patients present plaque psoriasis or psoriasis vulgaris. This disease is associated with other several comorbidities such as psoriatic arthritis, cardiovascular and metabolic diseases (3, 4). There is no cure for psoriasis. It is a disease that requires control to relieve the symptoms and minimize the development of new lesions (5). The first line treatments for mild to moderate and localized lesions are topical products (6, 7).

The aim of this study was to investigate and to describe the efficacy and safety of Dr Michaels® (Soratinex®) skin-care products for the topical treatment of stable chronic plaque psoriasis, in a Czech population.

## MATERIALS AND METHODS

After obtaining written consent, 75 patients (34 female/41 male), aged 18- 72-years-old (mean age: 38.5 years) participated in the study. All patients had a mild to moderate severe plaque psoriasis. Inclusion and exclusion criteria used are shown in Table I.

The products were used twice daily and in the same manner for all skin lesions. First, patients had to use a cleansing gel containing salicylic acid, fruit acid complex and emulsifiers. After 5 min, the gel was washed off and lesions were covered with an ointment, composed of herbal extracts and essential oils in a petroleum base. After the ointment was absorbed into the plaques, the

plaques were then covered with a thin layer of oil.

The study period was 8 weeks. Histologic variables and various blood picture parameters, including FW, glucose, cholesterol, triacylglyceroles, bilirubin, GMT, ALT, AST, creatinine, uric acid and urea in blood were monitored, before and after therapy with Michaels® (Soratinex®) treatment.

Assessment, using the Psoriasis Activity Severity Index (PASI) scores (8) (Fig. 1) and photographs analysis, was done at time 0, and after 2, 4, 6 and 8 weeks. Patient improvement was determined by the percentage reduction of the PASI scores. Side effects and tolerability were also evaluated.

## RESULTS

The data presented here are the results of a group of 75 patients (34 female/41 male) who undertook an 8-week treatment course using Dr Michaels® (Soratinex®) product family. Six patients were excluded because of non-compliance and 3 patients worsened and discontinued treatment. Six patients developed folliculitis, which resolved without cessation of treatment. Four patients did not have an improvement. Five patients had a moderate improvement, with the regression of 25-50% of skin lesions; 11 patients had a good improvement, with the resolution of 51-75% of lesions. Fifty patients had an outstanding improvement, with 76-100%

**Table I:** *Criteria for patient selection.*

Inclusion criteria	<ul style="list-style-type: none"> <li>▪ Mild to severe psoriasis without complications.</li> <li>▪ Both genders, age above 18.</li> <li>▪ No other current anti-psoriatic therapy.</li> <li>▪ Signed informed consent.</li> </ul>
Exclusion criteria	<ul style="list-style-type: none"> <li>▪ Pustular and erythrodermic psoriasis.</li> <li>▪ Systemic, acitretin, cyclosporine, methotrexate, light therapy currently or within the past 3 months.</li> <li>▪ Topical anti-psoriatic therapy.</li> <li>▪ Pregnancy, breast feeding.</li> <li>▪ Known hypersensitivity to any of the components of the products.</li> <li>▪ Lack of informed consent.</li> <li>▪ Low compliance.</li> </ul>

Score	0	1	2	3	4
Erythema	0=none	1=mild	2=moderate	3=severe	4=very severe
Infiltration	0=none	1=mild	2=moderate	3=severe	4=very severe
Scaling	0=none	1=mild	2=moderate	3=severe	4=very severe

Score	0	1	2	3	4	5	6
Area	0	<10	10<30	30<50	50<70	70<90	90<100

Fig. 1. PASI score.

reduction of lesions. Before treatment, the mean PASI score was 18.6+/-3.7 SD and was 3.1+/-1.6 SD after an 8- week treatment course. This represents 89 % reduction in PASI scores.

Fig. 1 and 2 show patient photographs of before and after treatment, with total resolution of lesions after week 8 of treatment. The treatment was well tolerated. Fig. 3 shows the change in PASI scores across 8 weeks of treatment.

## DISCUSSION

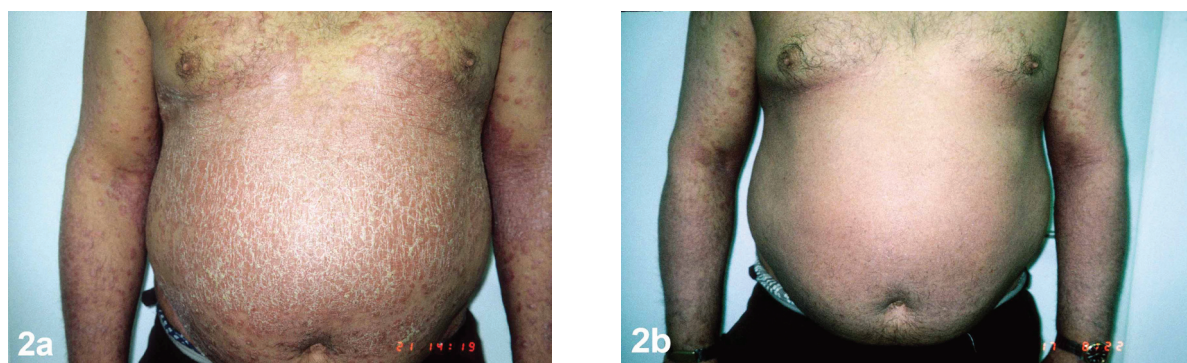
The authors compared the results of Dr Michaels<sup>®</sup> (Soratinex<sup>®</sup>) remedies with other local methods,

showing an 89% reduction in PASI scores. External corticoids gave positive results on average of 72%, analogues of vitamin D3 on average of 79% and phototherapy of 83%.

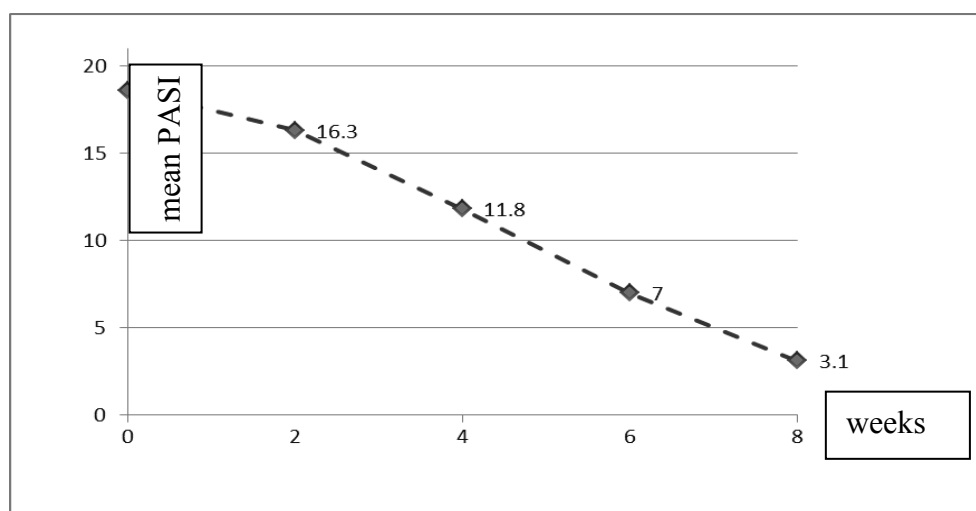
The tolerance of the therapy was very good. We noted side effects such as temporary burning in the beginning of the therapy in about 8% of cases under review. We did not observe any internal side effects, while the laboratory tests, mainly hepatic and renal functions, at the start of the study had normalized after the withdrawal of methotrexate, cyclosporine A and retinoids. In our study, we monitored laboratory values of blood picture, FW, glucose, cholesterol, triacylglycerols, bilirubin, GMT, ALT, AST,

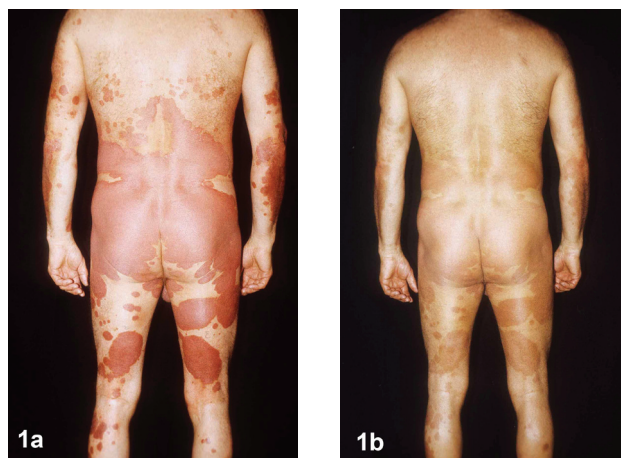

Fig 1. a): Week 0 - Before treatment. b): Week 6 - After treatment with Dr Michaels (Soratinex<sup>®</sup>) product family. 38-year-old male patient with psoriasis for 8 years. Presenting these lesions over the past 2 years. Previously, he was treated with cyclosporine A, without major improvement. Creatinine level had increased to 280 mmol/l, blood pressure 180/90 mm Hg. Patient had used 3 sets of the Dr Michaels product family. The treatment was 90% effective and the tolerance was good. Slight hyperpigmentation remained. At week 6 the laboratory test showed that creatinine decreased to 128 mmol/l and blood pressure to 160/75 mm Hg. Histological findings were normal.



**Fig. 2. a):** Week 0 - Before treatment. **b):** Week 8 - After treatment with Dr Michaels (Soratinex®) product family. 56-year-old male patient with psoriasis for 20 years presenting these lesions over the past year. The patient reported penicillin and sulfasalazin allergies. Previous treatments included methotrexate, cyclosporine A, sedatives and locally, preparations with urea and dithranol with temporary beneficial effects; The patient also presented minimal articular disorders He used 3 sets of the Dr Michaels product family. His levels of creatinine decreased from 320 mmol/l to 130 mmol/l. The blood pressure normalized without any other treatment. The level of cholesterol remained on 6.8 mmol/L. Histological finding was completely normal at week 8.



**Fig. 3.** Summarised change of (mean) PASI score in 75 patients.

creatinine, uric acid and urea in blood. We did not see any impairment.

Interesting was the persistence of the remissions. The authors monitored a lull period in 65 cases for at least one year and relapses of small extent occurred just in 30% of monitored cases. While the relapses show up in patients suffering from psoriasis treated by local corticoids on average in 1 to 2 months, patients treated internally with methotrexate, cyclosporine A, retinoids and biological preparations, roughly in 3 months. The repetition of the treatment by Dr

Michaels® (Soratinex®) preparations appears to be equally successful, while with other methods, when we repeated the same therapy, the success decreased.

The satisfaction of the patients was exceptional. The patients, compared to previous therapies, better evaluated Dr Michaels® (Soratinex®) remedies. The beginning of the effects already started after 3 to 5 weeks. The histological findings eventuated in normalization.

The mechanism of actions of Dr Michaels® (Soratinex®) preparations is believed to be a



synergistic effect from the different components. There is a keratolytic and superficial effect of fruit acids, as in cosmetic peeling. The plant extracts provide anti-inflammatory properties. This is the impulse for the healing process, which arises from the basal cells of the skin. Other components such as zinc oxide, evening primrose oil and tea tree oil, also impart cellular healing benefit. Lauryl sulphate helps the penetration into the epidermis. Psychotherapy and confidence in a new efficient remedy are also important in the healing process.

### CONCLUSION

Our investigation demonstrates that Dr. Michaels® (Soratinex®) products can be used safely and successfully in the treatment of stable chronic plaque psoriasis. Good to outstanding improvement was observed in the predominant percentage of the cases, while the products were well tolerated, without occurrence of contact sensitization.

### ACKNOWLEDGEMENTS

We gratefully acknowledge Tirsell Pty Ltd (Melbourne, Australia) and Frankl Pharma Global Ltd. (2 Parklands Place, Guilford, Surrey, United Kingdom) for providing the products for the studies.

### REFERENCES

1. Bowcock AM, Cookson WOCM. The genetics of psoriasis, psoriatic arthritis and atopic dermatitis; *Human Molecular Genetics* 2004; 13(1):R43-R55.
2. Lotti T. [Successful combination treatment for psoriasis with phototherapy and low-dose cytokines: A spontaneous, retrospective observational clinical study]. *Hautarzt* 2015; 66(11):849-54.
3. Gerdes S, Mrowietz U, Boehncke WH. [Comorbidity in psoriasis]. *Hautarzt* 2016; 67(6):438-44.
4. Jurado-Santa Cruz F, Páez-Agraz F. From evidence to expertise: concordance in the topical management of psoriasis. *Rev Med Inst Mex Seguro Soc* 2016; 54(3):304-11.
5. Jacobi A, Mayer A, Augustin M. Keratolytics and emollients and their role in the therapy of psoriasis: a systematic review. *Dermatol Ther Heidelb* 2015; 5(1):1-18.
6. Mason AR, Mason J, Cork M, Dooley G, Edwards G. Topical treatments for chronic plaque psoriasis. *Cochrane Database Syst Rev*. 2009; (2):CD005028.
7. Carrascosa JM et al. [Update of the topical treatment of psoriasis]. *Actas Dermosifiliogr*. 2009; 100(3):190-200.
8. Langley RG, Ellis CN: Evaluating psoriasis with Psoriasis Area and Severity Index, Psoriasis Global Assessment, and Lattice System Physician's Global Assessment. *J Am Acad Dermatol* 2004; 51:563-9.



## QUALITY OF LIFE ASPECTS OF PATIENTS WITH PSORIASIS USING A SERIES OF HERBAL PRODUCTS

K. FRANÇA<sup>1,13</sup>, M. TIRANT<sup>2</sup>, J. HERCOGOVÁ<sup>3,4</sup>, F. NOVOTNY<sup>5</sup>, M. FIORANELLI<sup>6</sup>, S. GIANFALDONI<sup>7</sup>, A.A.CHOKOEVA<sup>8,9</sup>, G. TCHERNEV<sup>10</sup>, U.WOLLINA<sup>11</sup>, M.G. ROCCIA<sup>12</sup> and T. LOTTI<sup>14</sup>

<sup>1</sup>Department of Dermatology & Cutaneous Surgery, Department of Psychiatry & Behavioral Sciences, Institute for Bioethics & Health Policy, University of Miami, Miller School of Medicine, Miami, FL, USA; <sup>2</sup>Psoriasis & Skin Clinic, Melbourne, Australia; <sup>3</sup>2nd Medical Faculty, Charles University, Bulovka Hospital, <sup>4</sup>Institute of Clinical and Experimental Medicine, Prague, Czech Republic; <sup>5</sup>PRO SANUM Ltd, Sanatorium of Prof. Novotný, Štěpánská Prague I, Czech Republic; <sup>6</sup>Department of Nuclear Physics, Sub-nuclear and Radiation, G. Marconi University, Rome, Italy; <sup>7</sup>Dermatological Department University of Pisa, Pisa, Italy; <sup>8</sup>"Onkoderma"-Policlinic for dermatology and dermatologic surgery, Sofia, Bulgaria; <sup>9</sup>Department of Dermatology and Venereology, Medical University of Plovdiv, Medical faculty, Plovdiv, Bulgaria; <sup>10</sup>Medical Institute of Ministry of Interior (MVR), Department of Dermatology, Venereology and Dermatologic Surgery, Sofia, Bulgaria; <sup>11</sup>Department of Dermatology and Allergology, Academic Teaching Hospital Dresden-Friedrichstadt, Dresden, Germany; <sup>12</sup>University B.I.S. Group of Institutions, Punjab Technical University, Punjab, India; <sup>13</sup>Centro Studi per la Ricerca Multidisciplinare e Rigenerativa, Università Degli Studi "G. Marconi", Rome, Italy; <sup>14</sup>Chair of Dermatology, University of Rome "G. Marconi" Rome, Italy

**Psoriasis is a chronic inflammatory disease affecting 1-3% of the general population. Due to the chronic nature of the disease, patients suffer from substantial psychosocial impact and impaired quality of life. Dr Michaels® (also branded as Soratinex®), an Australian series of topical herbal products, has been showing promising results for the treatment of patients with chronic plaque psoriasis and consequent improvement in their quality of life. This study aims to access the changes in quality of life of patients with Psoriasis using an Australian series of herbal skin-care products Dr Michaels® (Soratinex®) for psoriasis. The aim of this study is to observe and analyze the impact of Dr Michaels® product family on the quality of life of patients with psoriasis, 566 patients completed the Dermatology Quality of Life Index (DQLI) questionnaire in their initial consultation and at 3 follow up consultations, over a 6 months period. At the end of the data collection, all patients' answers were recorded and analyzed. The Psoriasis Area and Severity (PASI) Index were used to measure the severity and extent of psoriasis during the 3 consultations. The PASI for severe, moderate-severe, mild-moderate cases across time revealed a significant effect of the treatment within weeks, confirming the decreasing scores during the treatment. As well as PASI results, the final DLQI score showed a sensible reduction from mean =6.716 (at week 0) to 6.252 (at week 2), 4.015 (at week 6) and 2.407 (at week 10) signifying a 64.2% reduction of the initial score. This study demonstrates that Dr. Michaels® (Soratinex®) products, an Australian series of herbal-based skin products is effective for the treatment of psoriasis. This treatment also significantly improves patient's quality of life.**

Psoriasis is a chronic inflammatory disease affecting 1-3% of the general population (1). This disease is characterized by focal formation of inflamed, raised scaly plaques that occurs due the

excessive growth of skin epithelial cells (2). The cellular changes in the skin include hyperplasia of epidermal keratinocytes, vascular ectasia and hyperplasia and infiltration neutrophils, T

*Key words: Quality of Life, Psoriasis, Topical Products, Patient Satisfaction, suicidal tendencies, alcohol consumption, smoking*

Mailing address:

Professor Torello Lotti,  
Department of Dermatology,  
University of Rome "G. Marconi",  
Rome, Italy  
e-mail: professor@torelloitti.it

0393-974X (2016)

Copyright © by BIOLIFE, s.a.s.

This publication and/or article is for individual use only and may not be further reproduced without written permission from the copyright holder.

Unauthorized reproduction may result in financial and other penalties  
**DISCLOSURE: ALL AUTHORS REPORT NO CONFLICTS OF INTEREST RELEVANT TO THIS ARTICLE.**

lymphocytes, and other leucocytes in the skin. (2).

Psychosomatic stressful events play an important role in inducing or worsening psoriasis. Due to the chronic nature of the disease, patients suffer from substantial psychosocial impact and impaired quality of life (3, 4, 5, 6).

About 75% of patients have mild-to-moderate lesions, amenable to topical treatment (7, 8, 9). The most common available topical treatments include corticosteroids, vitamin D analogues (calcipotriol), retinoids, anthralin, tar compounds and combined treatments (7, 8). In the past years, new systemic medications were developed to treat moderate to severe cases, but there is a demand for new, safe and effective topical products (10, 11).

Dr Michaels® (also branded as Soratinex®), an Australian series of topical herbal products, has been showing promising results for the treatment of patients with chronic plaque psoriasis and consequently, improvement in their quality of life.

This study aims to access the changes in quality of life of patients with Psoriasis that were treated with Dr. Michaels® (Soratinex®) skin-care products for psoriasis.

## MATERIALS AND METHODS

The study included 566 patients with mild to severe stable chronic plaque psoriasis. All participants were treated with a series of herbal skin-care products Dr. Michaels® (Soratinex®) for psoriasis. Dr Michaels® (Soratinex®) product line offers three different preparations: a gel, an ointment and a conditioner (Table I).

These patients completed the Dermatology Quality of Life Index (DQLI) questionnaire in their initial consultation and at 3 follow up consultations, over a 6 months period. At the end of the data collection, all patients' answers were recorded and analyzed (12).

The Psoriasis Area and Severity Index were used to measure the severity and extent of psoriasis during the 4 consultations (13).

## RESULTS

### *Sociodemographic characteristics*

The study included the participation of 566 patients with chronic plaque psoriasis. The mean

**Table I.** Composition and application of Dr Michaels® (Soratinex®) Product Line.

Dr Michaels® (Soratinex®) Scalp and Body Cleansing Gel	Ingredients: Actives - salicylic acid, citric & glycolic acids Application: Applied before the use of the ointment. Scalp: Wet scalp and apply a small amount of cleansing gel. Massage thoroughly and leave for 2-3 minutes. Wash off with lukewarm water. (Can be applied to forehead but avoid cheek area). Body: Wet body. Apply small amount of cleansing gel to the psoriatic plaques. Leave for 2-3 minutes then rinse off with lukewarm water.
Dr Michaels® (Soratinex®) Scalp and Body Ointment	Ingredients: In a base of petrolatum Zinc oxide, Salicylic acid and essential oils such as Orange Oil, Rosemary Oil, Chamomile Oil Application: Applied to the psoriatic plaques of the scalp and body after using and washing off the cleansing gel. Only apply to severely infiltrated plaques on the scalp.
Dr Michaels® (Soratinex®) Skin Conditioner	Ingredients: Essential oils such as lavender oil, eucalyptus oil, natural vitamin E. Application: Applied to the psoriatic plaques two minutes after using the ointment (without washing it off).

age of participants was 32.5 years (8- to 84-years-of-age). Fifty-six per cent (318) were males and 44% (248) were females. Sixty-six 66% (374) were married, 25% (144) were single and 8% (48) were divorced. The location of the lesions was varied as well as the age of onset (Table II).

Seventy-six per cent (430) of patients reported a poor sleeping pattern presenting episodes of insomnia, and 24% (136) reported a good sleeping pattern of 6 to 8 hours of sleep daily. Twenty-four per cent (136) of patients had family history of psoriasis while 76% (430) did not have family history of psoriasis. Seventy-four per cent (419) were exercising regularly and 26% (147) were not. Regarding the alcohol consumption, the majority of patients 61% (343) reported weekly consumption while 39% (223) reported no consumption. The reasons for alcohol consumption reported by the

patients are listed in Fig. 1.

Twenty-two per cent (123) reported smoking, while 78% (443) did not. The reasons for smoking reported by the patients are listed in Fig. 2.

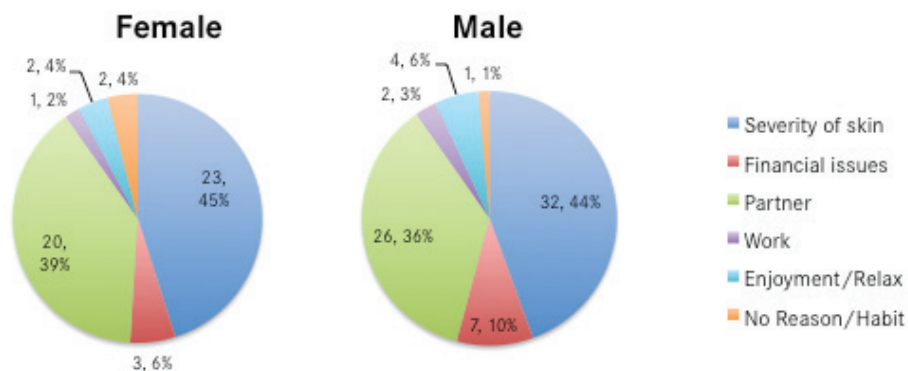
*Psoriasis area and severity index*

Patients with only nail psoriasis and psoriasis-arthritis were excluded from this evaluation.

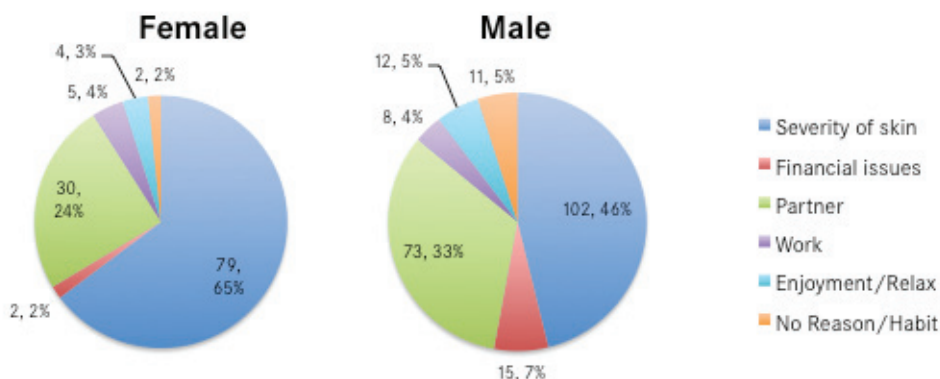
*Dermatology quality of life index*

The Dermatology Life Quality Index (DLQI) was conducted among the patients during the consultations and the mean and standard deviations of results for all 10 items can be seen in Table IV.

Equal variances within consultations were not assumed for this analysis, as Levene Test P-Value was less than 0.05. The unequal variances within groups (consultations) can be interpreted as response time for the treatment, which might differ among



**Fig. 1.** Reasons for Alcohol consumption within psoriasis patients that have a weekly alcohol consumption habit among case study. Note: total of 343 patients with a weekly alcohol consumption habit, of which 221 male and 122 female Source: Authors.



**Fig. 2.** Reasons for Smoking among psoriasis patients in case study. Note: total of 123 smokers, 72 male and 51 female. Source: Authors.

**Table II.** *Location of the Lesions and Age of onset*

<i>Variable</i>	<i>Percentage (n)</i>	
<b>Location of lesions</b>		
Arms+legs	33%	(186)
Scalp	28%	(156)
Body	20%	(112)
Nail+	12%	(70)
Palmoplantar	3%	(18)
Genitals	3%	(16)
Face	1%	(8)
<b>Age of onset</b>		
<10	5%	(28)
10 - 19	52%	(294)
19 - 29	27%	(151)
30 - 39	9%	(52)
40 - 49	2%	(13)
>50	5%	(27)

**Table III:** *Descriptive Data for PASI during initial consultation and at 3 follow up consultations over a 6 months period by Psoriasis Patients using Dr Michaels® product family.*

	<i>Week 0</i>		<i>Week 2</i>		<i>Week 6</i>		<i>Week 10</i>	
	<i>Count</i>	<i>(Mean)</i>	<i>Count</i>	<i>(Mean)</i>	<i>Count</i>	<i>(Mean)</i>	<i>Count</i>	<i>(Mean)</i>
Severe (>20)	37	(32.5)	35	(30.2)	5	(21.2)	0	
Moderate-Severe (10-20)	147	(16.8)	128	(14.2)	86	(11.3)	31	(12.2)
Mild-Moderate (<10)	355	(8.6)	311	(7.8)	272	(1.6)	90	(1.4)
None	0	-	65	-	176	-	418	-
PASI Group ( <i>total</i> )	539	(12.47)	539	(9.83)	539	(2.81)	539	(0.78)

*PASI evolution on Psoriasis Patients during treatment with Dr Michaels® product family*

**Table IV.** Descriptive Data for DLQI Items during treatment with Dr Michaels® product family.

DLQI Item Number	Week 0		Week 2		Week 6		Week 10		F-VALUE	P-VALUE
	Mean (SD)		Mean (SD)		Mean (SD)		Mean (SD)			
1*	2.000	(0.8)	1.652	(1.0)	1.161	(1.0)	0.424	(0.8)	372.600	0.000
2	1.397	(0.7)	1.238	(0.8)	0.757	(0.7)	0.265	(0.5)	371.450	0.000
3	1.076	(1.1)	0.870	(1.1)	0.419	(0.7)	0.230	(0.7)	99.600	0.000
4	0.544	(0.8)	0.516	(0.8)	0.174	(0.5)	0.150	(0.5)	56.490	0.000
5	0.449	(0.8)	0.458	(0.8)	0.354	(0.7)	0.230	(0.6)	12.900	0.000
6	1.093	(1.2)	1.091	(1.3)	0.939	(1.1)	0.651	(1.0)	20.680	0.000
7	0.477	(0.7)	0.471	(0.7)	0.351	(0.6)	0.271	(0.5)	14.850	0.000
8	0.701	(0.8)	0.646	(0.8)	0.468	(0.5)	0.180	(0.4)	92.480	0.000
9	0.521	(0.8)	0.529	(0.8)	0.427	(0.6)	0.354	(0.5)	9.980	0.000
10	0.458	(0.6)	0.434	(0.6)	0.126	(0.3)	0.074	(0.3)	97.27	0.000
Total	6.716		6.252		4.015		2.407			

\*: Study size of 566 for item 1, while all other items were calculated for 539 patients as 27 Nail only and PsA only patients were excluded from the study.

patients.

Unequal variances *t*-test (Welch's ANOVA) was conducted in order to test the hypothesis of significant+ difference in results across time (between groups). The significance level was set at  $\alpha=0.05$  and the F-Value and p-value found for each item of the DLQI can be seen in the descriptive in Table IV. As all the items have shown p-value less than 0.05, the treatment has shown significant effect for all items.

As well as PASI results, the final DLQI score has shown a sensitive reduction from mean =6.716 (week 0) to 6.252 (week 2), 4.015 (week 6) and 2.407 (week 10); a 64.2% reduction of the initial score.

The evolution of the improvement for each item of DLQI is shown in Table V, obtained after repeated Games-Howell tests (significance level of  $\alpha=0.05$ ). For every week, the item results showed significant difference; there is a "plus sign" added to the line.

From this test, the following conclusions can be drawn: Items 1, 2 and 3 have shown significant effect already on week 2 and the three items kept on showing significant differences on week 6 as well as week 10, which can be noted through the reduction of the mean; Item 4 and 7 showed a difference only

on week 6 and no difference on week 10, indicating that the treatment showed improvement after the second follow up and stabilized the results; Item 5, 6 and 9 have shown significant difference only on week 10; Items 8 and 10 showed improvement only on week 6, but also showed continuous improvement on week 10.

#### Suicidal ideations

During treatment, on each consultation patients were asked if they ever had suicidal tendencies, data summary can be seen in Table VI.

Conducting a *Chi*-Square test comparing the number of responses across time, it failed to reveal significant effect of the treatment on suicidal tendencies and therefore, with a significance level of  $\alpha=0.05$ , the treatment did not affect increase or decrease of cases of suicidal tendencies ( $\chi^2_{2,222} = 4.208$ , p-value=0.91<sup>+</sup> p-value>0.05/significance level  $\alpha = 0.05$ ).

At the start of the study, twelve (12) patients had suicidal ideations. They all came from the divorced group. They all blamed the severity and/or location of their psoriasis plus the financial cost of treatment,

**Table VI.** *Suicidal Tendencies evolution during Dr Michaels® treatment.*

	Week 0	Week 2	Week 6	Week 10
Very much	0	0	0	1
A lot	5	3	4	5
A little	7	5	7	5
Not at all	527	532	528	528

as the cause of their marital break-up. They explained that the burden of having psoriasis and the loss of their partner had had major psychological impact, resulting in depression and suicidal ideations. These suicidal ideations continued even as the psoriasis resolved.

### DISCUSSION

Psoriasis has a strong negative impact on quality of life of affected patients. One of the major goals of treatment therefore is the improvement of quality of life (3, 4). In this study, we used the DLQI, a validated instrument with a good sensitivity to change (12, 14).

The treatment with the Dr Michaels® product family has consistently showed improvement of both PASI and DLQI. The conclusion that can be draw is that the treatment has significantly improved quality of life for psoriasis patients. All items in the DLQI refer to quality of life such as pain, embarrassment, self-consciousness and impact on daily, social, leisure and professional activities and the treatment has given good results for all of them. Our study could also provide some evidence of a dose-response relationship for an association between drinking and smoking habits and psoriasis.

As seen in the case study, the severity of skin has consistently been the main reason for smoking and drinking for psoriasis patients. It is natural that if the patient has an improvement of his or her disease, the skin gradually will not be the factor for drinking and smoking. It was not the scope of this study and therefore not proved that the treatment of Dr Michaels® product family could reduce the smoking or drinking, but as the results clearly show a better life quality and significant skin improvement, this could imply a change of behavior of the patient

regarding these two habits.

Further studies in the evolution of smoking and drinking habits related to the treatment of psoriasis could be carried out in the future.

### CONCLUSION

This study demonstrates that Dr. Michaels® (Soratinex®) products, an Australian series of herbal-based skin products, is effective for the treatment of psoriasis and significantly improves the quality of life for patients.

### ACKNOWLEDGEMENTS

The authors gratefully acknowledge Paulo Henrique Schmitz Agostini for assistance with statistical analysis, Tirsell Pty Ltd (Melbourne, Australia) and Frankl Pharma Global Ltd (Surrey, UK) for providing the products for the studies.

### REFERENCES:

1. Weger W. Current status and new developments in the treatment of psoriasis and psoriatic arthritis with biological agents. *Br J Pharmacol* 2010;160(4):810-20.
2. Krueger J, Bowcock A. Psoriasis pathophysiology: current concepts of pathogenesis. *Ann Rheum Dis* 2005; 64(S2):ii30-6.
3. Dubertret L, Mrowietz U, Ranki A, van de Kerkhof PC, Chimenti S, Lotti T, Schäfer G; EUROPSO Patient Survey Group. European patient perspectives on the impact of psoriasis: the EUROPSO patient membership survey. *Br J Dermatol* 2006; 155(4):729-36.
4. Campolmi E, Zanieri F, Santosuosso U, D'Erme AM, Betti S, Lotti T, Cossidente A. The importance of stressful family events in psoriatic patients: a



- retrospective study. *J Eur Acad Dermatol Venereol* 2012; 26(10):1236-9.
5. França K, Chacon A, Ledon J, Savas J, Nouri K. Psychodermatology: a trip through history. *Anais Brasileiros de Dermatologia* 2013; 88(5):842-3.
  6. Jafferany M, Franca K. Psychodermatology: Basics Concepts. *Acta Derm Venereol* 2016; [Epub ahead of print].
  7. Samarasekera EJ, Sawyer L, Wonderling D, Tucker R, Smith CH. Topical therapies for the treatment of plaque psoriasis: systematic review and network meta-analyses. *Br J Dermatol* 2013; 168(5):954-67.
  8. Afifi T, de Gannes G, Huang C, Zhou Y. Topical therapies for psoriasis: Evidence-based review. *Canadian Family Physician* 2005; 51(4):519-25.
  9. Sawyer L, Samarasekera EJ, Wonderling D, Smith CH. Topical therapies for the treatment of localized plaque psoriasis in primary care: a cost-effectiveness analysis. *Br J Dermatol* 2013; 168(5):1095-105.
  10. Loffredo S, Ayala F, Marone G, Delfino G, Stranges S, Marone G. Immunopathogenesis of psoriasis and pharmacological perspectives. *Rheumatol Suppl* 2009; 83:9-11.
  11. AlShobaili HA, Shahzad M, Al-Marshood A, Khalil A, Settin A, Barrimah I. Genetic Background of Psoriasis. *Int J Health Sci (Qassim)* 2010; 4(1):23-29.
  12. Finlay AY, Khan GK. Dermatology Life Quality Index (DLQI): a simple practical measure for routine clinical use. *Clin Exp Dermatol* 1994; 19:210-6.
  13. Langley RG, Ellis CN. Evaluating psoriasis with Psoriasis Area and Severity Index, Psoriasis Global Assessment, and Lattice System Physician's Global Assessment. *J Am Acad Dermatol* 2004; 51:563-9
  14. Bronsard V, Paul C, Prey S, et al. What are the best outcome measures for assessing quality of life in plaque type psoriasis? A systematic review of the literature. *J Eur Acad Dermatol Venereol* 2010; 24(S2):17-22.



## RAPID COMMUNICATION: A VEGETABLE OIL EXTRACT RESTORES REDOX STATUS IN FIBROBLASTS FROM PSORIATIC PATIENTS

V. BARYGINA<sup>1</sup>, M. BECATTI<sup>1</sup>, A. MANNUCCI<sup>1</sup>, N. TADDEI<sup>1</sup>, M. TIRANT<sup>2</sup>,  
J. HERCOGOVA<sup>3,4</sup>, K. FRANÇA<sup>5</sup>, M. FIORANELLI<sup>6</sup>, M.G. ROCCIA<sup>7</sup>, G. TCHERNEV<sup>8</sup>,  
U. WOLLINA<sup>9</sup>, T. LOTTI<sup>10</sup> and C. FIORILLO<sup>1</sup>

<sup>1</sup>Department of Experimental and Clinical Biomedical Sciences, University of Florence, Florence Italy; <sup>2</sup>Psoriasis & Skin Clinic, Melbourne, Australia; <sup>3</sup>2nd Medical Faculty, Charles University, Bulovka Hospital, <sup>4</sup>Institute of Clinical and Experimental Medicine, Prague Czech Republic; <sup>5</sup>Department of Dermatology & Cutaneous Surgery, Department of Psychiatry & Behavioral Sciences, Institute for Bioethics & Health Policy, University of Miami, Miller School of Medicine, Miami, FL, USA; <sup>6</sup>Department of Nuclear Physics, Sub-nuclear and Radiation, G. Marconi University, Rome, Italy; <sup>7</sup>University B.I.S. Group of Institutions, Punjab Technical University, Punjab, India; <sup>8</sup>Medical Institute of Ministry of Interior (MVR), Department of Dermatology, Venereology and Dermatologic Surgery, Sofia, Bulgaria; <sup>9</sup>Department of Dermatology and Allergology, Academic Teaching Hospital Dresden-Friedrichstadt, Dresden, Germany; <sup>10</sup>Chair of Dermatology, University of Rome "G. Marconi" Rome, Italy

Barygina and Becatti contributed equally to this work.

**Psoriasis is an inflammatory skin disease that affects 2-5% of the worldwide population. It is a chronic immune-mediated hyperproliferative inflammatory skin disease of unknown etiology, characterized by the appearance of sore patches of thick, red skin with silvery scales.**

Recent research suggests that oxidative stress is involved in the pathogenesis of psoriasis. Indeed, a number of studies revealed increased markers of oxidative stress and decreased antioxidant capacity in plasma, in white blood cells (1, 2) and in skin (3-5).

The comprehension of the role of immune function in psoriasis could permit the management of this complex disease, which dramatically affects patients far beyond the skin. In fact, cytokines and growth factors released by activated T cells have been shown to display a prominent role in keratinocyte hyperproliferation; however, in this study, we focused our attention on dermal fibroblasts, which are also directly involved in the developing psoriatic lesions accelerating keratinocyte proliferation (6).

Supplementation with antioxidants was shown to be helpful in treatment of patients with psoriasis (7, 8). Essential and vegetable oils represent an important source of natural antioxidants. The present study aimed to estimate the *in vitro* effect of a mixture of vegetable and essential oils (calendula, patchouli, geranium, neroli, myrrh) - Dr Michaels (Soratinex) family products, on redox status of fibroblast primary culture from lesional psoriatic skin.

### MATERIALS AND METHODS

The study was approved by the Local Ethical Committee and carried out according to the Helsinki Declaration. Analyses were performed in 3 patients

*Key words: psoriasis, natural treatment, natural oils, redox system, cell viability*

#### Mailing address:

Dr. Victoria Barygina, PhD,  
Department of Experimental and Clinical Biomedical Sciences,  
University of Florence,  
Florence Italy  
e-mail: v.barygina@gmail.com

(2 females and 1 male) affected by moderate psoriasis (PASI=13) with a mean age of  $45.5 \pm 8.5$  years, and with a mean duration of disease of 14 years. No subject involved in the study followed any systemic therapy before the study or had a history of any disease which might alter redox status.

Water-soluble extract of oil mixture (OME) was prepared as previously reported (9). Total antioxidant capacity of OME was estimated by the ORAC assay as previously reported using Trolox (the water-soluble vitamin E analogue) as the standard antioxidant (10).

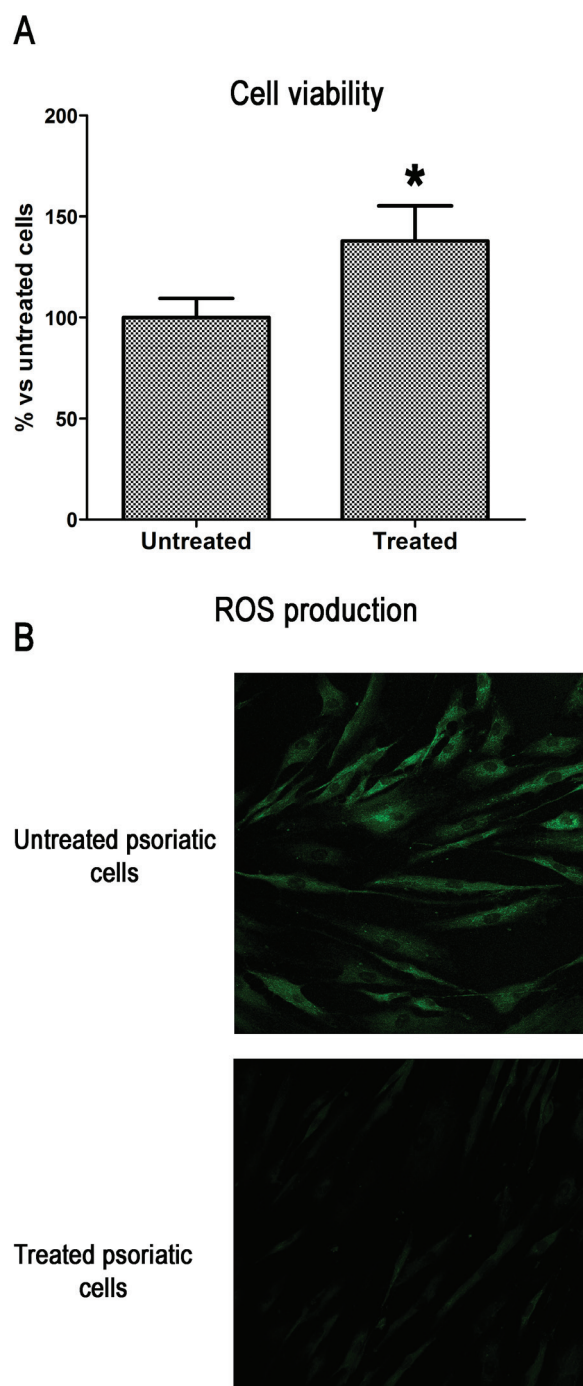
Cell viability was measured using a fluorometric resazurin reduction method following the manufacturer protocol (Cell Titer-Blue, Promega Corp). Briefly, fibroblasts were plated in black 96-multiwell plate ( $6 \times 10^3$  cells/well). OME at the opportune dilution was then added and incubated 24 h at  $37^\circ\text{C}$  and cells were then washed with PBS and  $100\mu\text{l}$  of resazurin diluted in RPMI was added. The microplate was further incubated for 2 h at  $37^\circ\text{C}$  and fluorescence was measured using a fluorometric microplate reader (Fluoroskan Ascent; Thermo Electron Corp., Vantaa, Finland).

Treatment for 24 h of 1:5000 dilution OME revealed to be the most effective concentration in restoring cell viability and it was therefore used for confocal microscopy experiments aimed at measuring, in untreated and treated psoriatic fibroblasts, intracellular ROS production using the  $\text{H}_2\text{DCFDA}$  marker (9).

## RESULTS

According to our data, the total antioxidant capacity of OME (at the 1:5000 dilution) resulted equivalent to  $163.6\text{mM}$  Trolox, which indicates a very high antioxidant capacity for the provided oil mixture. As a preliminary experiment aimed at evaluating the effect of OME on cell viability, a dose-dependent test was carried out in psoriatic fibroblasts in the presence of increasing OME concentrations ranging from 1:1000 to 1:10000.

Our data indicate that treatment with 1:5000 OME increased the viability of psoriatic fibroblasts by  $37.9 \pm 1.7\%$  compared to untreated cells as shown by resazurin assay (Fig. 1a). A significant decrease in intracellular ROS production was observed in OME-treated fibroblasts compared to untreated



**Fig. 1. a):** Cell viability assay in untreated and OME treated psoriatic fibroblasts. The reported values (means $\pm$ SD) are representative of three independent experiments, each performed in triplicate. \*Significant difference ( $P \leq 0.01$ ) versus untreated psoriatic fibroblasts; **b):** Confocal microscopy analysis of untreated and OME treated psoriatic fibroblasts of reactive oxygen species production (63x magnification) using the  $\text{H}_2\text{DCFDA}$  fluorescent probe.

fibroblasts as revealed by confocal analysis (Fig. 1b). Furthermore, OME dilutions (1:10000 and 1:20000) did not display any significant viability-improving or redox balancing effect (data not shown).

### CONCLUSIONS

Taken together, our data indicate a strong protective, redox balancing effects of OME obtained from the vegetable oil mixture (Dr Michaels (Soratinex) family products) and if used at appropriate concentration, significantly increases the viability and decreases intracellular ROS production in human psoriatic fibroblasts. A strong antioxidant effect of the OME obtained from Dr Michaels mixture of oils can be the reason for the effectiveness of the mixture in a topical treatment of psoriasis. Further studies are in progress to understand the mechanisms underlying the protective effects of the used compounds in psoriasis but also in other dermatological diseases such as, eczema, acne, atopic dermatitis and more.

### REFERENCES

1. Zhou Q, Mrowietz U, Rostami-Yazdi M. Oxidative stress in the pathogenesis of psoriasis. *Free Radic Biol Med* 2009; 47:891-905.
2. Barygina VV, Becatti M, Soldi G, et al. Altered redox status in the blood of psoriatic patients: involvement of NADPH oxidase and role of anti-TNF- $\alpha$  therapy. *Redox Rep* 2013; 18:100-6.
3. Dimon-Gadal S, Gerbaud P, Thérond P, Guibourdenche J, Anderson WB, Evain-Brion D, Raynaud F. Increased oxidative damage to fibroblasts in skin with and without lesions in psoriasis. *J Invest Dermatol* 2000; 114:984-9.
4. Tekin NS, Tekin IO, Barut F, Sipahi EY. Accumulation of oxidized lowdensity lipoprotein in psoriatic skin and changes of plasma lipid levels in psoriatic patients. *Mediators Inflammation* 2007; 2007:78454.
5. Becatti M, Barygina V, Emmi G, Silvestri E, Taddei N, Lotti T, Fiorillo C. SIRT1 activity is decreased in lesional psoriatic skin. *Intern Emerg Med* 2016; in press.
6. Boehncke WH, Schön MP. Psoriasis *Lancet* 2015; 386:983-94.
7. Kharaeva Z, Gostova E, De Luca C, Raskovic D, Korkina L. Clinical and biochemical effects of coenzyme Q10, Vitamin E, and Selenium supplementation to psoriasis patients. *Nutrition* 2009; 25:295-302.
8. Søyland E, Funk J, Rajka G, et al. Effect of dietary supplementation with very-long-chain n-3 fatty acids in patients with psoriasis. *N Engl J Med* 1993; 328:1812-6.
9. V. Barygina, The redox system: selected concepts in general medicine and in dermatology, in *Natural Antioxidants in General Medicine and in Dermatology*. T. Lotti, D. Turini, J. Hercogova, ed. World Health Academy, New York.
10. Dell'Agli M, Fagnani R, Galli GV, et al. Olive oil phenols modulate the expression of metalloproteinase 9 in THP-1 cells by acting on nuclear factor-kappaB signaling. *J Agric Food Chem* 2010; 58:2246-52.